

## Rare manifestation of acute aortic dissection (Type B)

Jiří Šťastný<sup>a</sup>, Petr Šantavý<sup>b</sup>, Vojtěch Prášil<sup>c</sup>, Martin Gřiva<sup>a</sup>,  
Zdeněk Coufal<sup>a</sup>, Vladimír Lonský<sup>b</sup>

<sup>a</sup> Department of Cardiology, Tomas Bata Regional Hospital, Zlín, Czech Republic

<sup>b</sup> Department of Cardiac Surgery, Palacky University Teaching Hospital, Olomouc, Czech Republic

<sup>c</sup> Department of Radiology, Palacky University Teaching Hospital, Olomouc, Czech Republic

---

### ABSTRACT

---

#### Keywords:

Aortic dissection

Aortitis

Cardiovascular syphilis

Compressed left atrium

Right-sided hemothorax

A right-sided hemothorax is a rare manifestation of an acute type B aortic dissection that has been covered in the available references in only a few cases. This case report covers the case of a 58-year-old man hospitalized for acute pain in the epigastrium with severe hypotension and sopor. An acute type B dissection manifested by an isolated right-sided hemothorax with concurrent oppression of the left atrium of the heart and pulmonary veins by a mediastinal hematoma was diagnosed. Cardiovascular syphilis was diagnosed as the probable causal agent of the dissection. The acute situation was resolved by the implantation of a stent graft and evacuation of hematoma from the right-sided thoracotomy.

© 2018, ČKS.

---

### Introduction

Acute aortic dissection is a life-threatening condition. Early and precise diagnostics is essential for mortality prevention, which however still remains high. Acute aortic dissection is manifested by the sudden onset of severe pain and not infrequently by hemodynamic instability. Localization of the pain and other symptoms differs depending on the extent and place where the aorta and adjacent structures are damaged. A right-sided hemothorax with the concurrent oppression of the left atrium of the heart and pulmonary veins by a mediastinal hematoma ranks among the rare manifestations of acute type B aortic dissection of luetic etiology. The acute condition was successfully managed by the implantation of a stent graft and evacuation of hematoma from the right-sided thoracotomy.

---

### Case report

A 58-year-old white male with chronic alcohol abuse in anamnesis, was hospitalized in the Emergency Department on the grounds of a qualitative disturbance of consciousness with severe hypotension and agonizing pain in the epigastrium. When providing information for the case history, the patient mentioned that he had suffered from slight pain in the chest during previous months. At the time of admission, he was soporous, with a systolic pressure of 40 mmHg. An ECG examination revealed sinus tachycardia with a frequency of up to 180/min.

Clinical signs of dehydration were present. Stabilization of blood circulation, spontaneous ventilation and full consciousness were attained by the intravenous administration of 2500 ml of crystalloids, with temporary support of blood circulation by noradrenalin. The pain in the epigastrium and bottom part of the left hemothorax persisted. Laboratory tests revealed the presence of normochromic, normocytic anemia with hemoglobin amounting to 93 g/L; the other laboratory findings were normal. An echocardiographic examination revealed a significant extrapericardial oppression of the left atrium of the heart, moderate aortic regurgitation with a slight dilatation of the ascending aorta, and a right-sided fluidothorax. The other structures were without pathological findings.

On the grounds of suspected acute aortic dissection, urgent CT angiography was performed and showed an intramural hematoma of the descending aorta 85 × 37 × 60 mm in size with communication into the right pleural cavity where the hemothorax was located (Fig. 1). Compression of the left atrium of heart and pulmonary veins by a mediastinal hematoma was confirmed (Fig. 2). Another chronic intramural hematoma was discovered dorsally on the transition of the arch and the descending aorta. The patient complained of persisting pain. He had no signs of heart/respiratory failure. The condition was resolved by the exclusion of affected part of thoracic aorta by three tubular stent grafts with proximal stent graft overlapping left subclavian artery. Presented type II. endoleak was resolved by embolization of proximal part of the left subclavian artery by coils (Fig. 3). The he-

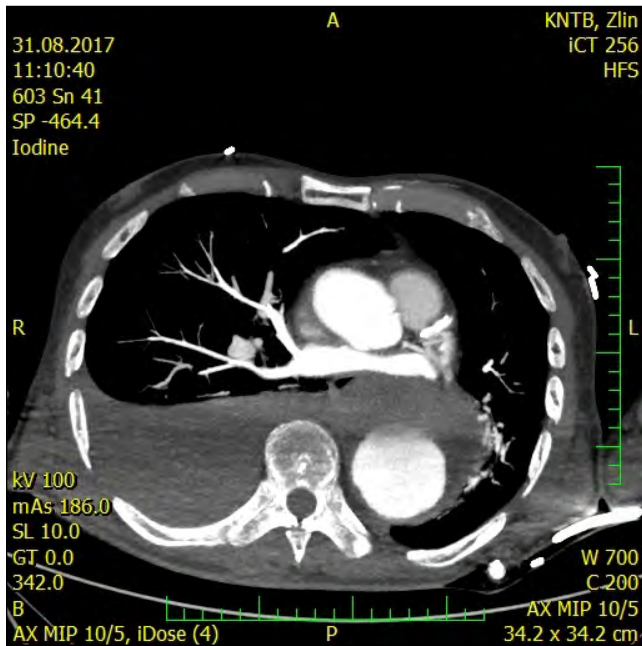


Fig. 1 – Rupture of descending aorta with a right-sided hemothorax.

matomas from the right pleural cavity were surgically evacuated through a right-sided thoracotomy six days later. During the subsequent course of action the patient complained of a slight dysphagia. An examination of the swallowing act showed a left-sided ventrolateral deviation of the esophagus due to oppression by an intramural hematoma of the descending aorta without obstruction. A conservative approach was applied. As part of the additional examination of the etiology, tertiary stage of syphilis was confirmed based on a positive serological test in both blood and cerebrospinal fluid. The treatment was based on antibiotics. The patient was discharged for outpatient treatment and remained registered at the dispensary.

## Comments

Based on the Stanford classification, aortic dissections are divided into type A, comprising affections of the ascending aorta (twice as common), and type B, affecting the more distal parts of the aorta outside the ascending segment. Both types differ in terms of prognosis and therapeutic approach. While type A requires urgent surgery, type B allows less acute consideration, with the application of percutaneous endovascular procedure if intervention is necessary. In approximately 10% of type-B cases a left-sided hemothorax develops. However, owing to the anatomic situation, a right-sided hemothorax only develops very rarely (only a few case reports are available).<sup>1,2</sup> Also, compression of the left atrium of heart and pulmonary veins by a mediastinal hematoma – although reported – is very rare. The left atrium of heart is a thin-walled structure with low intraluminal pressure which can therefore be easily oppressed by pathological mediastinal processes.<sup>3</sup> If significant compression with a decrease in the

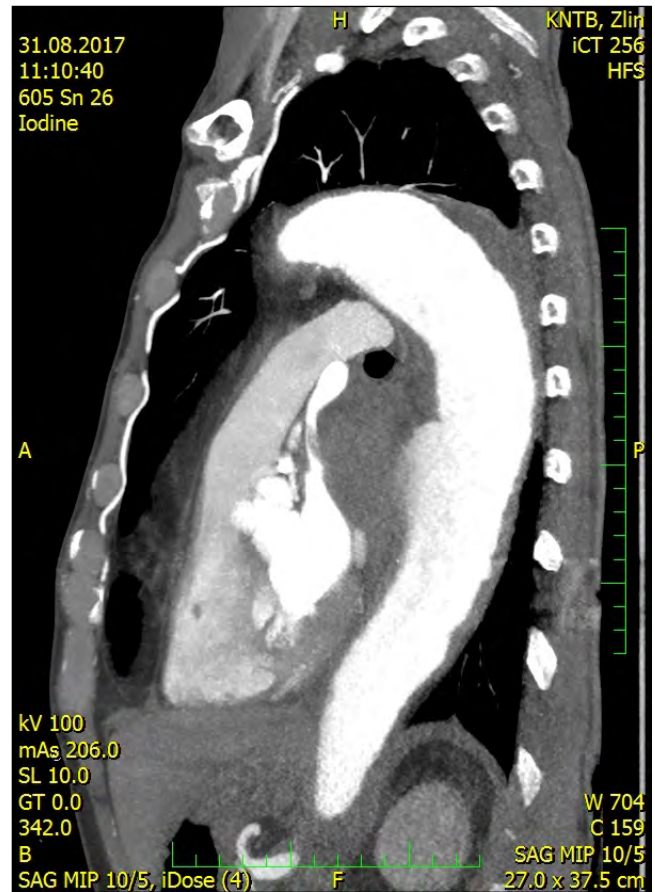


Fig. 2 – Left atrium and pulmonary veins compressed by a mediastinal hematoma.

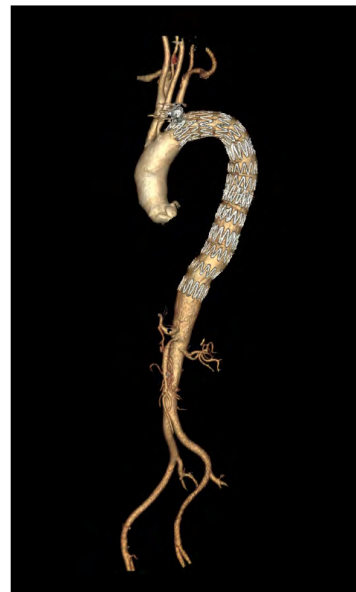

Fig. 3 – Exclusion of affected part of thoracic aorta by three tubular stent grafts.

volume of the left atrium of heart appears, the clinical manifestation is similar to cardiac tamponade. In this case, the patient could be hemodynamically stabilized by the fast refilling of the intravascular volume with pre-existing dehydration, which resulted in the improvement of the refilling of heart compartments with a relative re-

duction in the oppression of the left atrium of heart and pulmonary veins.

In current clinical practice, the diagnosis of cardiovascular syphilis is relatively rare. However, at the time when antibiotics were not commonly available, tertiary syphilis was the most common cause of aneurysms in the thoracic aorta and it is estimated that it was responsible for 5–10% of all deaths for cardiovascular reasons.<sup>4</sup> Cardiovascular syphilis is one of the late symptoms of the infection caused by *Treponema pallidum* and manifests itself most commonly 20 to 30 years after primary infection. The basis of the syphilitic affection of the aorta is the obliterative endarteritis of the vasa vasorum most commonly in the area of the adventitia and media of the ascending aorta and in the area of the aortic arch. Destruction of the connective tissue in the wall of the blood vessel appears with resulting scarification, calcification, the formation of aneurysms and intramural hematomas. The most common manifestation is the aneurismatic dilatation of the ascending aorta with aortic regurgitation. However, a rupture is rare.<sup>5</sup>

#### Financial support and conflict of interest disclosure

None of the authors has a conflict of interest and financial support to disclose.

#### Ethical statement

The research was conducted in accordance with The Code of Ethics of the World Medical Association (Declaration of Helsinki).

#### Reference to the online article

<http://www.cksonline.cz/coretvasa-case-reports/clanky.php?p=detail&id=68&pid=976>

#### References

1. Abu-Fadel MS, Gibbson MF, Michel LB, et al. Right sided hemothorax: an uncommon manifestation of type b aortic dissection (descending aortic dissection). *Chest* 2004;126:958S.
2. Ozkan F, Akpınar E, Serter T, et al. Ruptured type B aortic dissection presenting with right hemothorax. *Diagn Interv Radiol* 2008;14:6–8.
3. D’Cruz IA, Feghali N, Gross CM. Echocardiographic manifestations of mediastinal masses compressing or encroaching on the heart. *Echocardiography* 1994;11:523–533.
4. Cruz RP, Marrone LC, Marrone AC. Chronic syphilitic aortic aneurysm complicated with chronic aortic dissection. *Am J Surg* 2010;200:e64–e66.
5. Longo DL. *Harrison’s Principles of Internal Medicine*. 18th ed. New York: McGraw-Hill, 2012:2060–2066.



## CURRICULUM VITAE

**EDUCATION:** 09/2006–05/2012 – General medicine, Medical School of Masaryk University (MU) in Brno, Czech Republic.

**PROFESSIONAL EXPERIENCE:** 08/2012 – today – Physician, Cardiology Department, Tomas Bata Regional Hospital in Zlin, Czech Republic; 7/2011–9/2011 – Research Trainee, Division of Cardiovascular Diseases, Mayo Clinic, Rochester, Minnesota, USA; 1/2011–12/2011 – Research Administrator, International Clinical Research Center in Brno (ICRC), Czech Republic; 10/2009–5/2012 – Research Trainee, Department of Pathophysiology, Masaryk University, Brno, Czech Republic.

**RESEARCH EXPERIENCE:** 7/2011–9/2011 – Sleep Disordered Breathing and Cardiac Function and Morphology and Sleep Disordered Breathing and Arrhythmias under supervision of Tomas Konecny, MD. Mayo Clinic, Rochester, MN, USA; 10/2009–6/2012 – Department of Pathophysiology, Masaryk University, Brno, clinical-genetic examination of obese patients in project DANONE2007; 9/2010–6/2012 – Department of Pathophysiology, MU Brno, research of the newly identified adipocytokines and their role in human metabolic pathways under supervision of MUDr. Julie Bienertová-Vašková, Ph.D. (Visfatin gene analysis in patients with strongly developed obesity phenotype); 1/2011–1/2012 – International Clinical Research Center in Brno, a member of research team studying sleep apnea in patients after acute myocardial infarction; 9/2009–6/2010 – Department of Pathophysiology, Masaryk University, Brno, research of VNTR polymorphism of Per3 gene in association with anthropometric markers and eating habits in cohort consists of 330 patients.

**PUBLICATIONS AS A FIRST AUTHOR:** Stastny J, Bienertova-Vasku J, Tomandl J, et al. Association of genetic variability in selected regions in visfatin (NAMPT) gene with anthropometric parameters and dietary composition in obese and non-obese Central-European population. *Diabetes Metab Syndr* 2013;7:166–171; Stastny J, Bienertova-Vasku J, Vasku A. Visfatin and its role in obesity development. *Diabetes Metab Syndr* 2012;6:120–124.