



SAIK

Slovenská asociácia
intervenčnej kardiológie

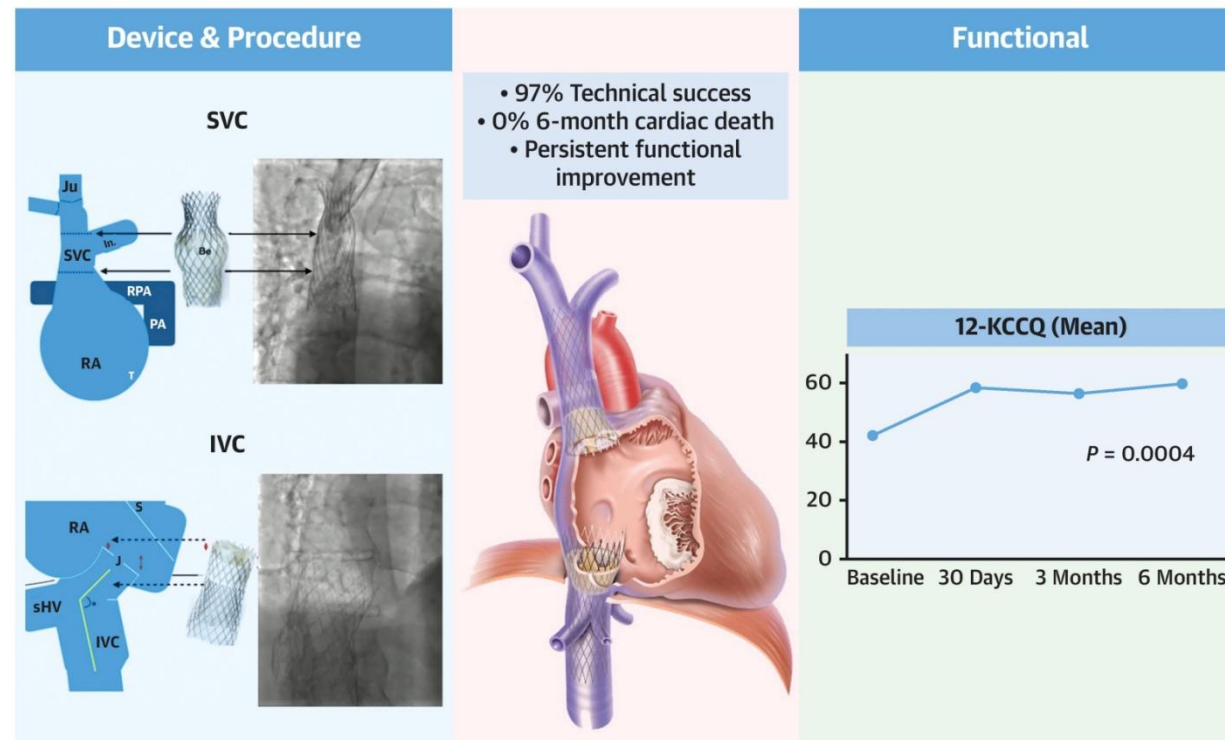
„Už je koniec, tak to kl'udne vytiahni,“

Anton Farkaš

Kardiocentrum AGEL

TricValve v manažmente TR

CENTRAL ILLUSTRATION: 6-Month Outcomes of the TricValve System for Severe TR: TRICUS EURO Study (N = 35)

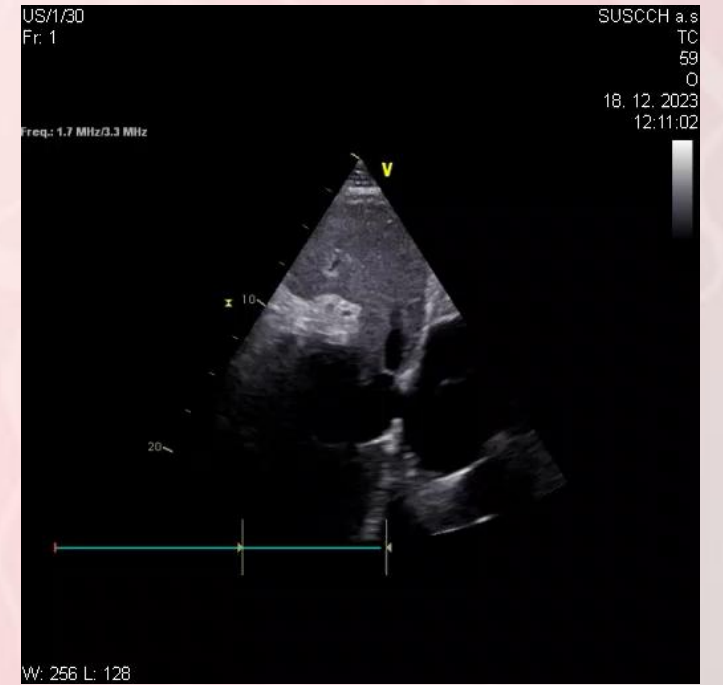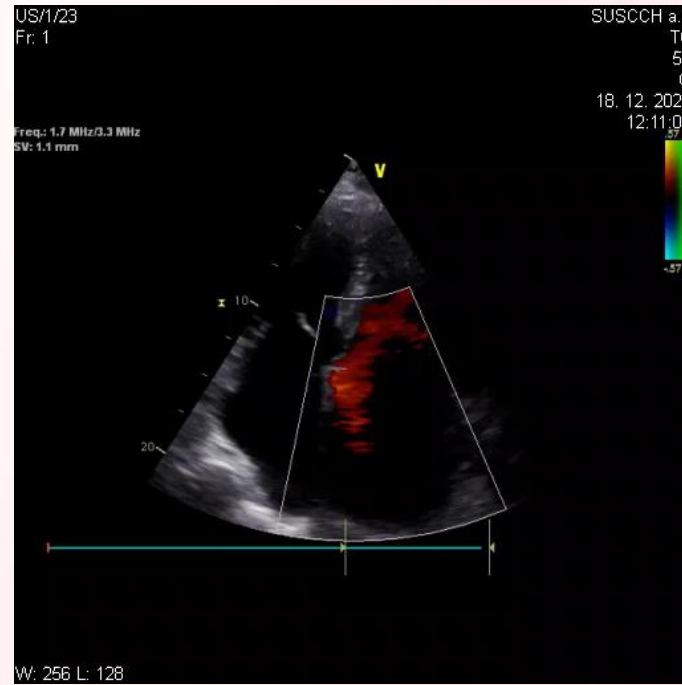

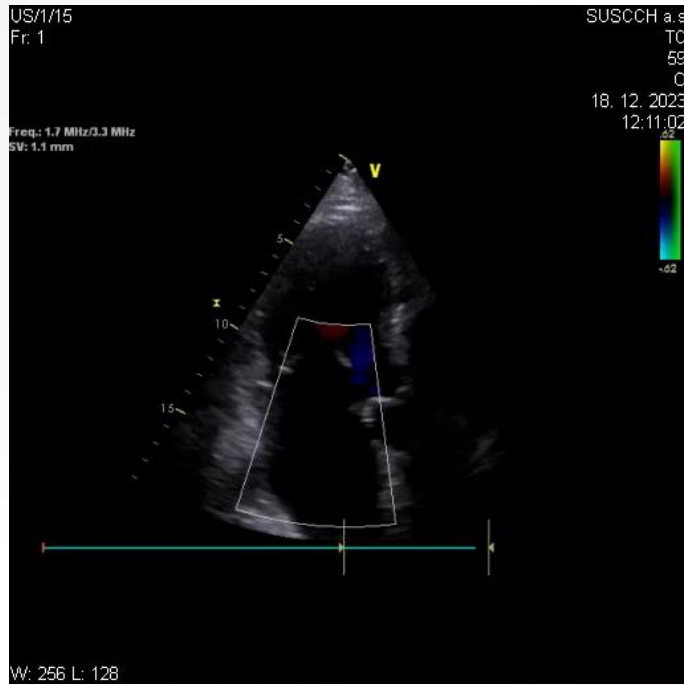
Estévez-Loureiro R, et al. J Am Coll Cardiol Interv. 2022;15(13):1366-1377.

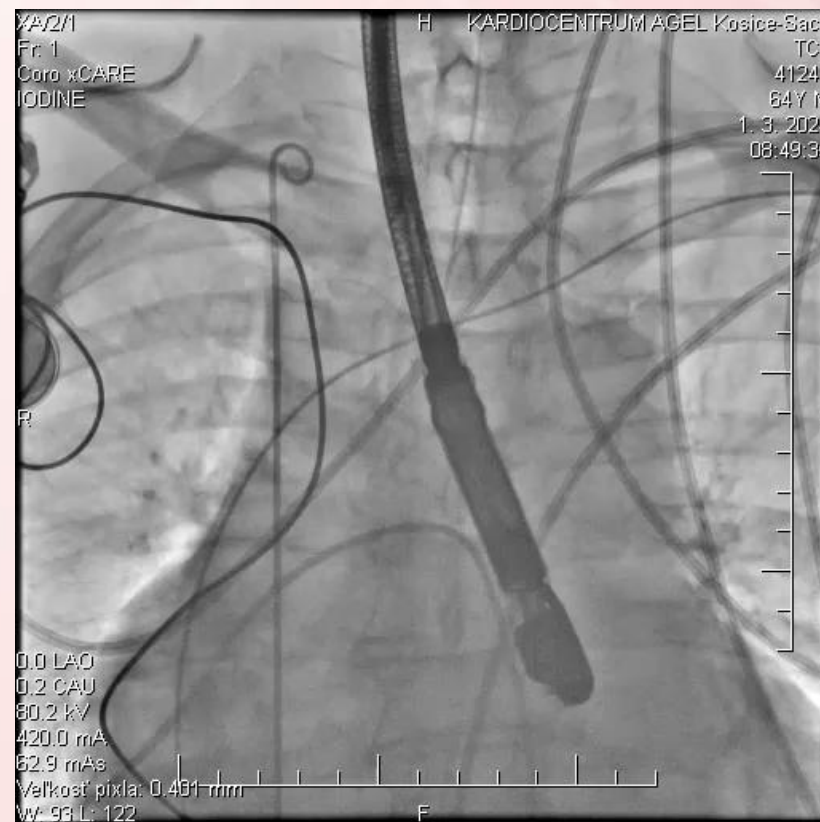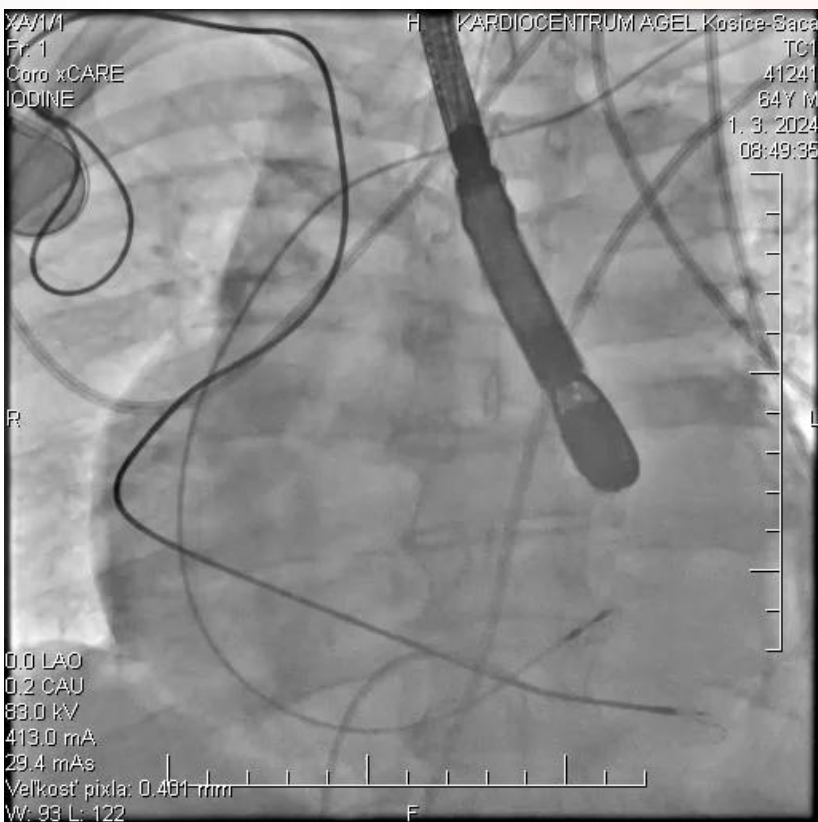
J.D. 64 ročný

- Permanentá AFib , CHADS VASC 3, HAS BLED 2
- - primoimplantacia TKS- Medtronic Astra XT SR MRI z ľavej strany - LBBAP (I.sin)
- - stav po reimplantácii TKS pre EOL SJM Endurity MRI, PM 1172, VVIR /2018/ (I.dx)
- - stav po reimplantácii TKS pre EOL (2010 - Altrua SR, Guidant) (I.dx)
- - stav po impantácii KS VVIR pre permanentú AFib s rýchlym prevodom na komory /1998/ (I.dx)
- - stav po RFCA AV uzla pre tachyfibriláciu predsiení /1998/
- CHSZ, HFmrEF s LVEF 45%, dominantne pravostranné srdcové zlyhávanie, NYHA II
- Trikuspidálna regurgitácia hemodynamicky významná, sekundárna
- Artériová hypertenzia 2 . st. ESC/ESH s VVKVR
- Diabetes mellitus 2 typu na diéte
- Dyslipidémia na diéte
- Hyperurikémia
- Stav po bilat. COVID asoc. BRPN (01/2020)

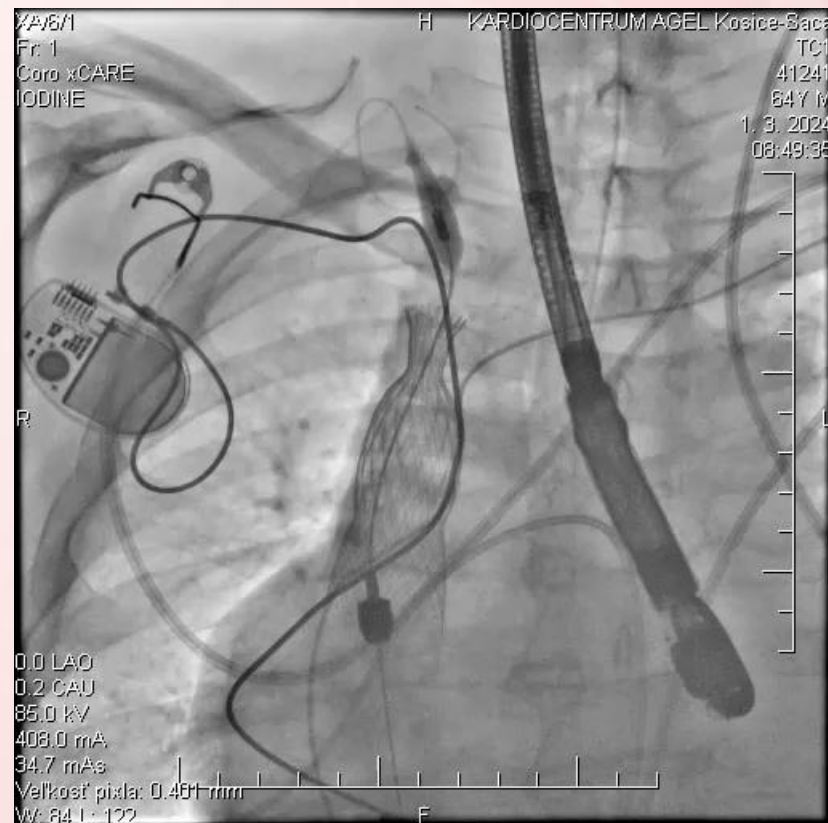
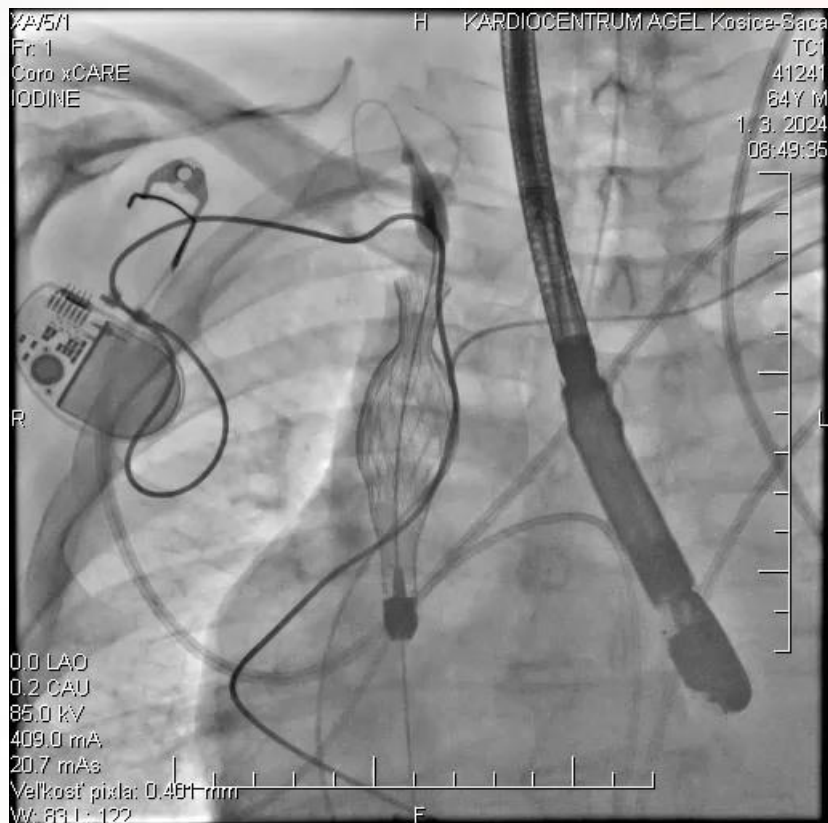
Baseline TTE



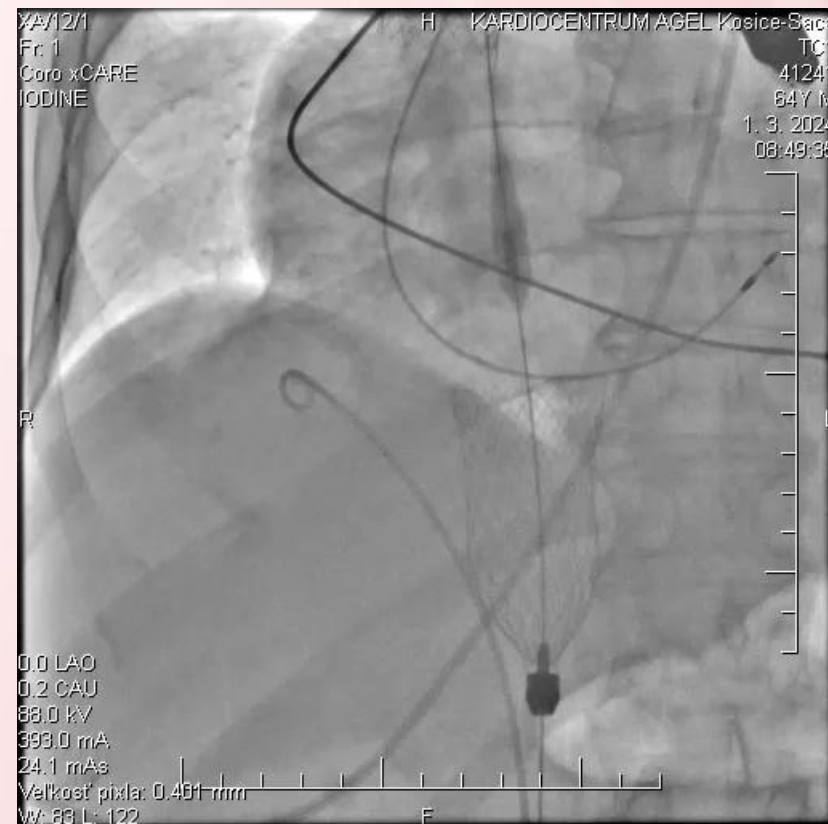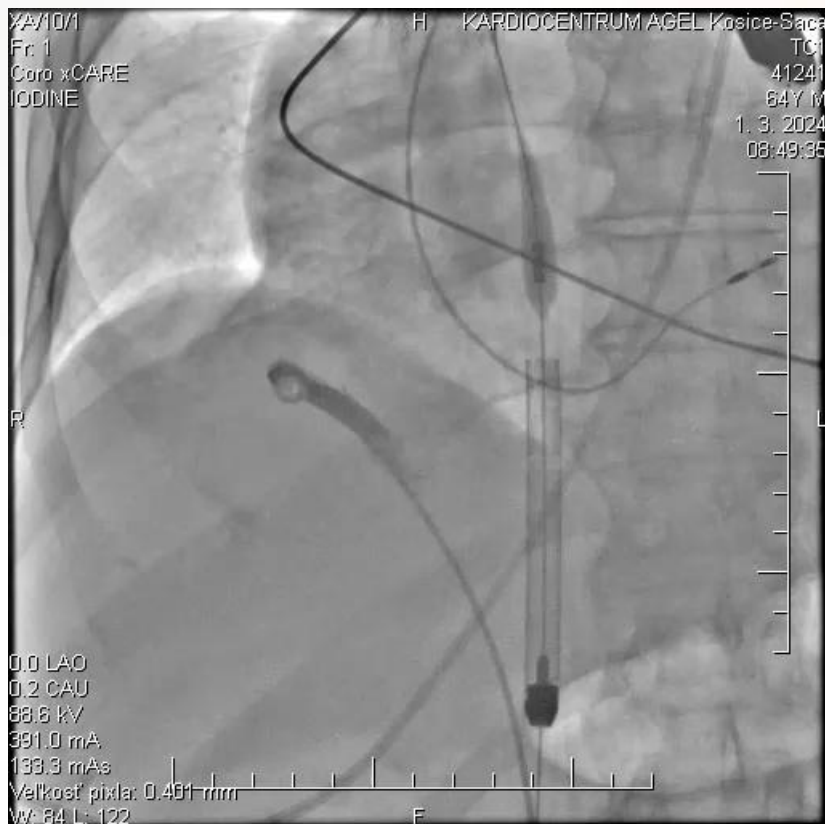Implantácia TricValve



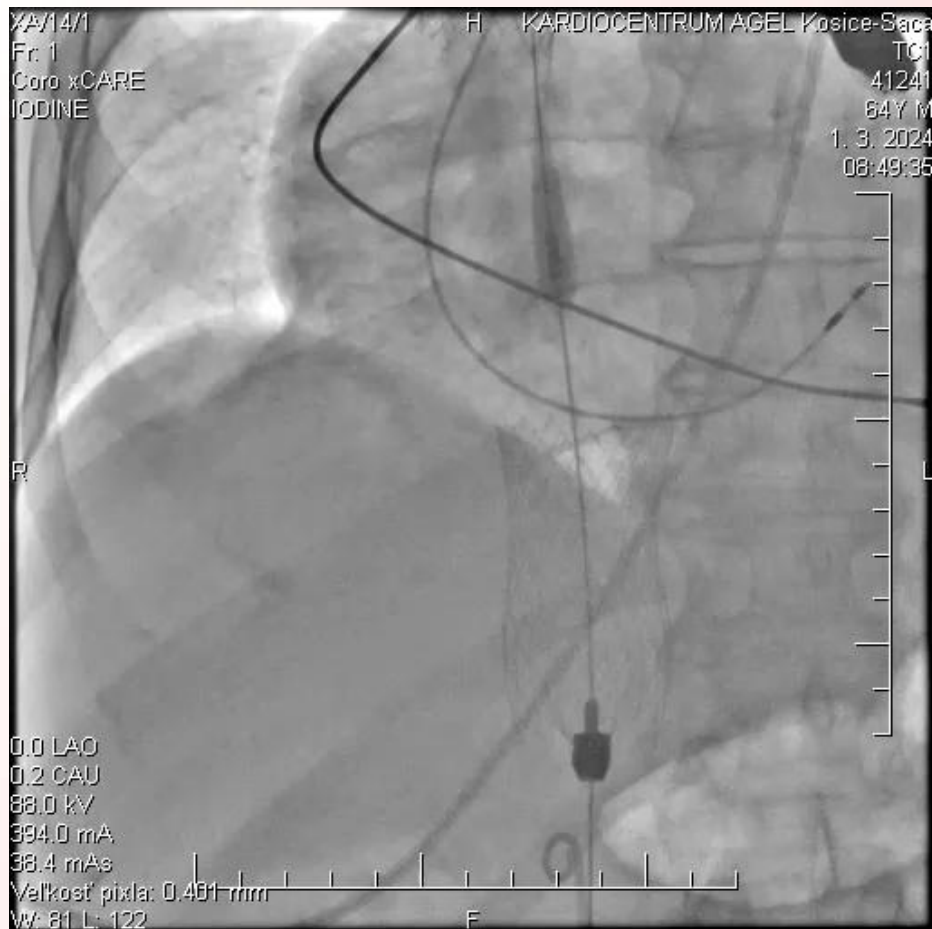
Implantácia TricValve



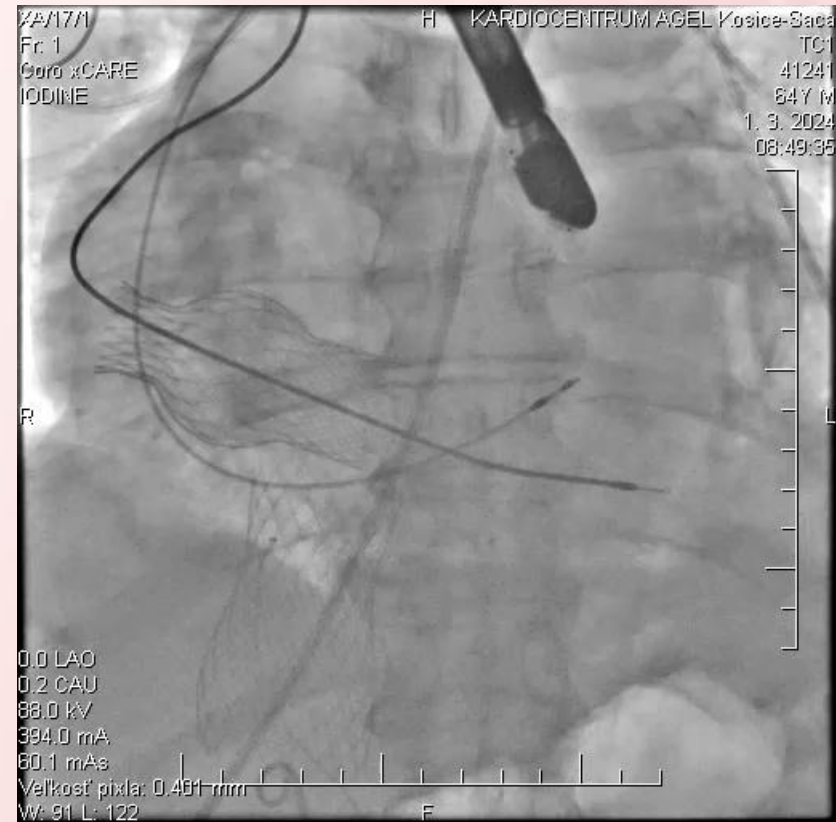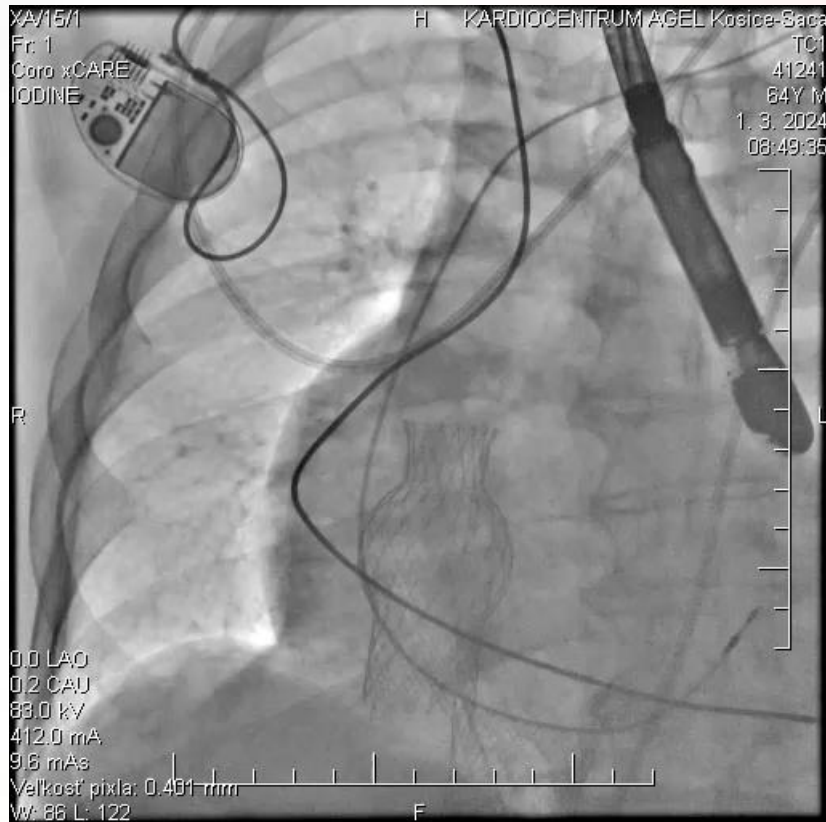
Implantácia TricValve



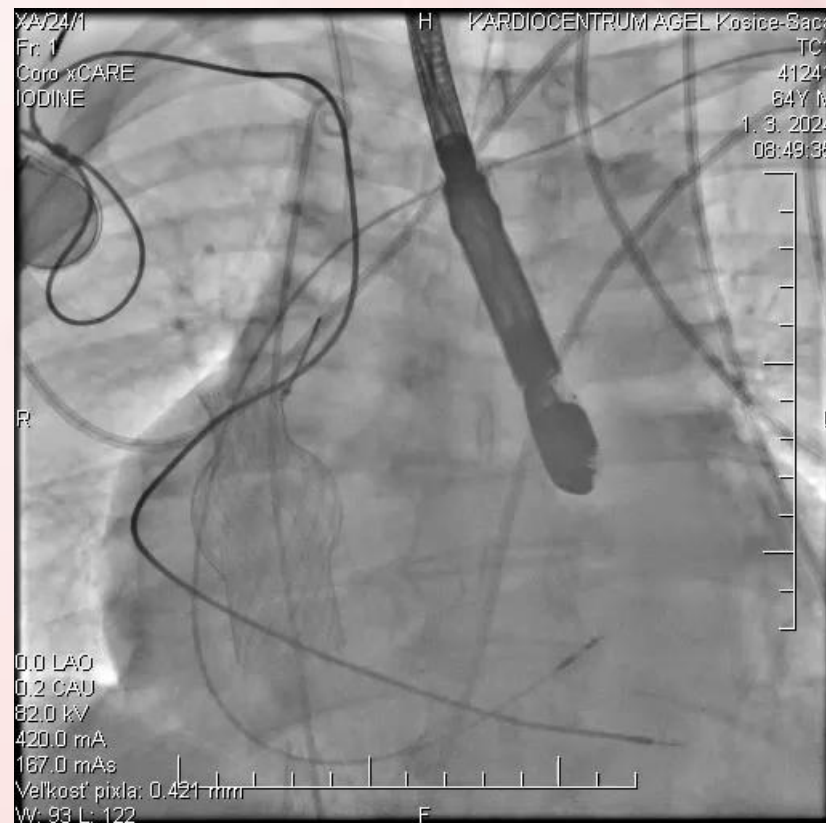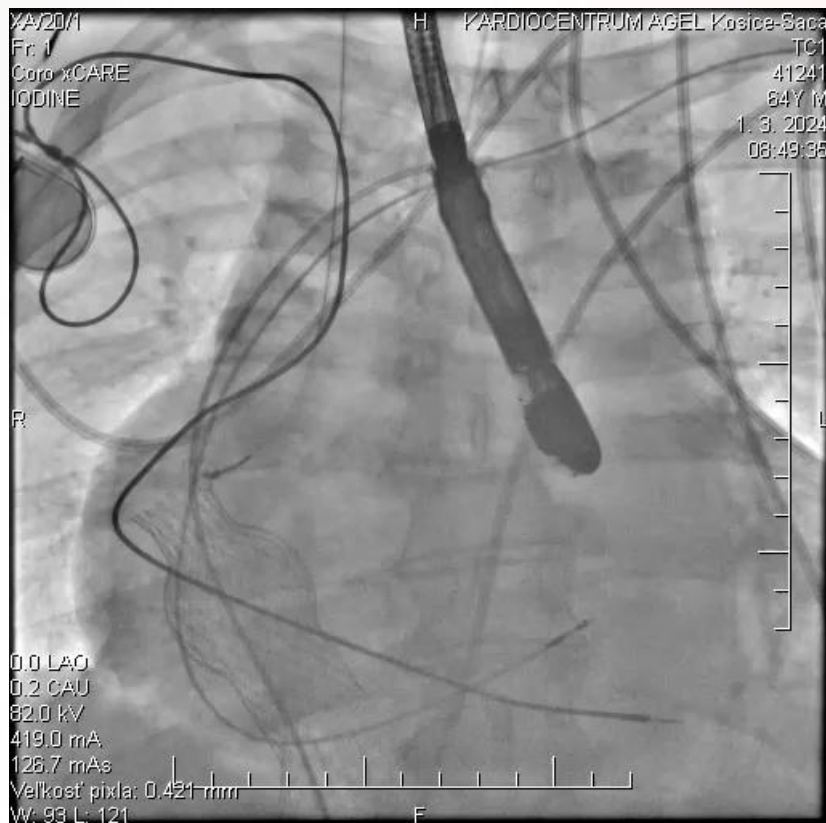
Výsledok implantácie



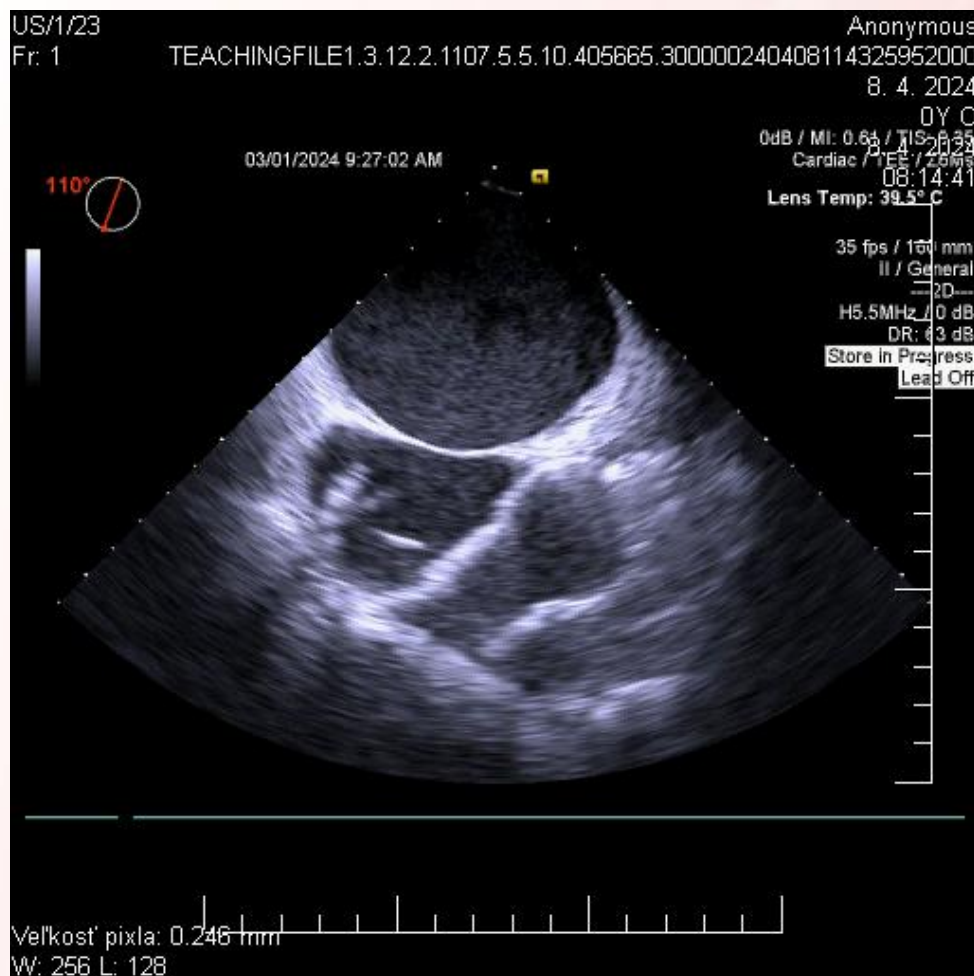
Tak sme to vytiahli



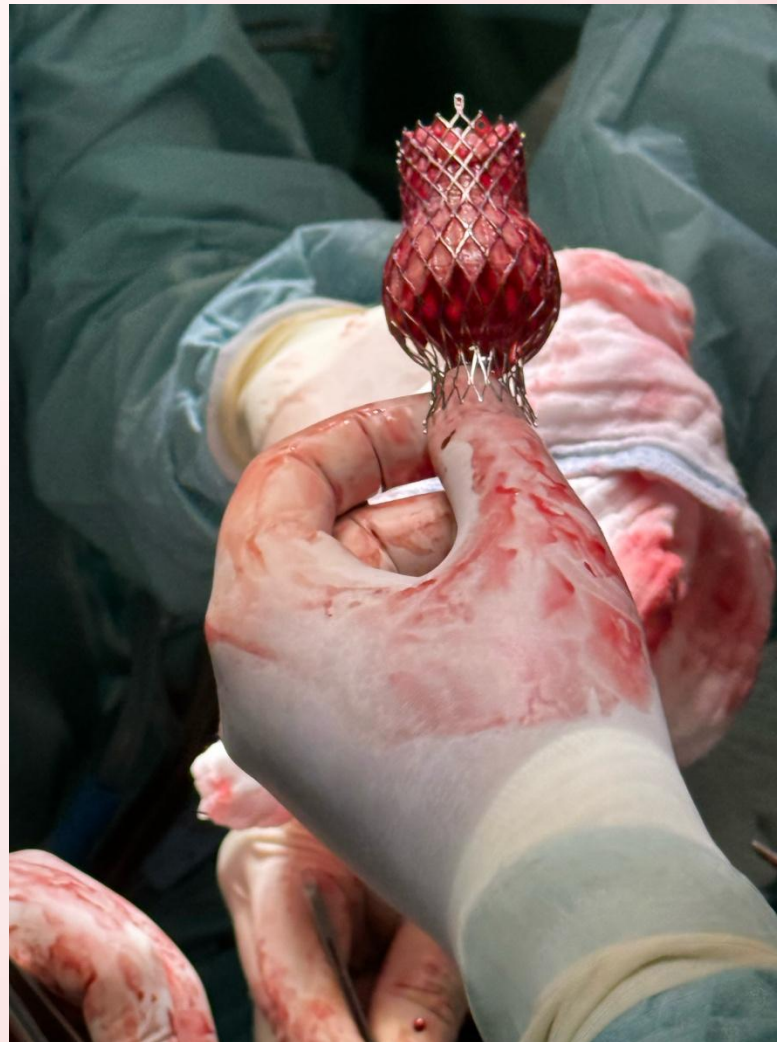
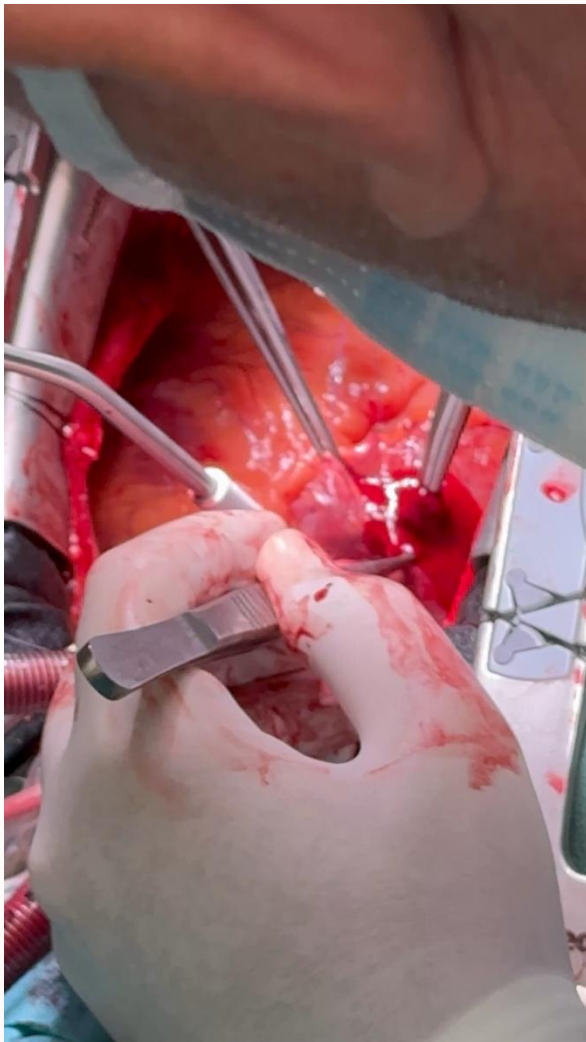
Tak sme to skúsili znova vytiahnúť



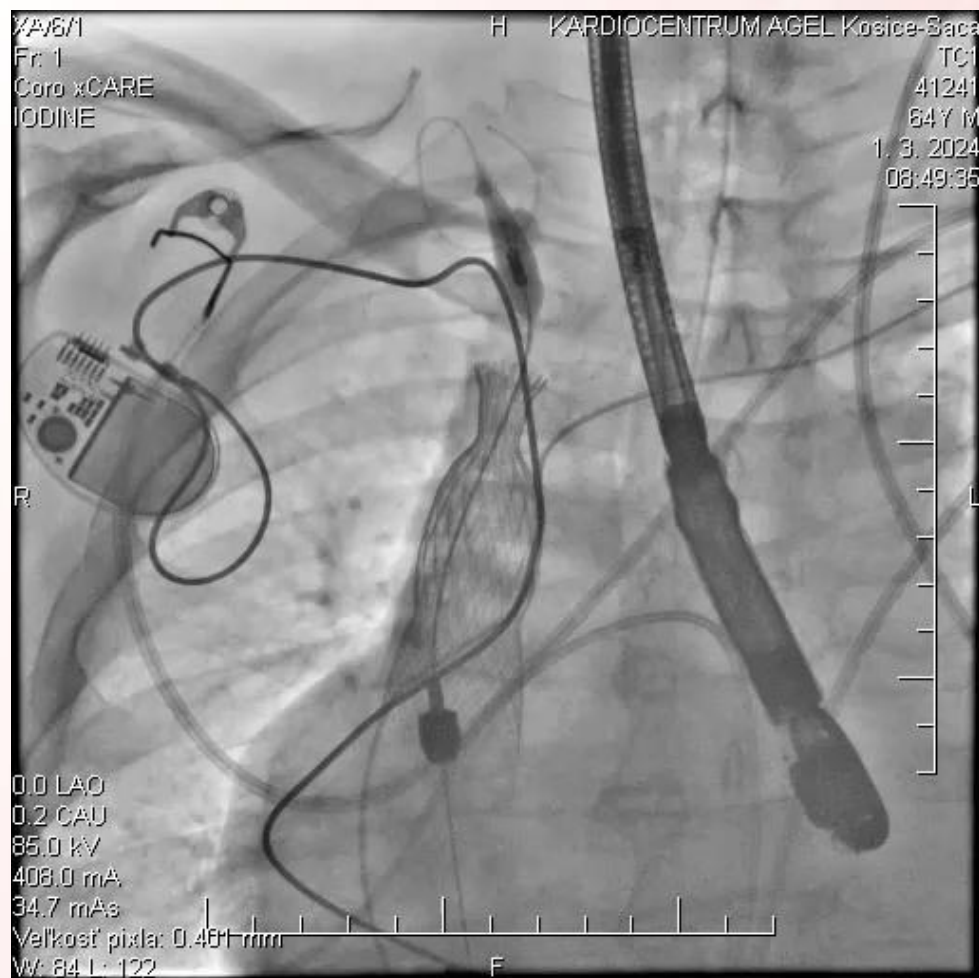
No tak sme to nevytiahli



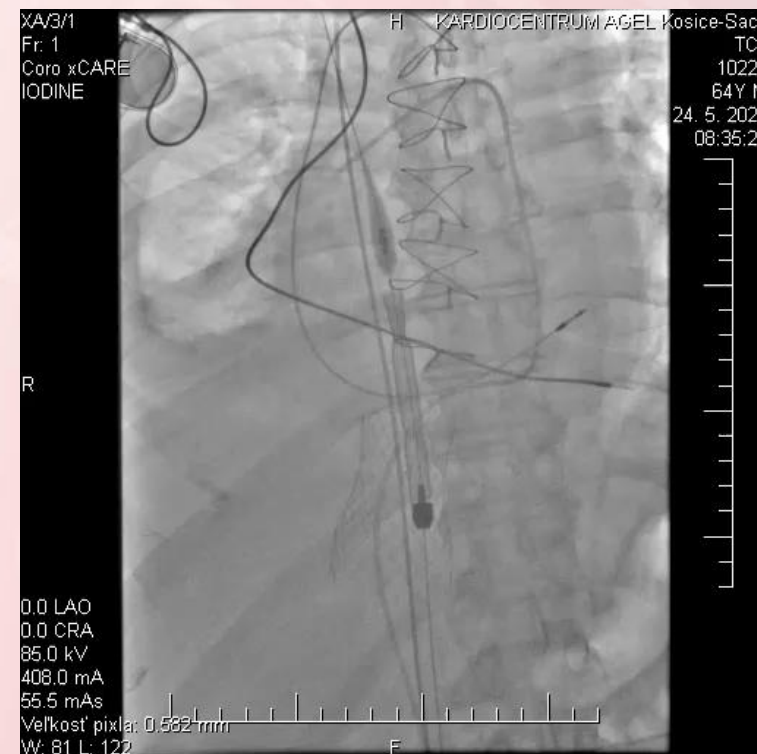
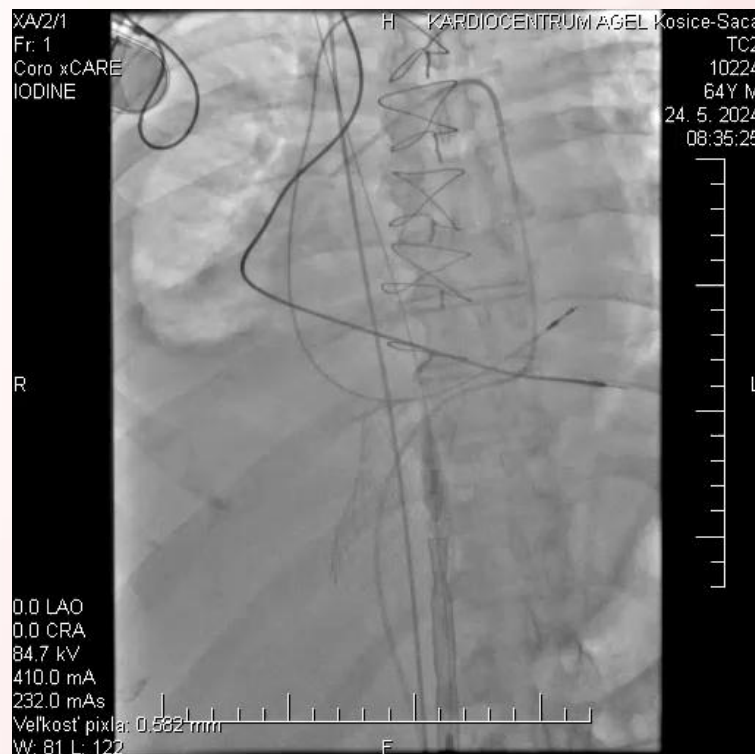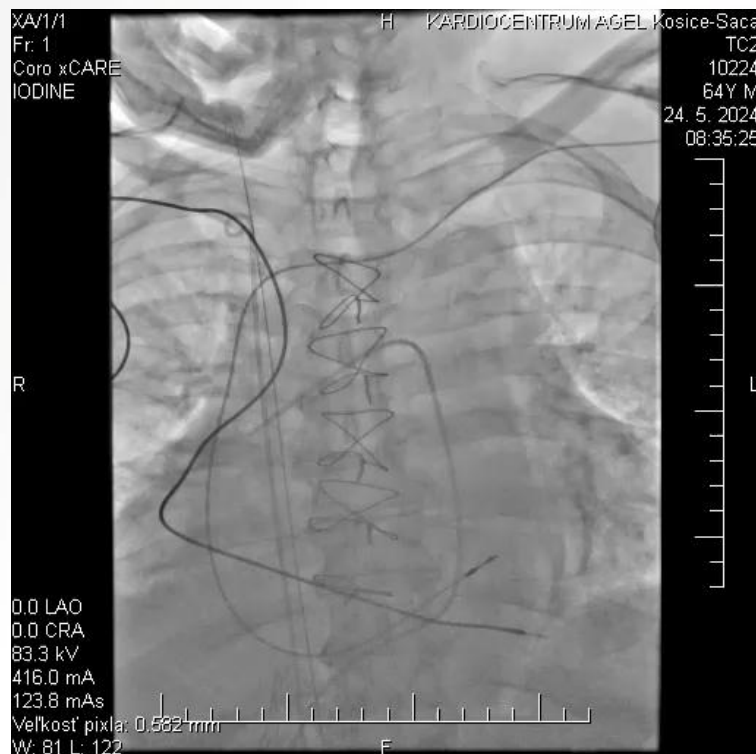Na našu hanbu sme zavolali chirurgov



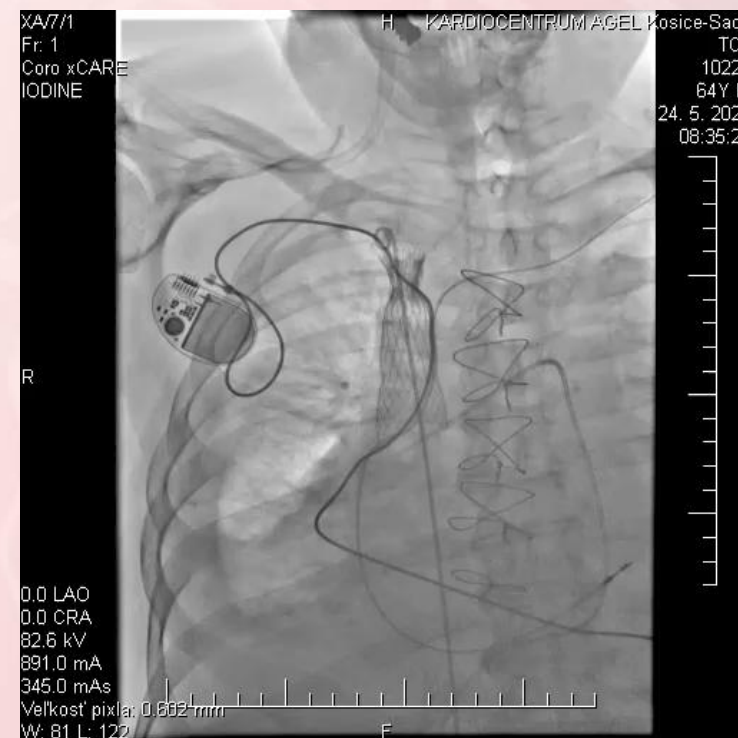
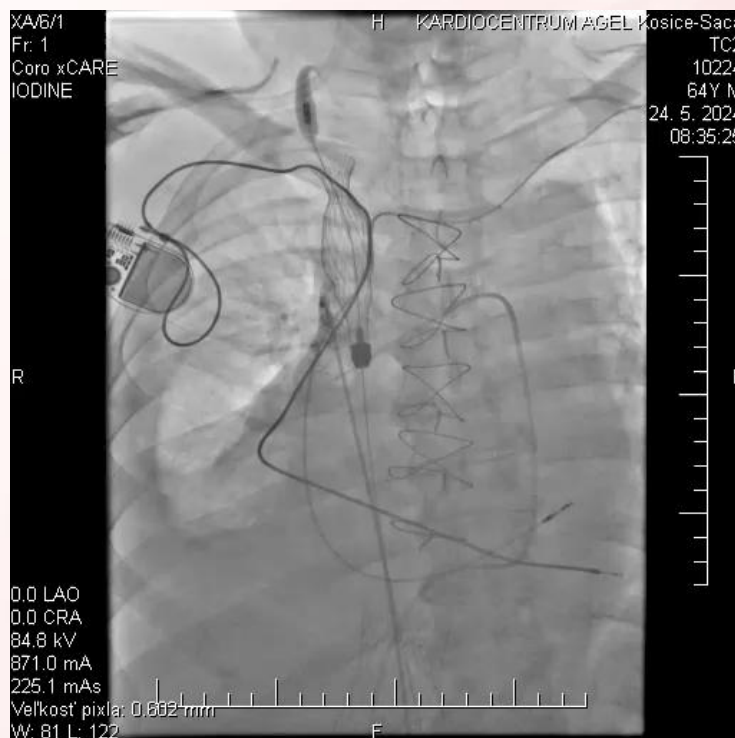
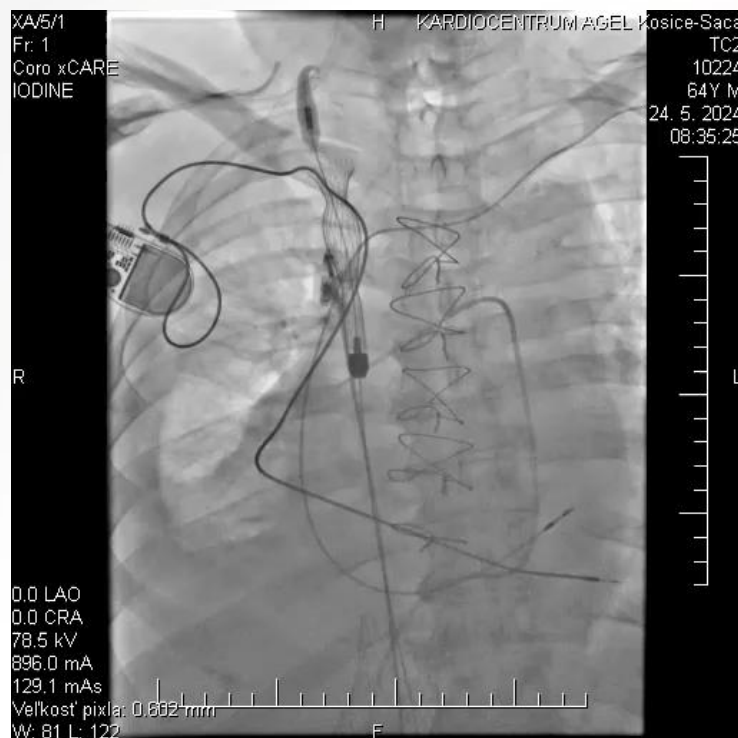
Kde bol problém?



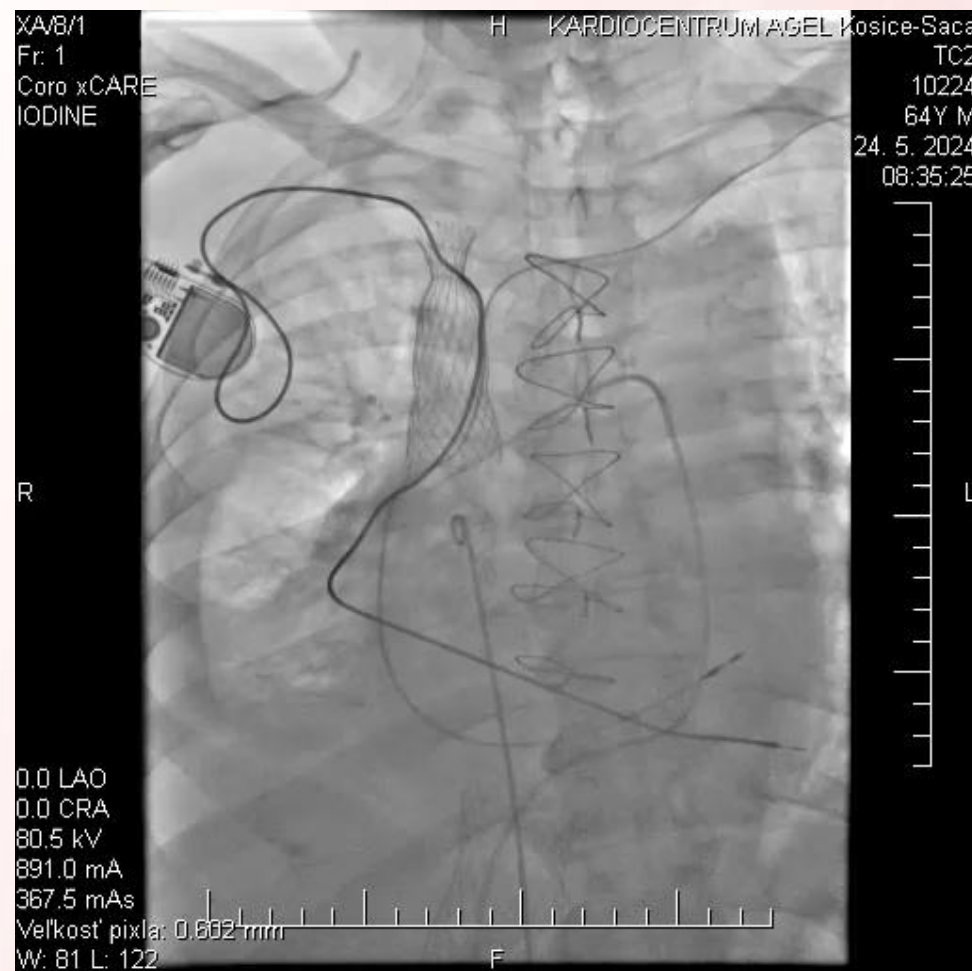
Implantácia na druhý pokus



Implantácia na druhý pokus



Implantácia na druhý pokus





SAIK

Slovenská asociácia
intervenčnej kardiológie

**Ďakujem
za pozornosť'**

2026 © SAIK