



MUDr. Martin Hudec
II. klinika kardiologickej
Oddelenie akútnej
SÚSCCH a.s. L

18.4.2024
ČAIK

Pac. po nedávno prekonanom prednom STEMI, difúznym viacievnyim postihnutím – dec 2023

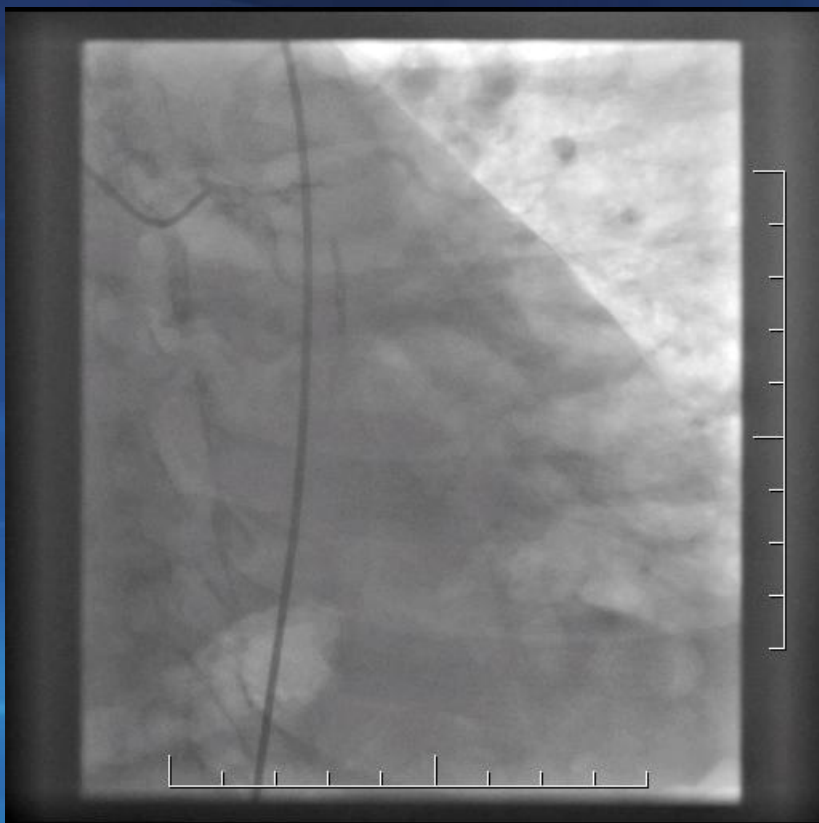
● 81 ročný muž

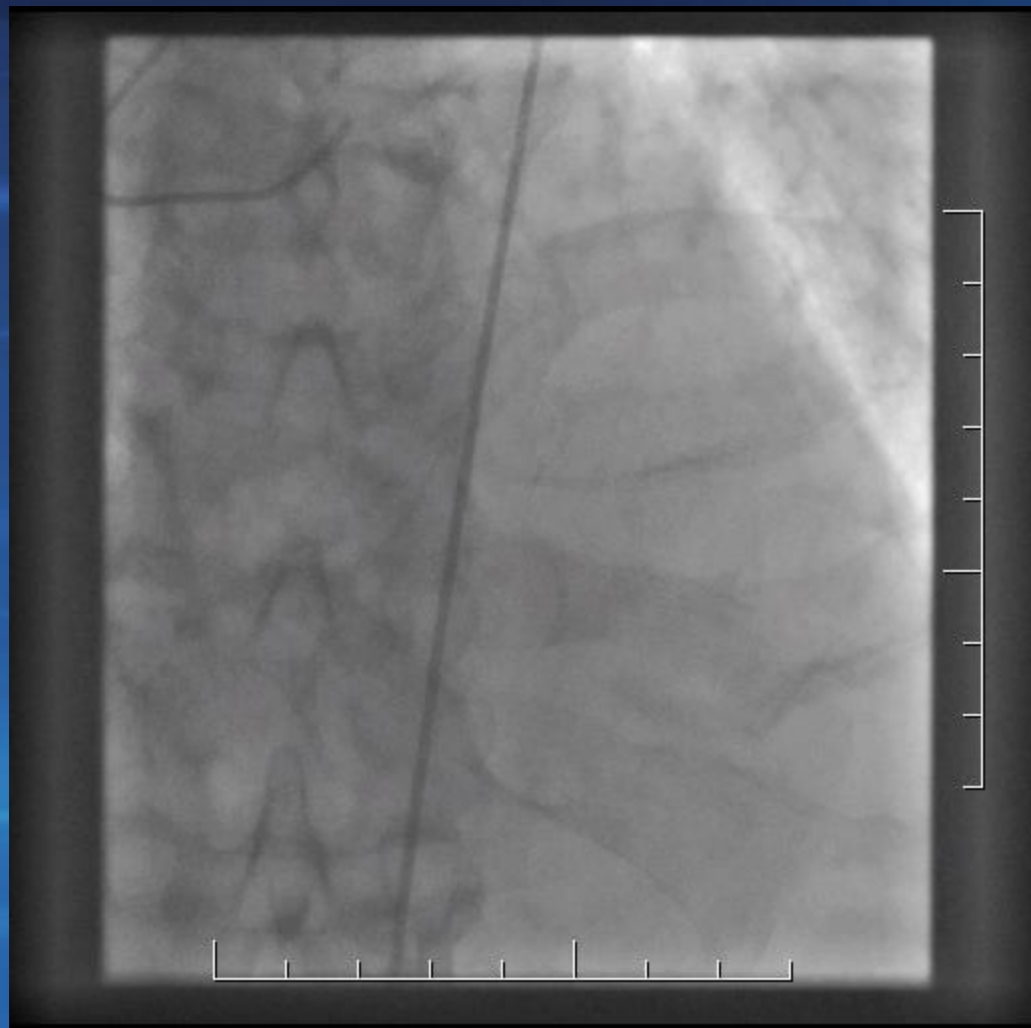
- polymorbídny pacient, s koronárnou chorobou srdca po recentne (12/2023) prekonanom STEMI prednom,
- difúznym viacievnyim postihnutím koron. aa. vrátane kritickej stenózy hlavného kmeňa LCA,
- preložený z KC v Nitre za účelom revaskularizácie myokardu. Pacient odmieta kardiochirurgické riešenie, s intervenčným riešením súhlasí.

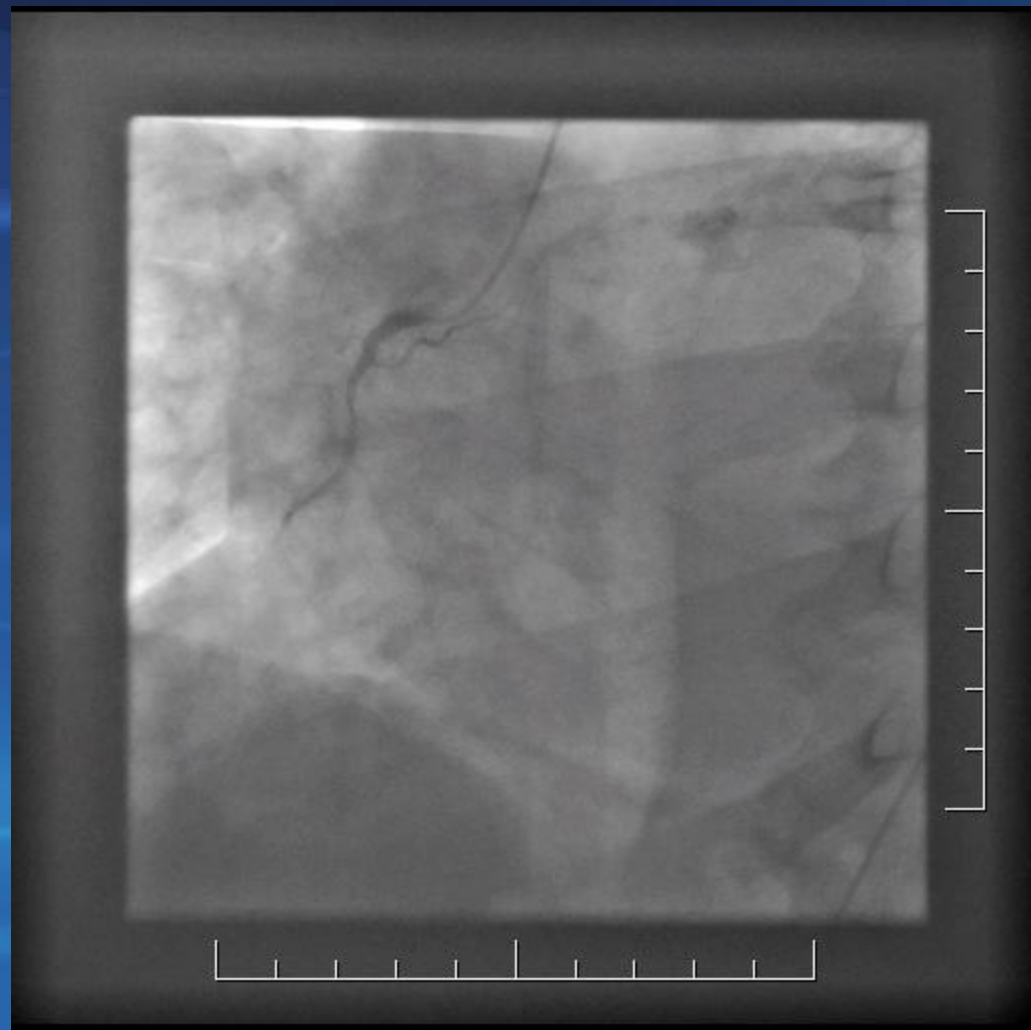
● OA:

- St. po STEMI prednej steny, MVD vrátane HK v teréne LBBB
- Novodiagnostikované srdcové zlyhávanie s redukovanou EF na 25-30%
- - na podklade CAD, vstupne NYHA IV, aktuálne rekompensovaný
- - fluidthorax bilat., st.p.punkcii I.dx. 27.12.2023
- Fibrilácia predsiení v dok.
- - st.p.CMP
- Art. hypertenzia
- DM 2.typu na PAD
- - v št. chronických komplikácií (makroangiopatia- PAO DK- st.p.amputácii oboch DK)
- - diabetická nefropatia,
- Chronická anémia ľahk.st.
- Dyslipoproteinémia
- A. hypertenzia 1.st. s veľmi vysokým KVS rizikom
- Stav po úraze ľHK v detstve s operačným riešením

Echokardiograficky je LK nedilatovaná, so závažnou systolickou dysfunkciou s EF 25-30% pri difúznej hypokinéze ĽK, bez významných chlopňových chýb.
RTG hrudníka s obrazom stázy v MO, fluidthorax



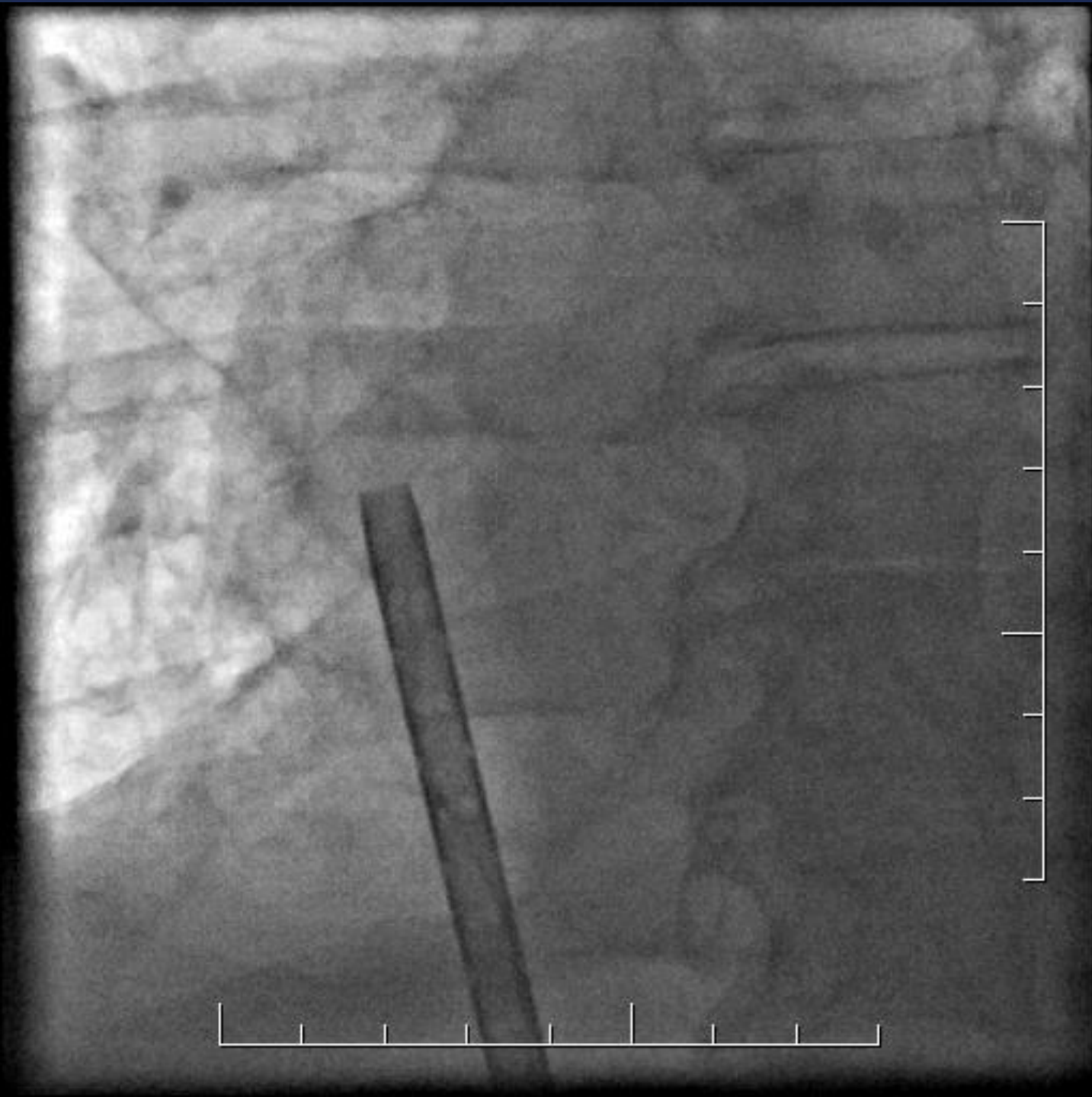




Preklad z KC Nitra, plánovaná PCI HK/RIA/RCX za
ECMO podpory...

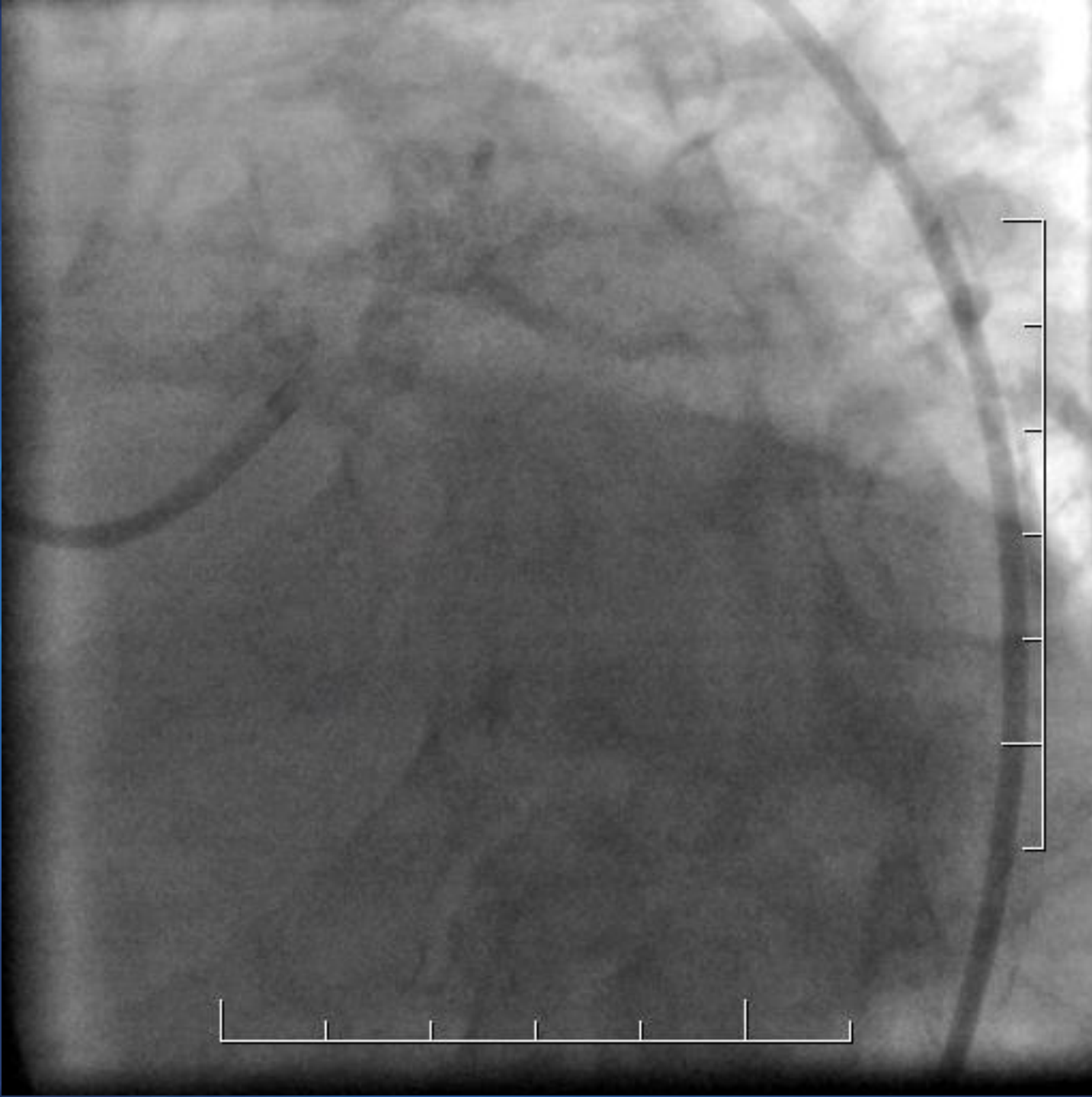
PCI: HK/RIA/RCX + ECMO

- Zavedenie V-A ECMO femorálne



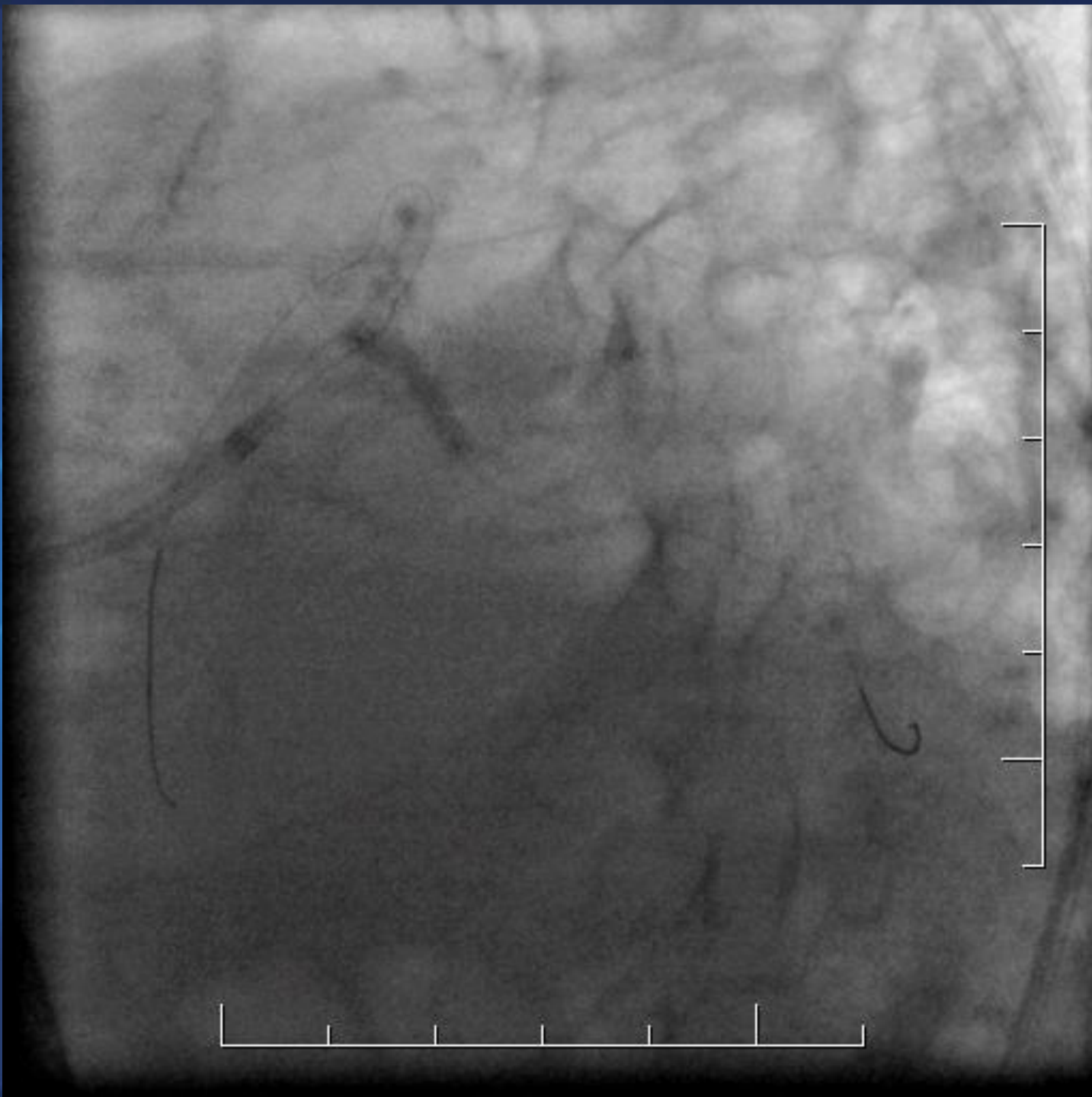
PCI: HK/RIA/RCX

- 7F EBU3,5
- 2x Sion –RIA/RCX



PCI: HK/RIA/RCX

- Dilatácia
 - SCB 2,0x15mm,
 - NCB 3,0x15mm 24atm

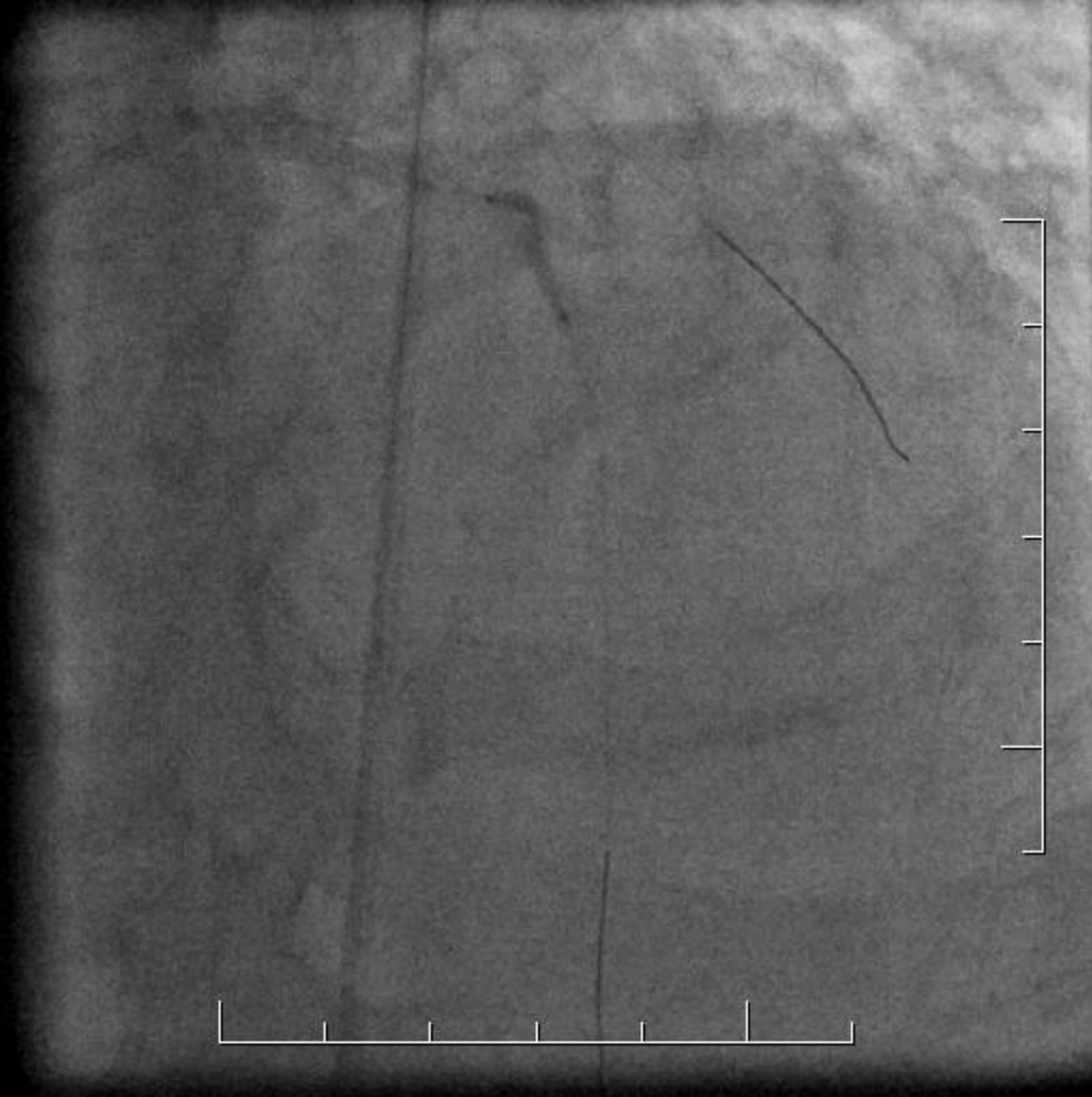


PCI: HK/RIA/RCX

- Dilatácia
 - SCB 2,0x15mm,
 - NCB 3,0x15mm 24atm

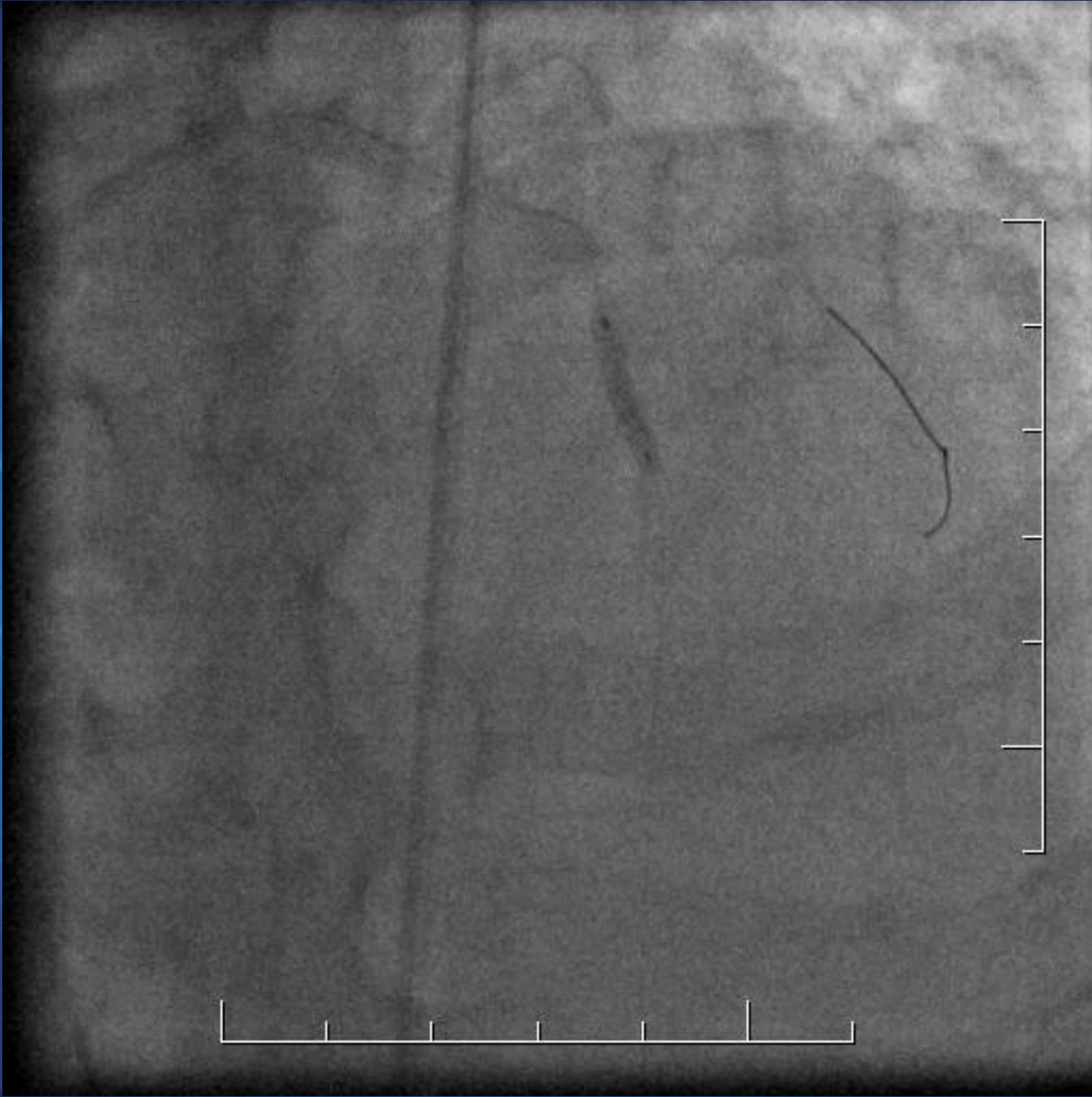
PCI: RIA

- Dilatácia
 - SCB 2,0x15mm,
 - NCB 2,5x20mm 20atm
 - NCB 3,0x20mm 22atm



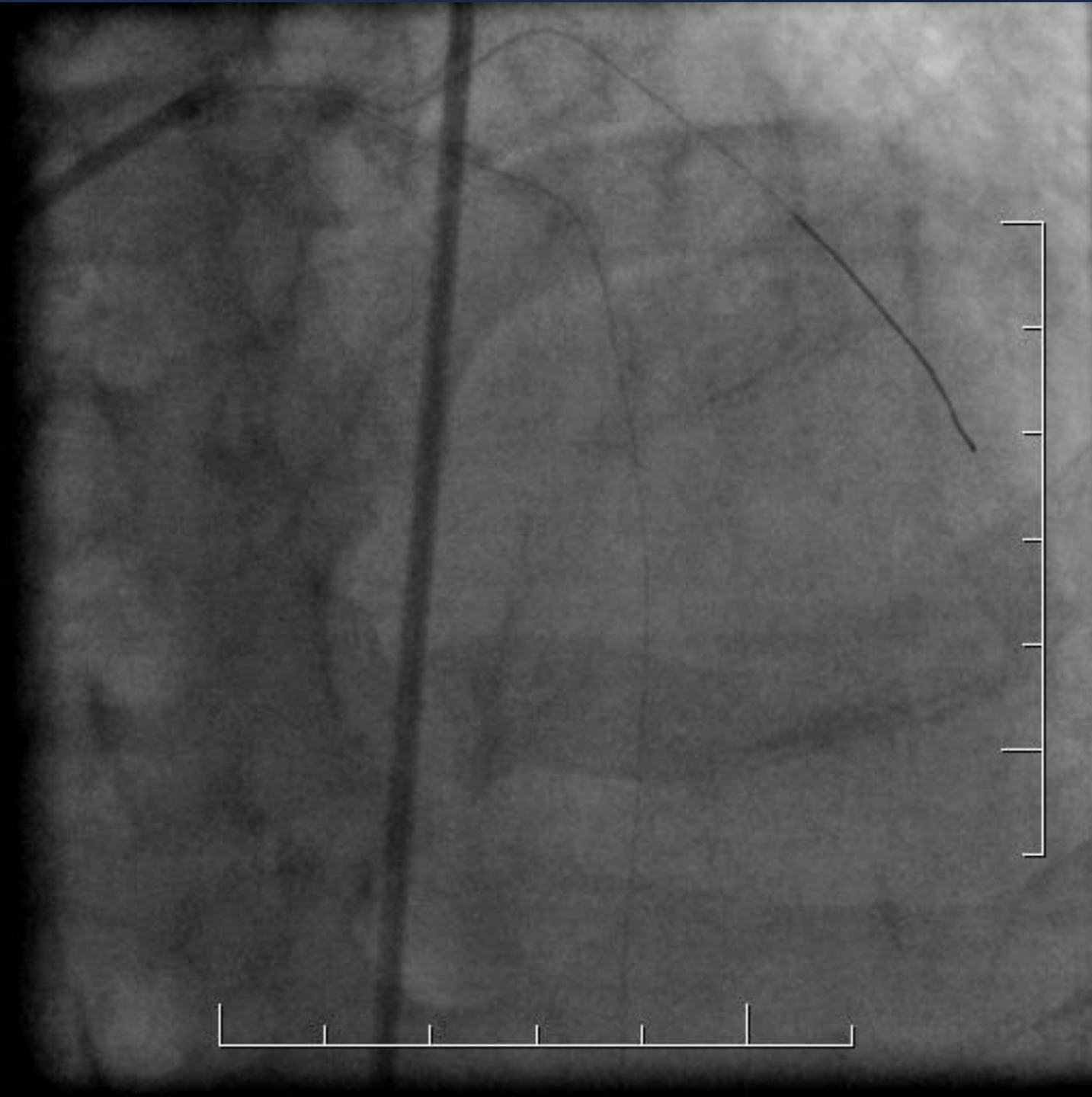
PCI: RIA

- Dilatácia
 - SCB 2,0x15mm,
 - NCB 2,5x20mm 20atm
 - NCB 3,0x20mm 22atm



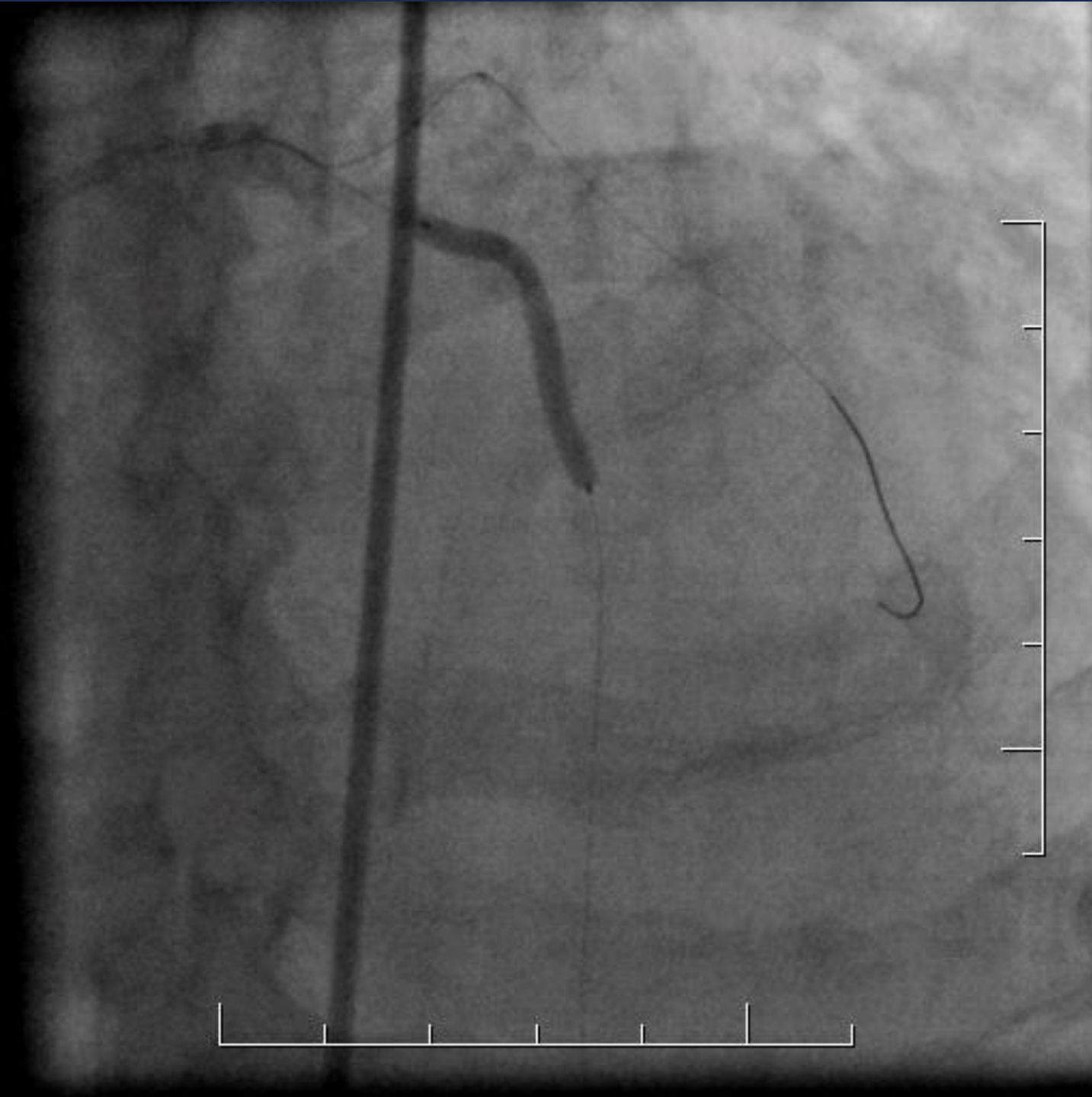
PCI: RIA

- Hlboká disekcia mRIA



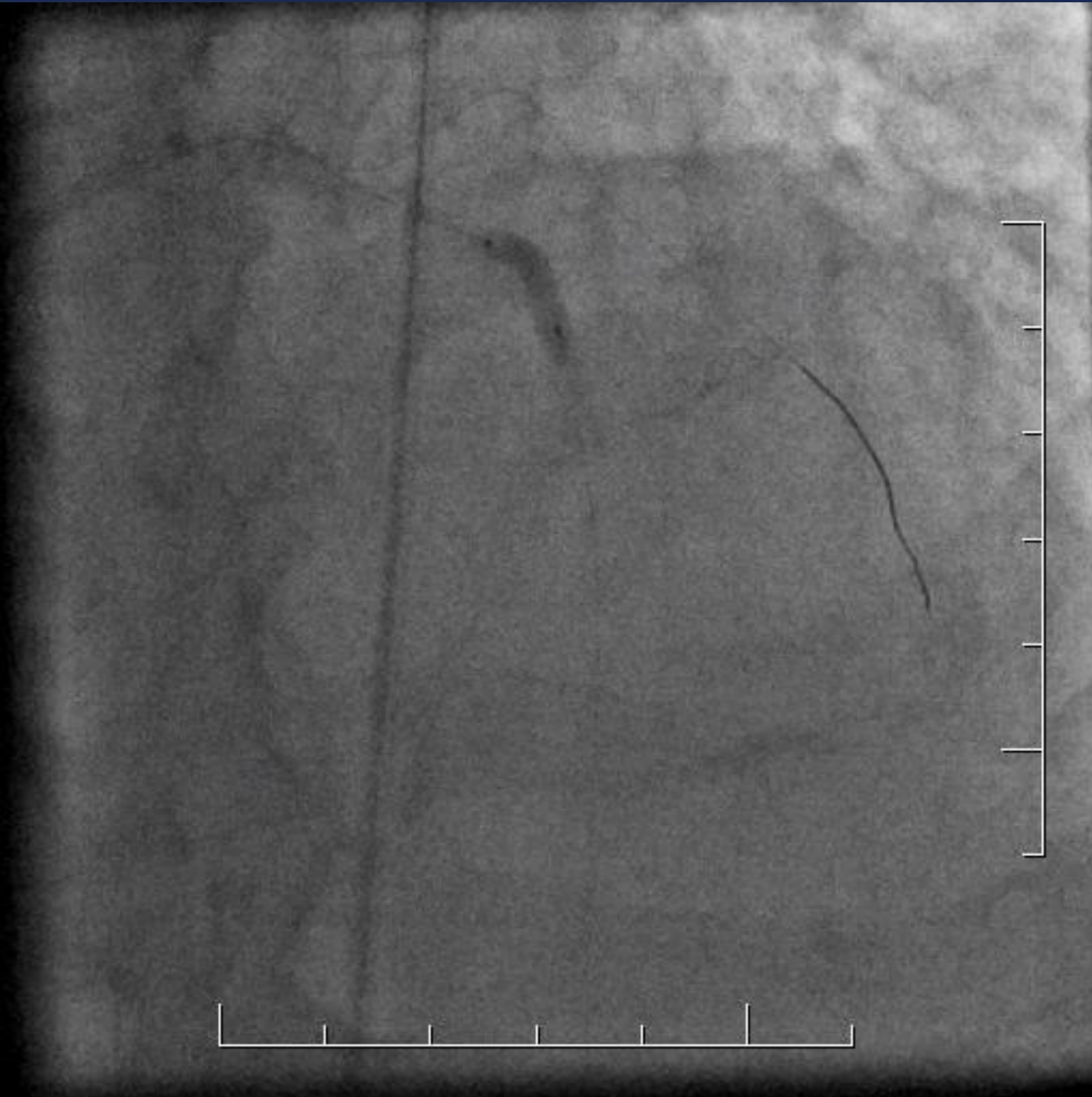
PCI: RIA

- Za pomoci anchoringu implantácia
 - DES Orsiro 3,0x35mm 14atm



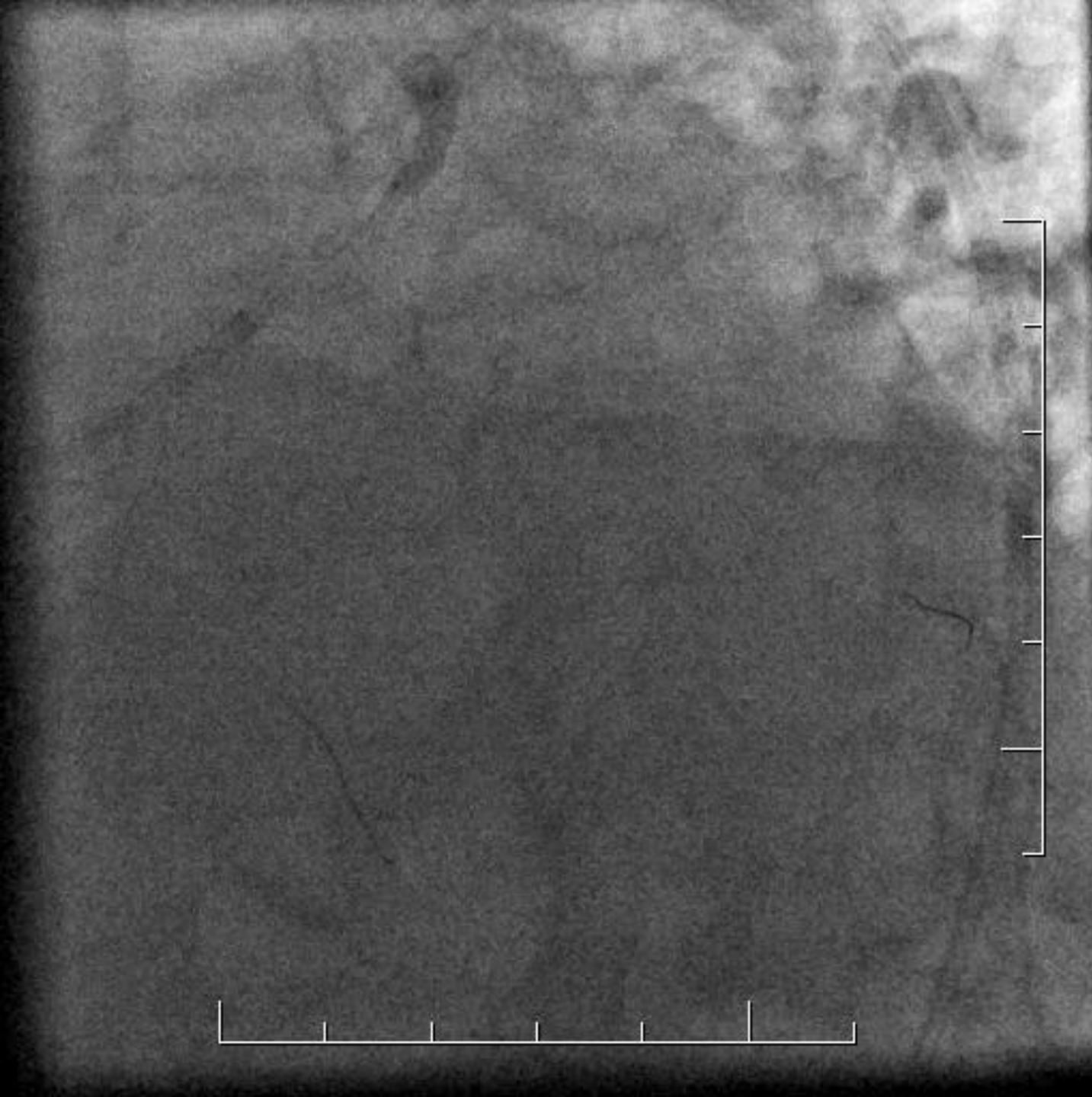
PCI: RIA

- POT na 18atm



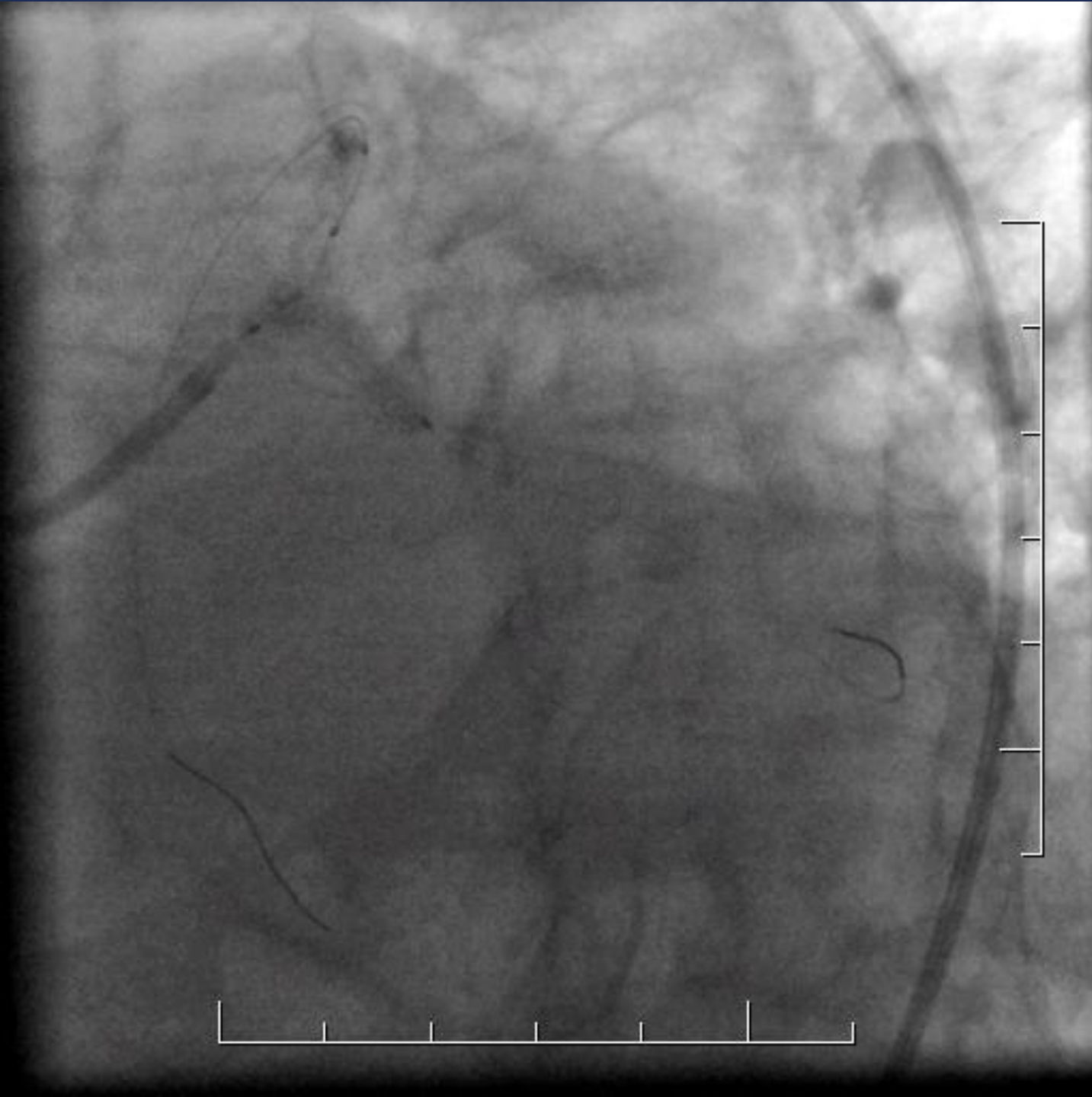
PCI: RCX

- Za pomoci anchoringu implantácia
 - DES Elunir 3,5x20mm 14atm



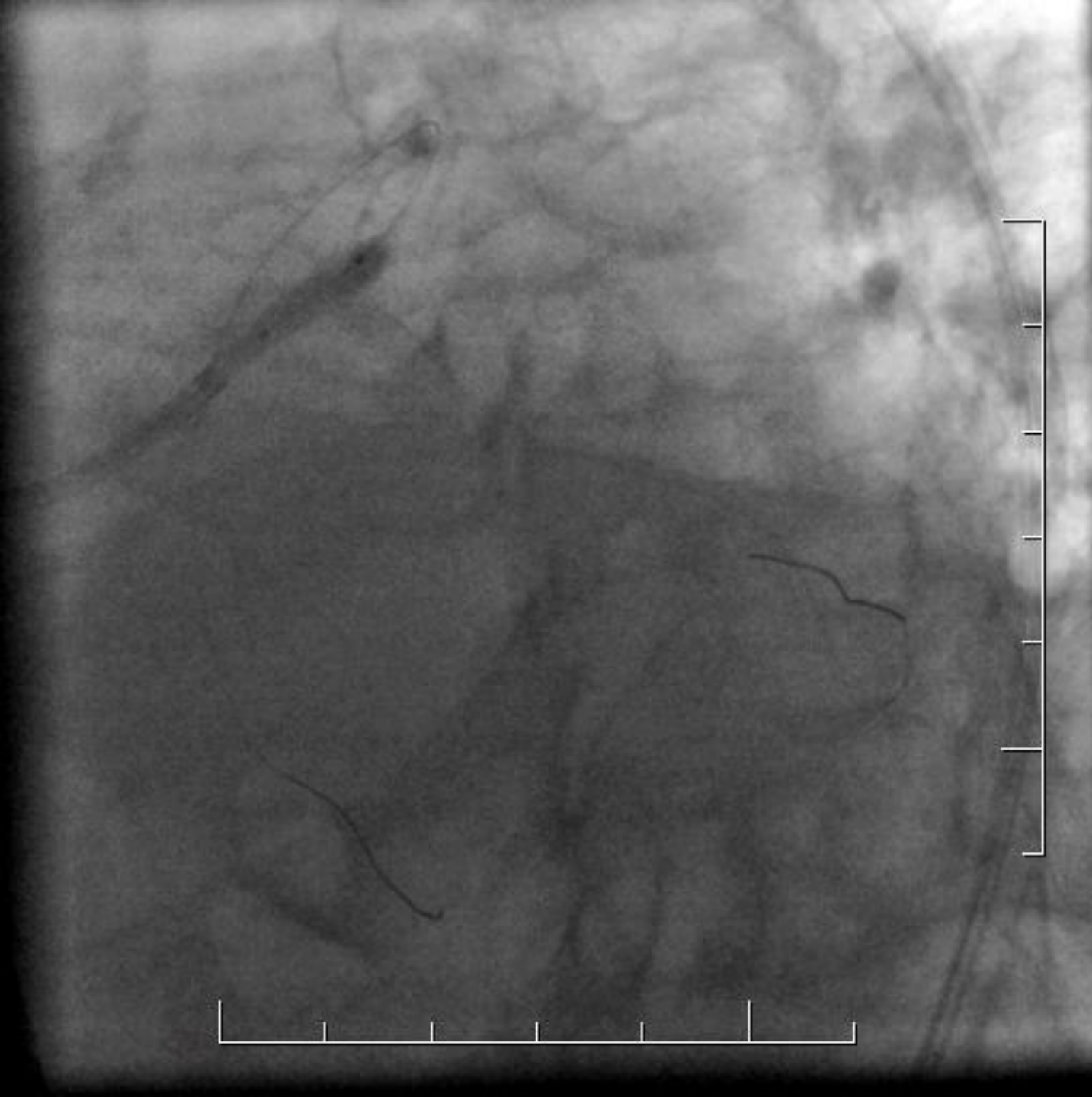PCI: RCX

- Za pomoci anchoringu implantácia
 - DES Elunir 3,5x20mm 14atm



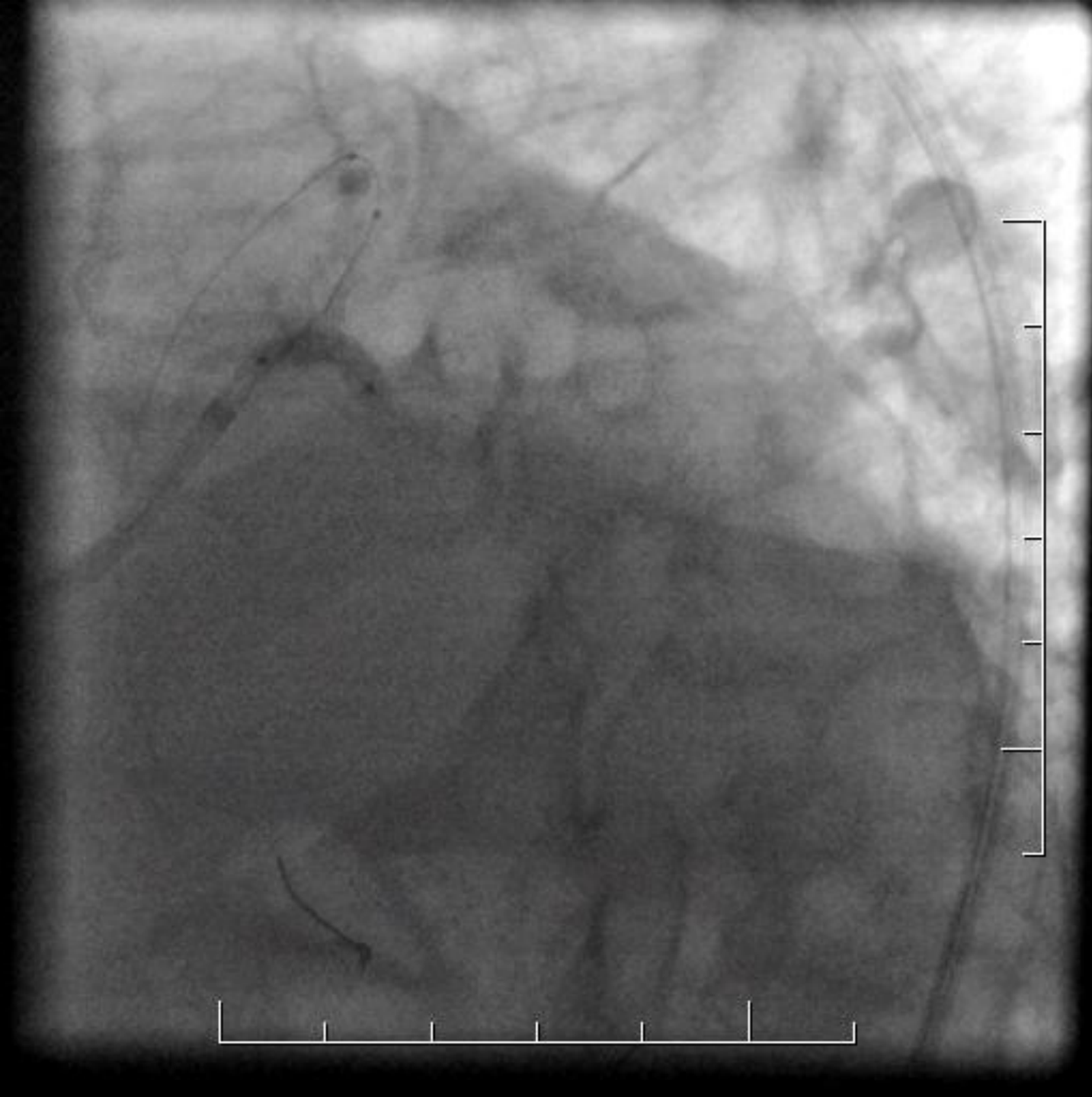
PCI: RCX

- CRUSH stentu NCB 3,5x15mm 24atm



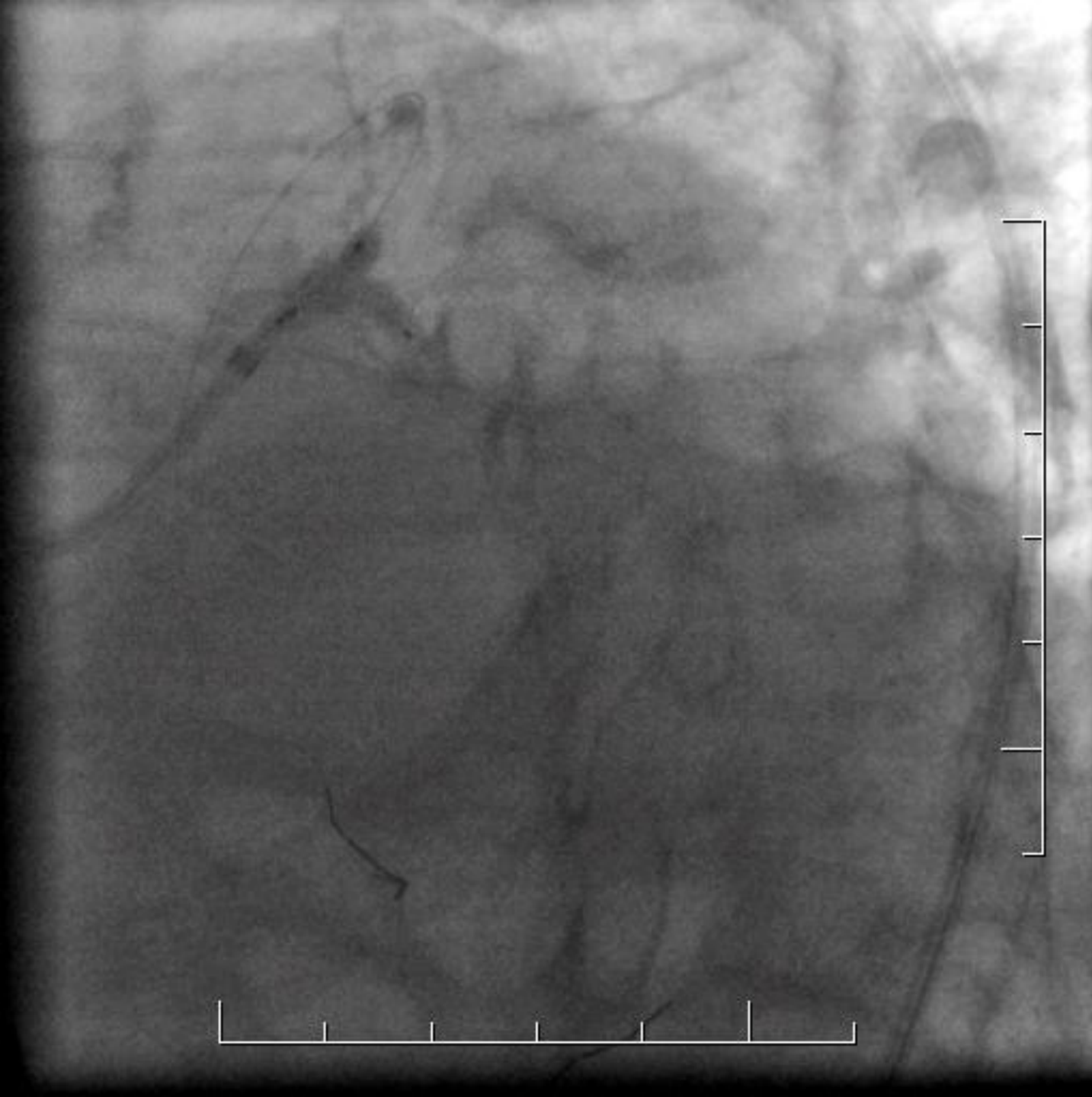PCI: RCX

- Rewiring RCX
- Dilatácia oka stentu
 - SCB 2,0x15mm
 - NCB 3,5x15mm 26atm



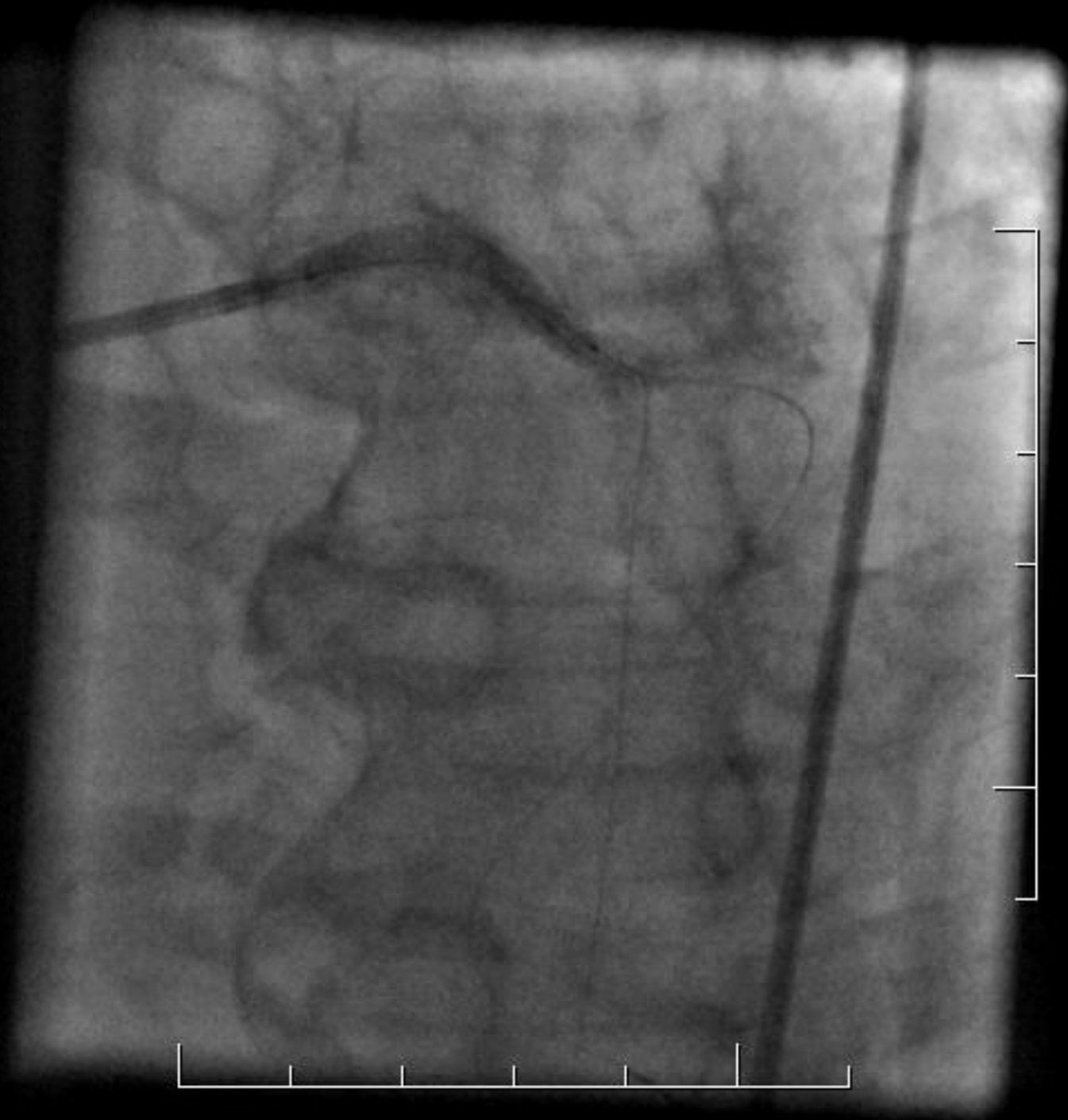PCI: HK/RIA/RCX

- 1. kissing
 - 2x NCB 3,5x15mm 10atm



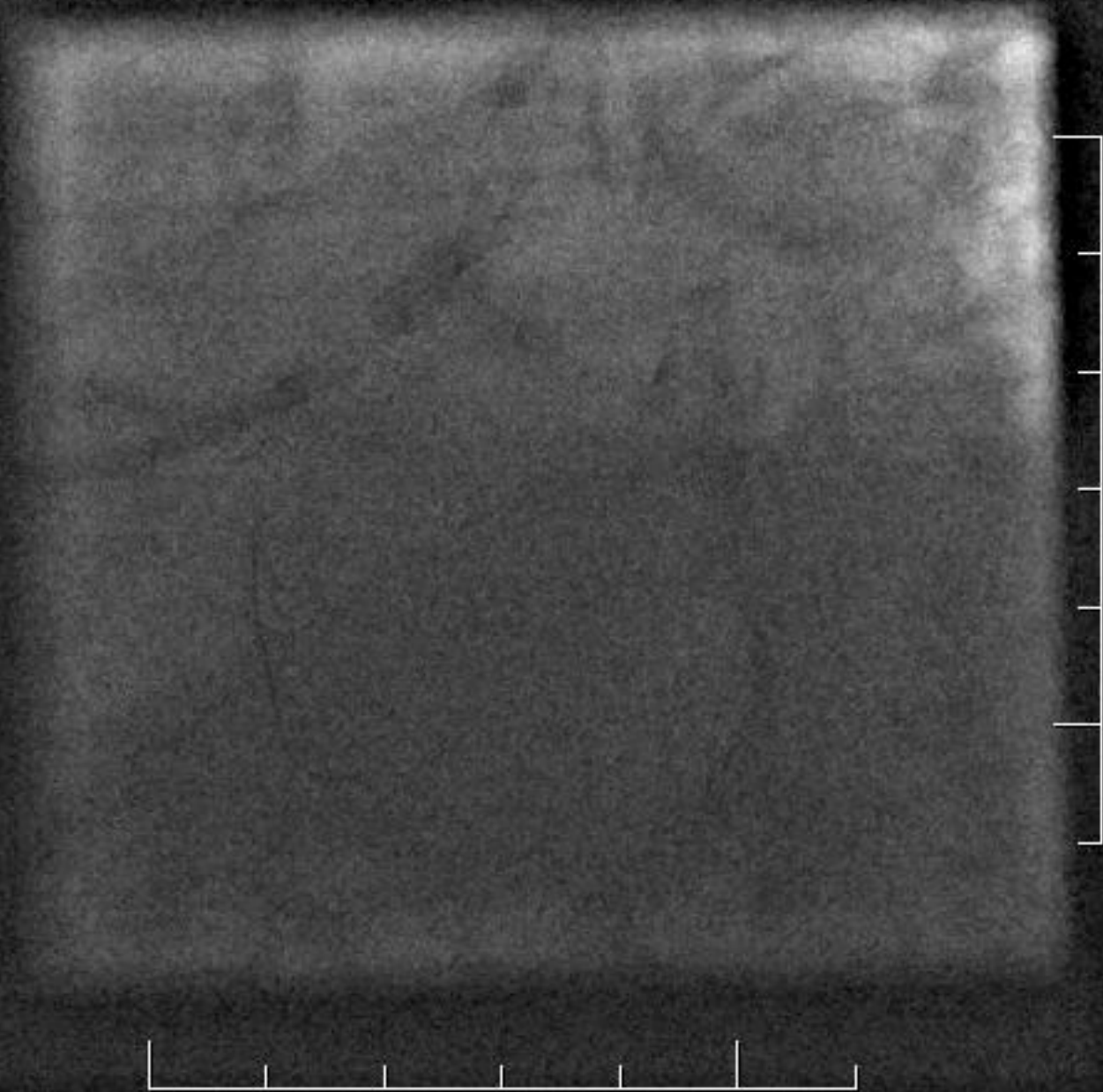
PCI: HK-RIA

- Implantácia DES od ostia HK do RIA
 - Orsiro 3,5x35mm 16atm



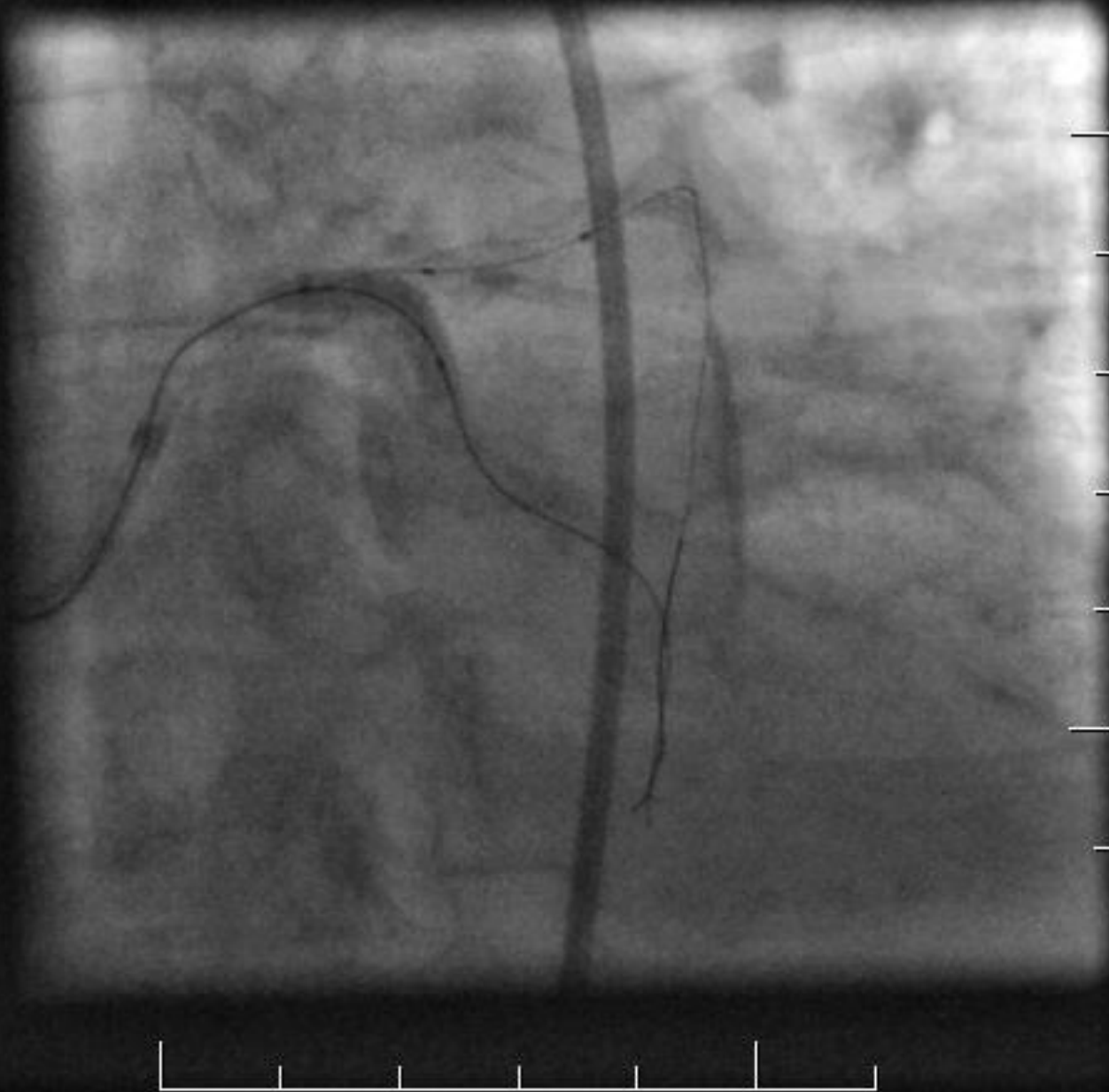
PCI: HK/RIA/RCX

- POT 4,5x8mm 24atm



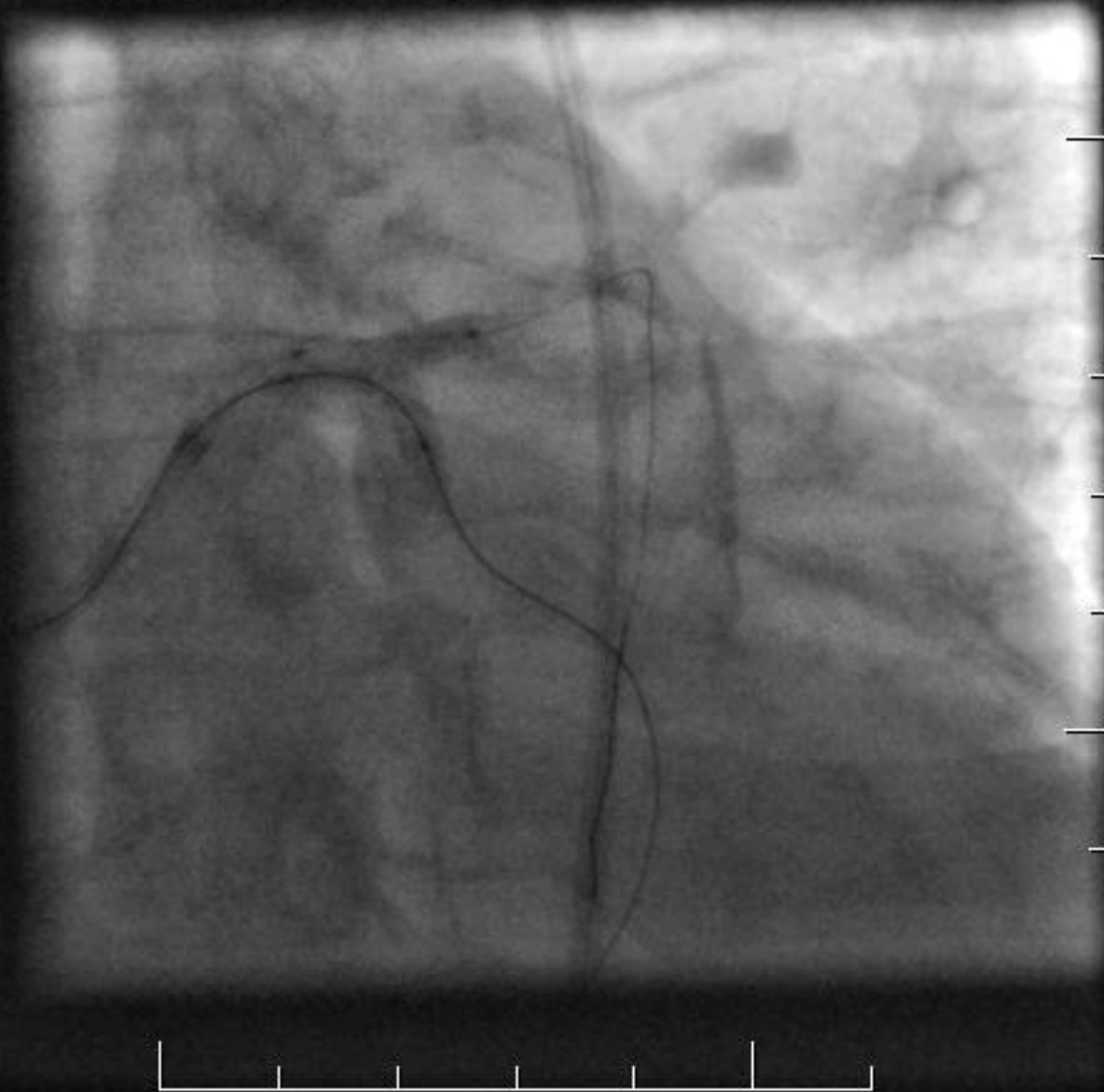
PCI: HK/RIA/RCX

- Rewiring RCX
 - Dilatácia oka stentu SCB 1,5x15mm
 - NCB 3,5x15mm 28atm



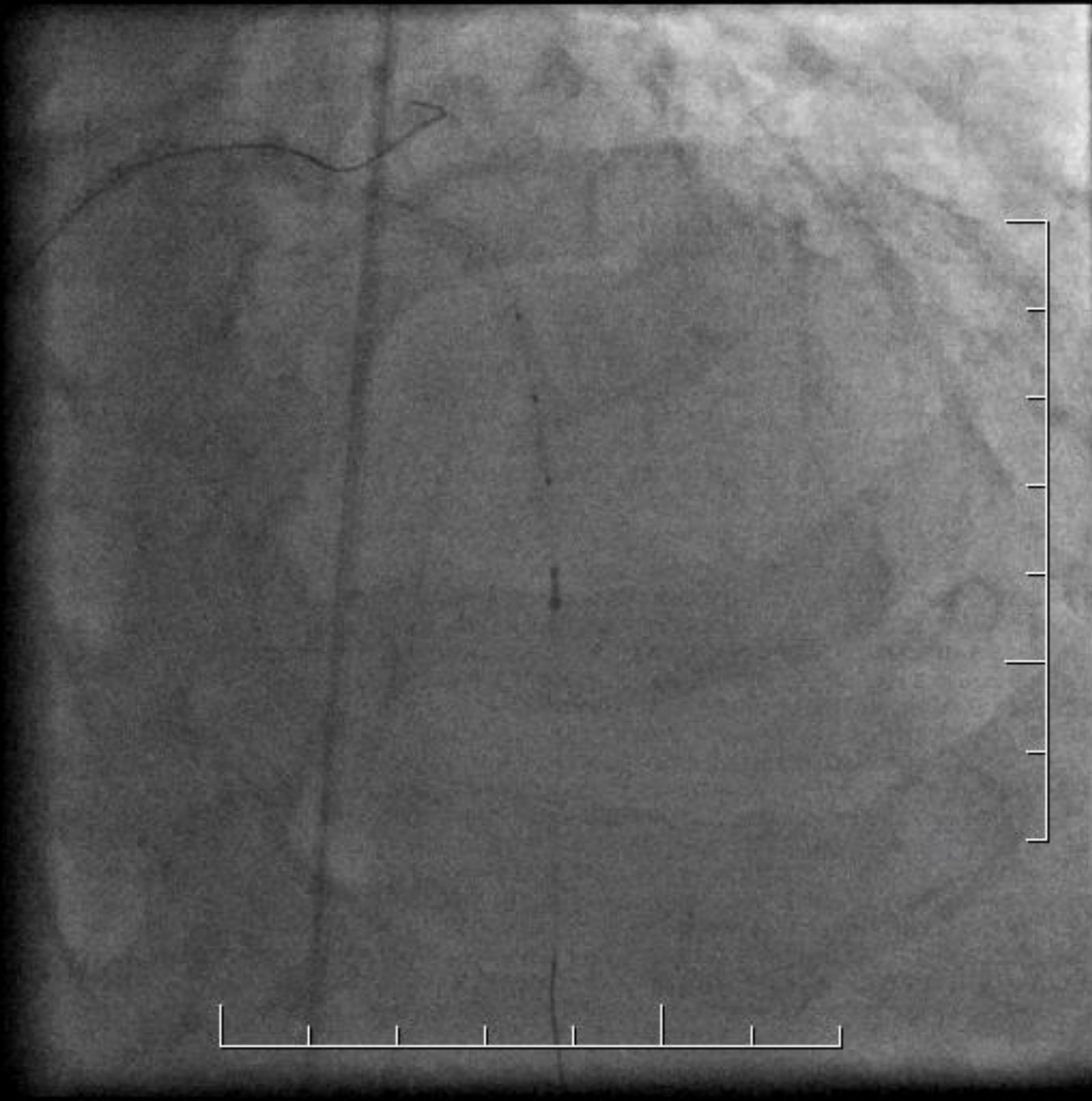
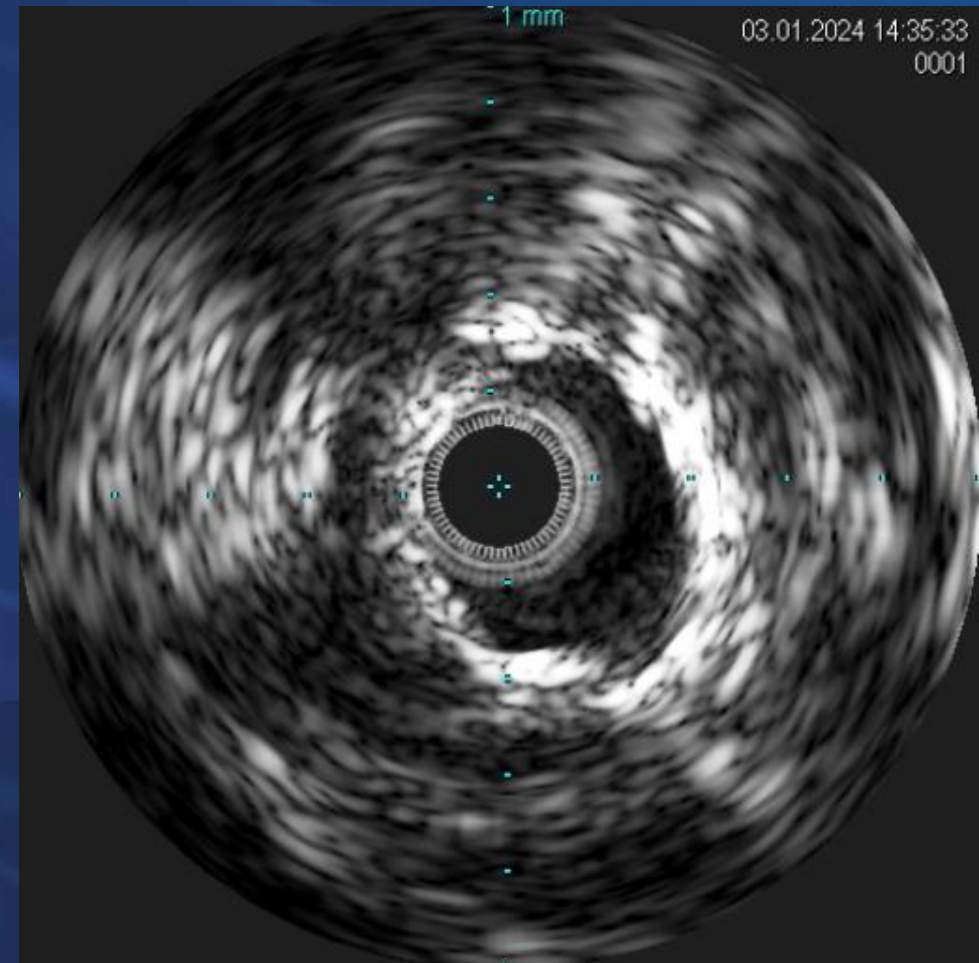
PCI: HK/RIA/RCX

- 2. kissing
 - 2x NCB 3,5x15mm 10atm



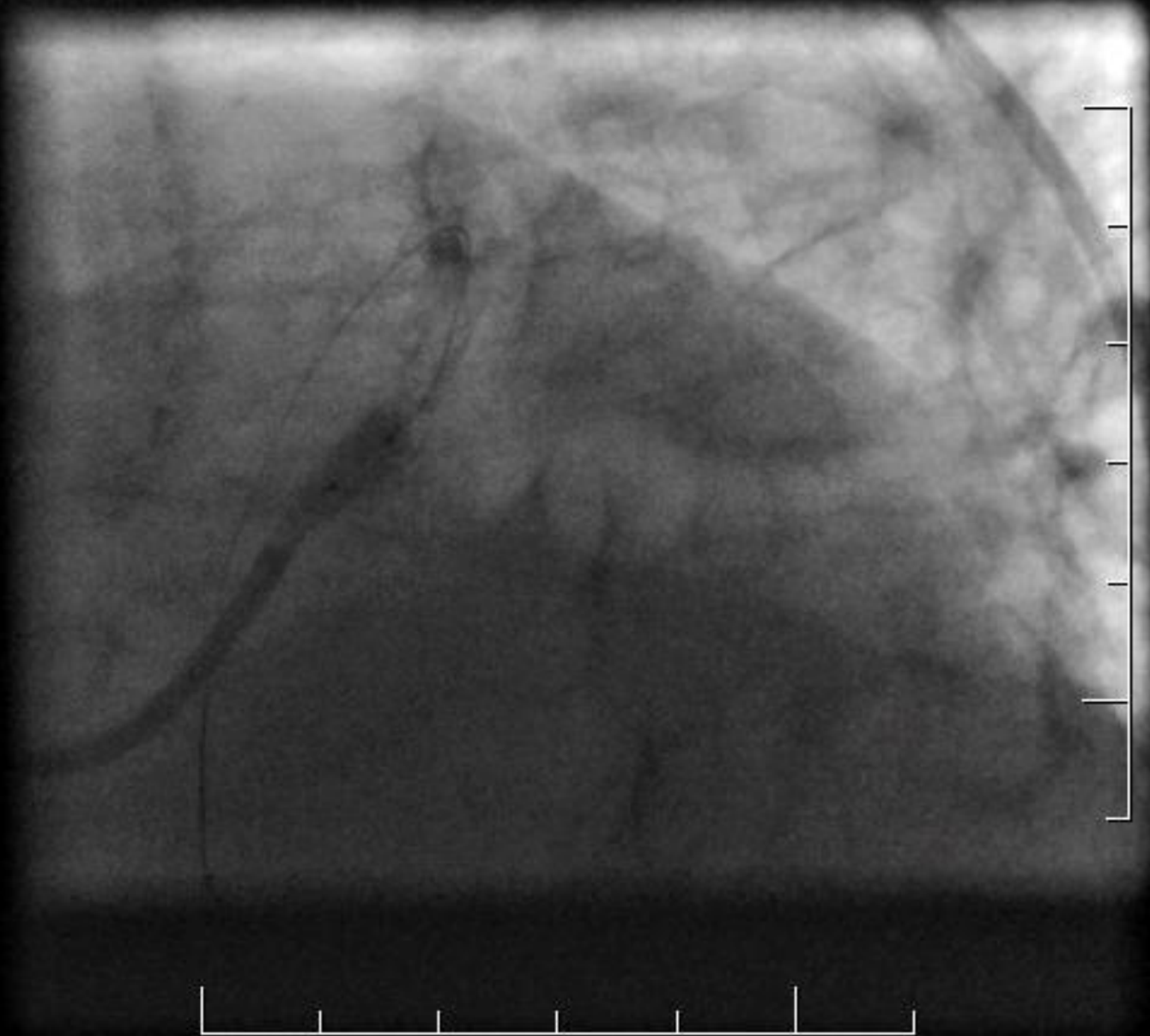
PCI: HK/RIA/RCX

- IVUS kontrola
 - Dobrá apozícia stentov



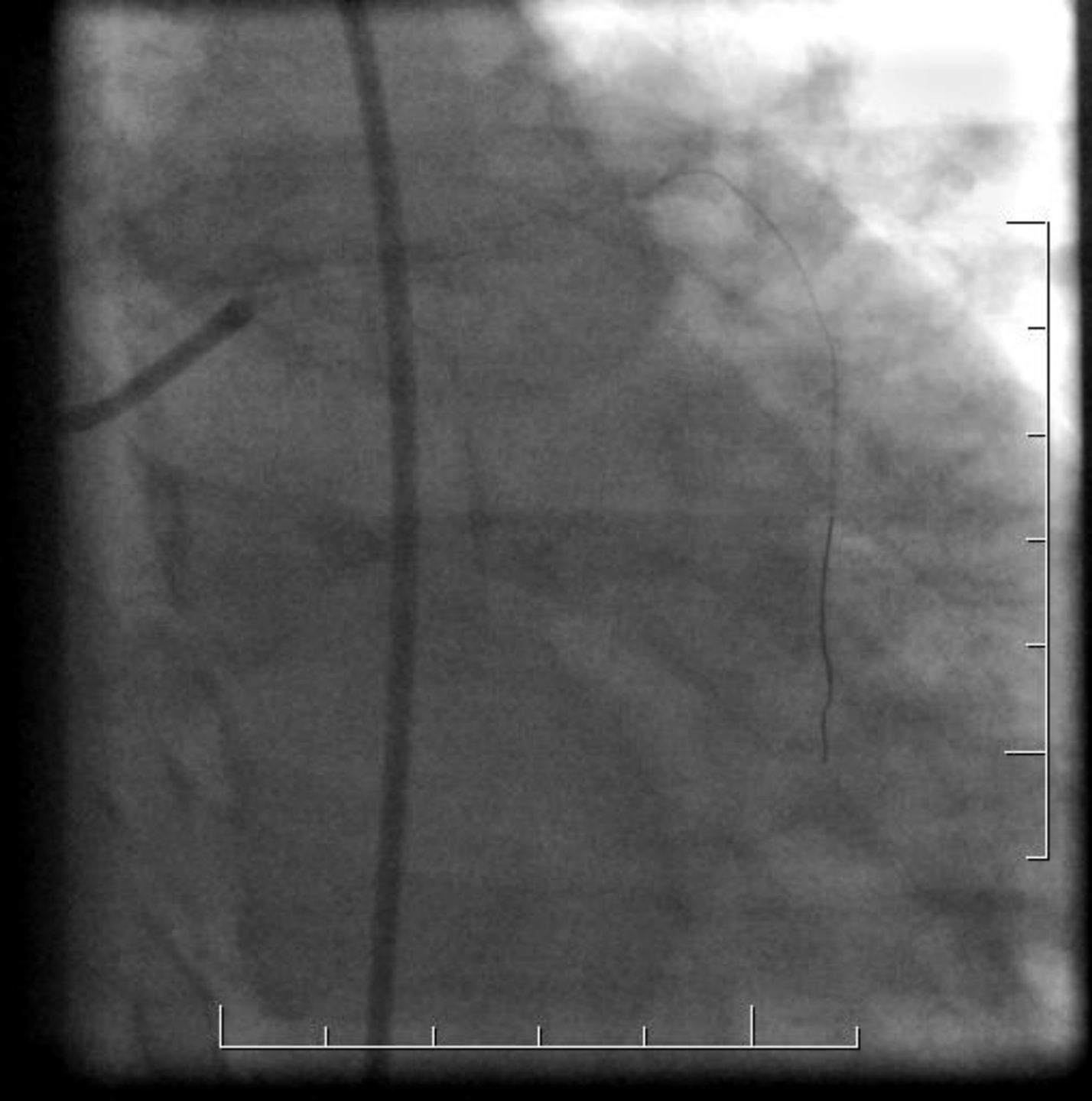
PCI: HK/RIA/RCX

- Final POT
 - NCB 4,5x8mm 24atm



PCI: HK/RIA/RCX

- na OCT 2,0mm² lézia na RCX

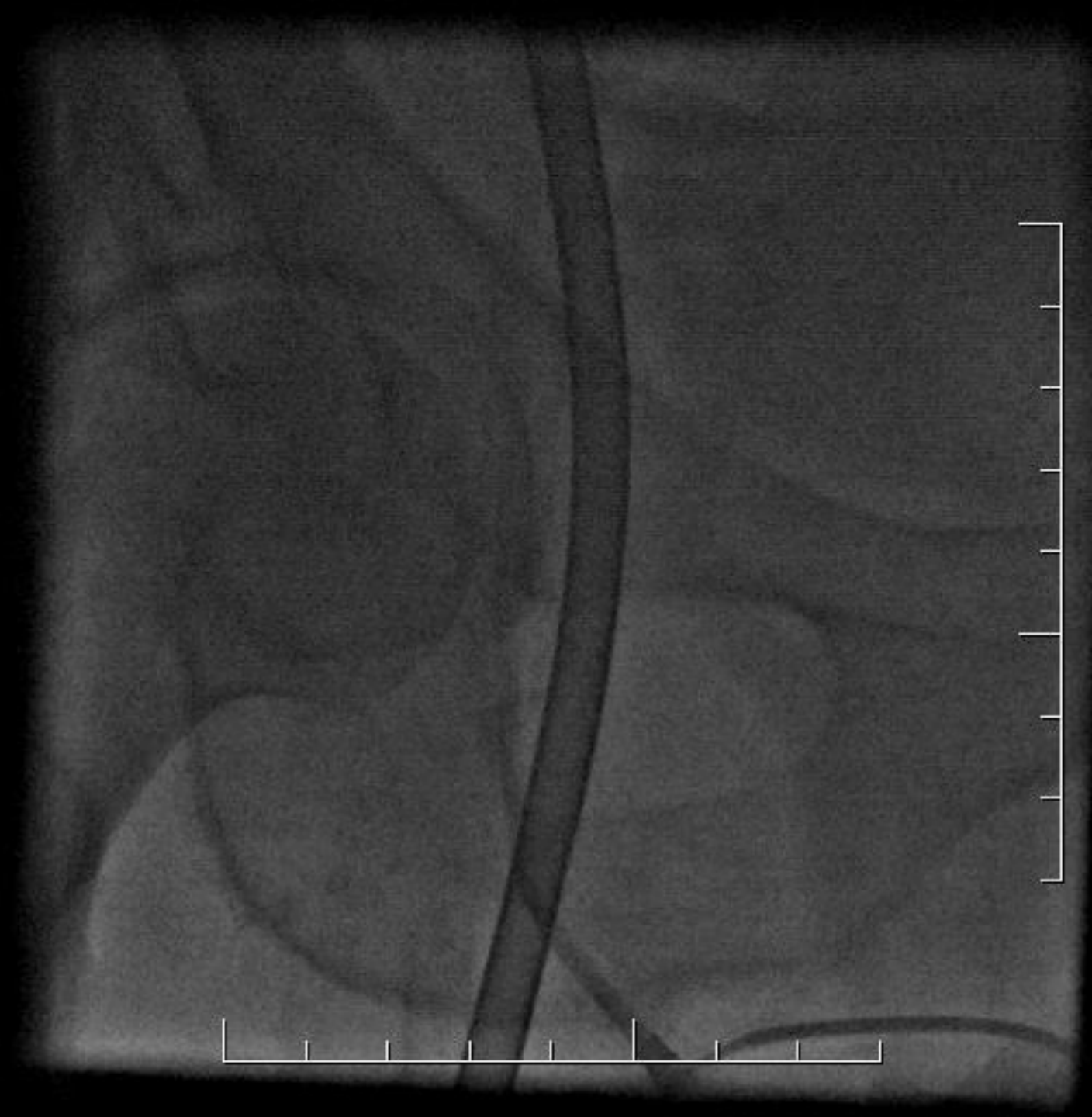


PCI: HK/RIA/RCX

- na OCT 2,0mm² lézia na RCX

DKCRUSH

24 dilatácií (balóny a stenty)



High risk PCI of unprotected Left Main



PulseCath
17F
2 l/min

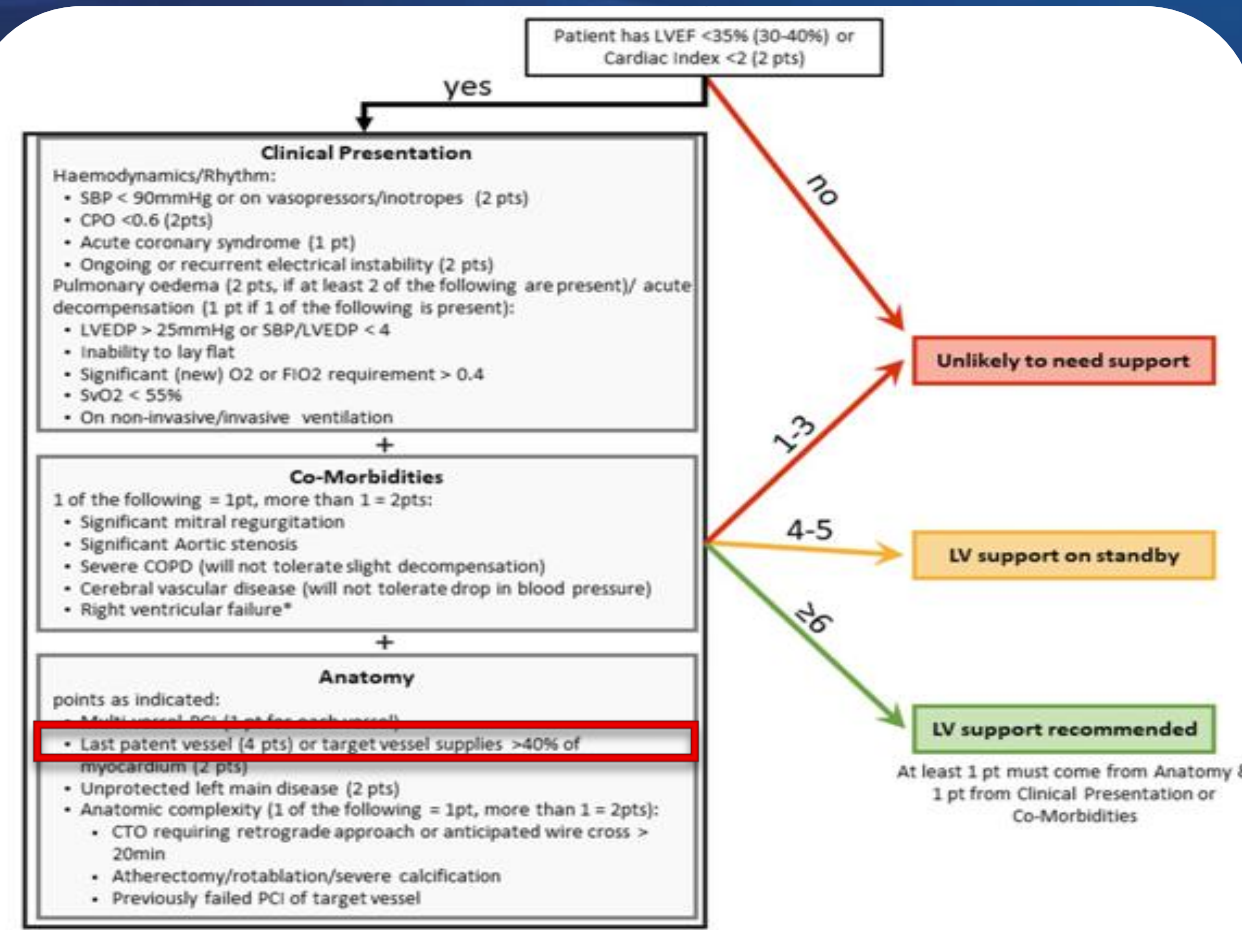
High risk PCI – algoritmus použitia mechanickej podpory

High-risk percutaneous coronary intervention. LV: left ventricular; eGFR: estimated glomerular filtration rate

CLINICAL
Severe LV dysfunction (ejection fraction < 35%)
Decompensated heart failure (elevated LV end-diastolic pressure)
Arrhythmias (rapid atrial fibrillation, ventricular tachycardia)
COMORBIDITIES
Severe valvular disease
Severe lung disease
Chronic kidney disease (eGFR < 30 mL/min/1.73 m ²)
Acute coronary syndrome
ANATOMICAL/PROCEDURAL
Unprotected left main coronary intervention or equivalent
Three-vessel disease with complex, calcified lesions (high Syntax score or Type C lesions)
Retrograde chronic total occlusion

PCI HK

- EFL'K <35%
- CTO RCA



Aggarwal B, Aman W, Jeroudi O, Kleiman NS. Mechanical Circulatory Support in High-Risk Percutaneous Coronary Intervention. Methodist Deakey Cardiovasc J. 2018 Jan-Mar;14(1):23-31. doi: 10.14797/mdcj-14-1-23. PMID: 29623169; PMCID: PMC5880556.

Alexander Geppert, Kambis Mashayekhi, Kurt Huber, The use of mechanical circulatory support in elective high-risk percutaneous coronary interventions: a literature-based review, European Heart Journal Open, Volume 4, Issue 2, March 2024, oeae007, <https://doi.org/10.1093/ehjopen/oeae007>

