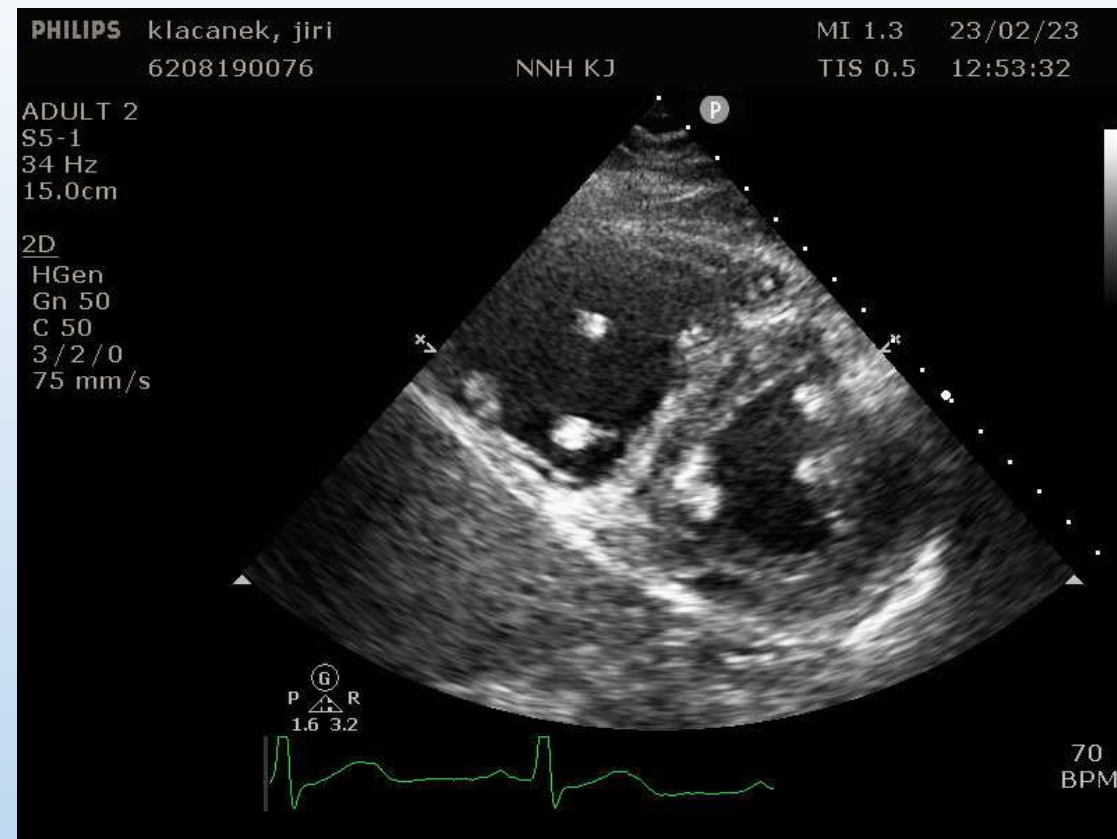
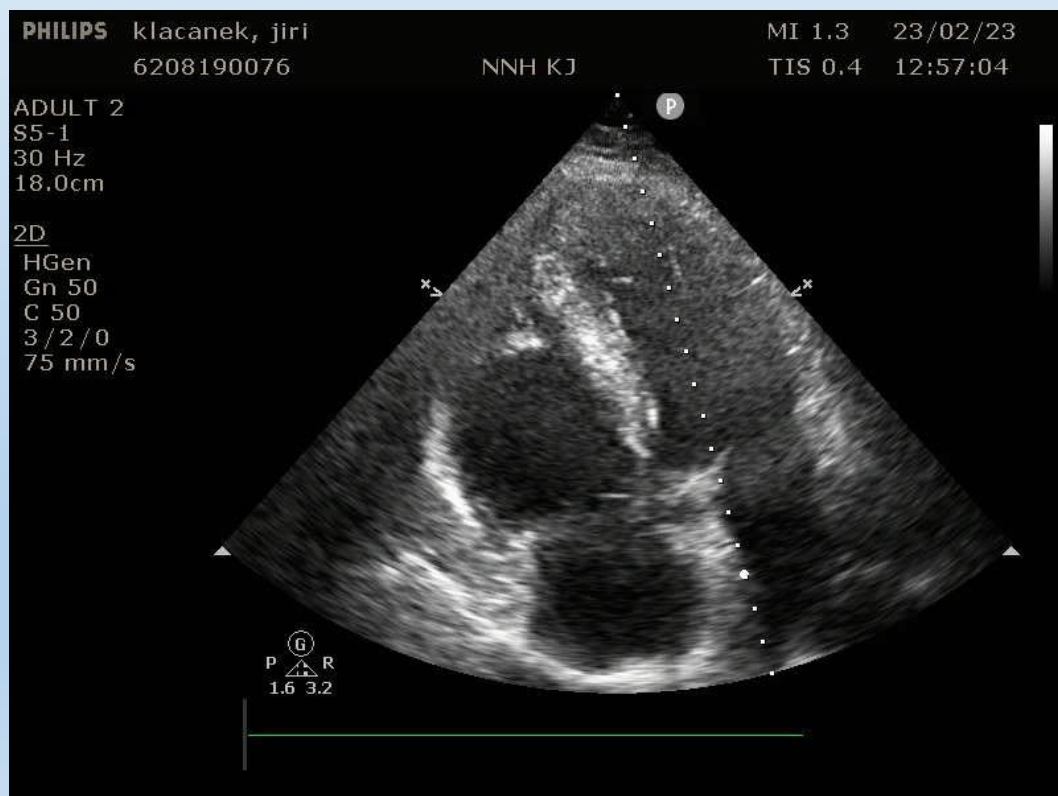


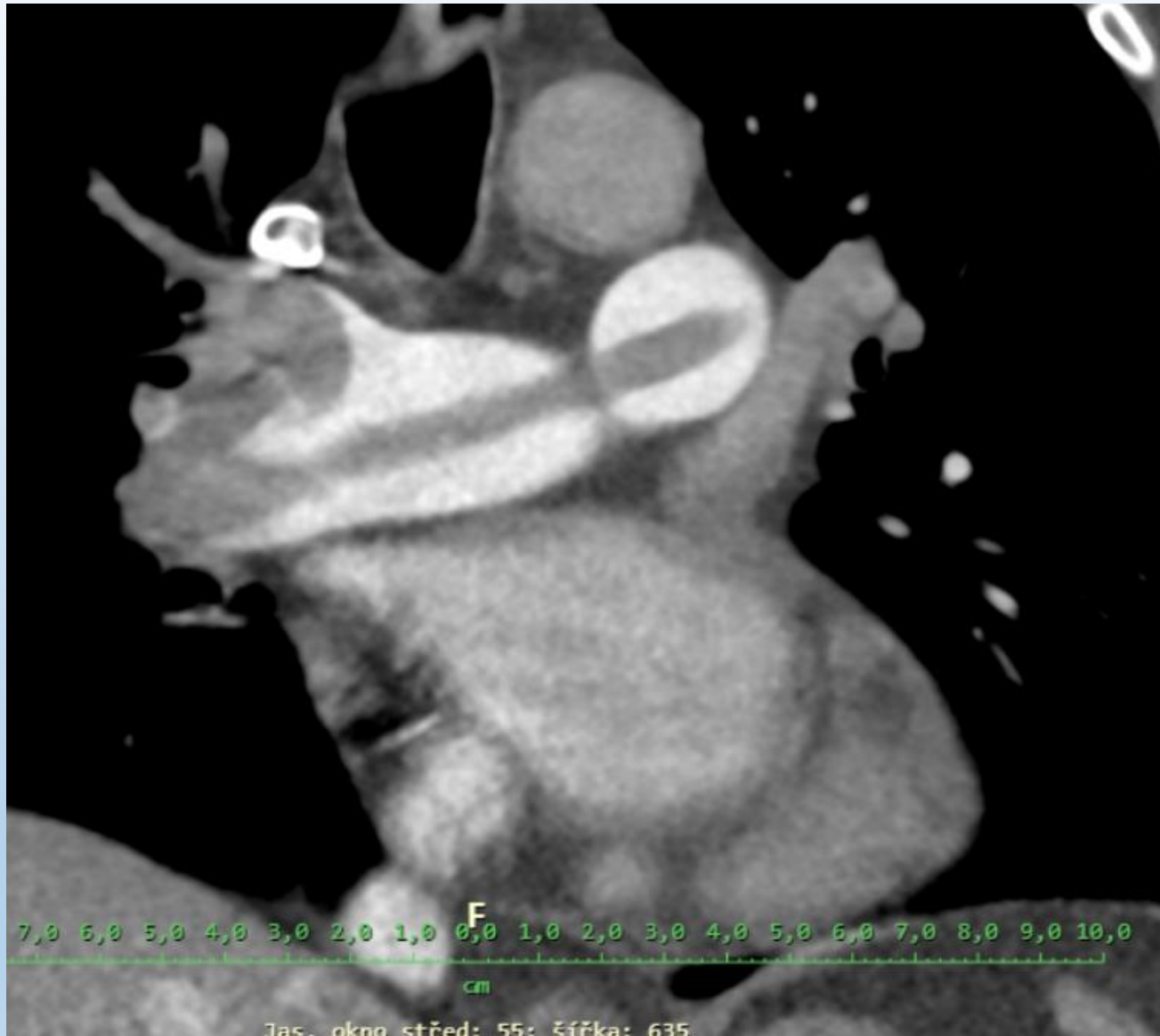
Echoqíz



Progredující hypotenze, desaturace

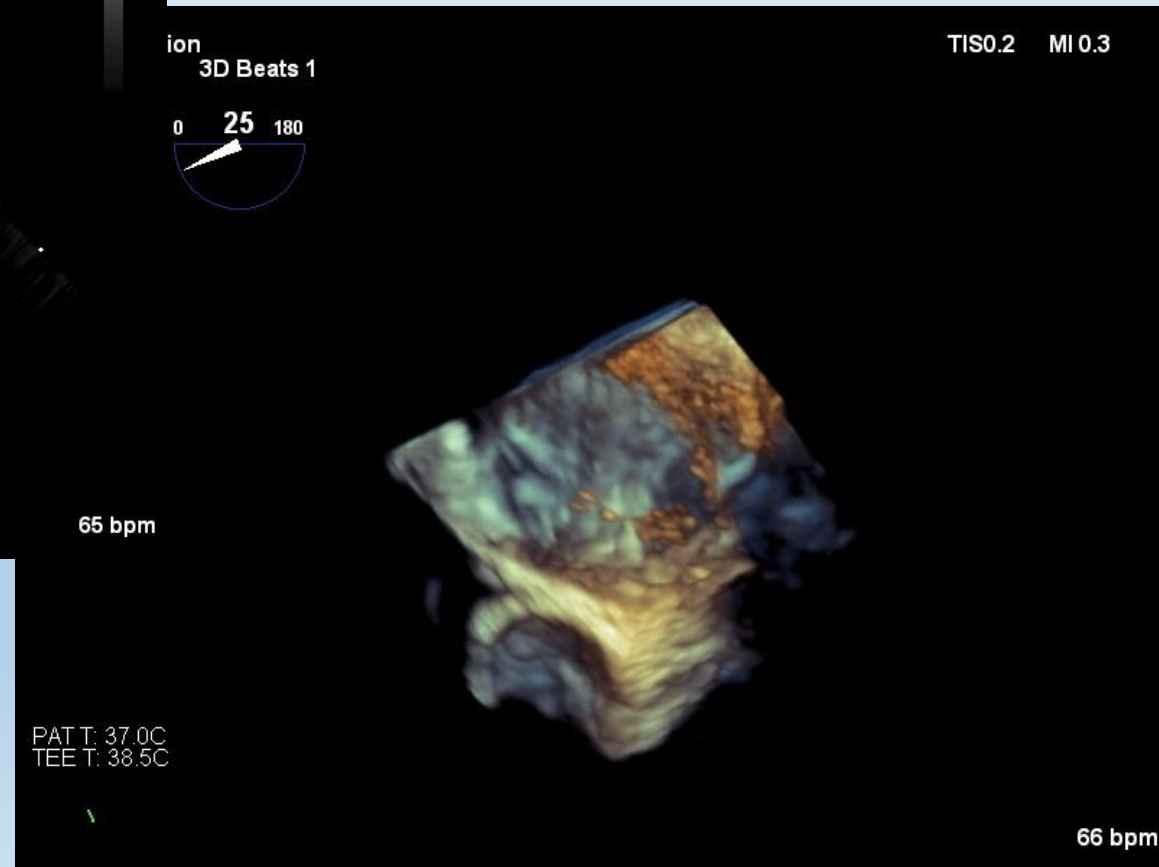
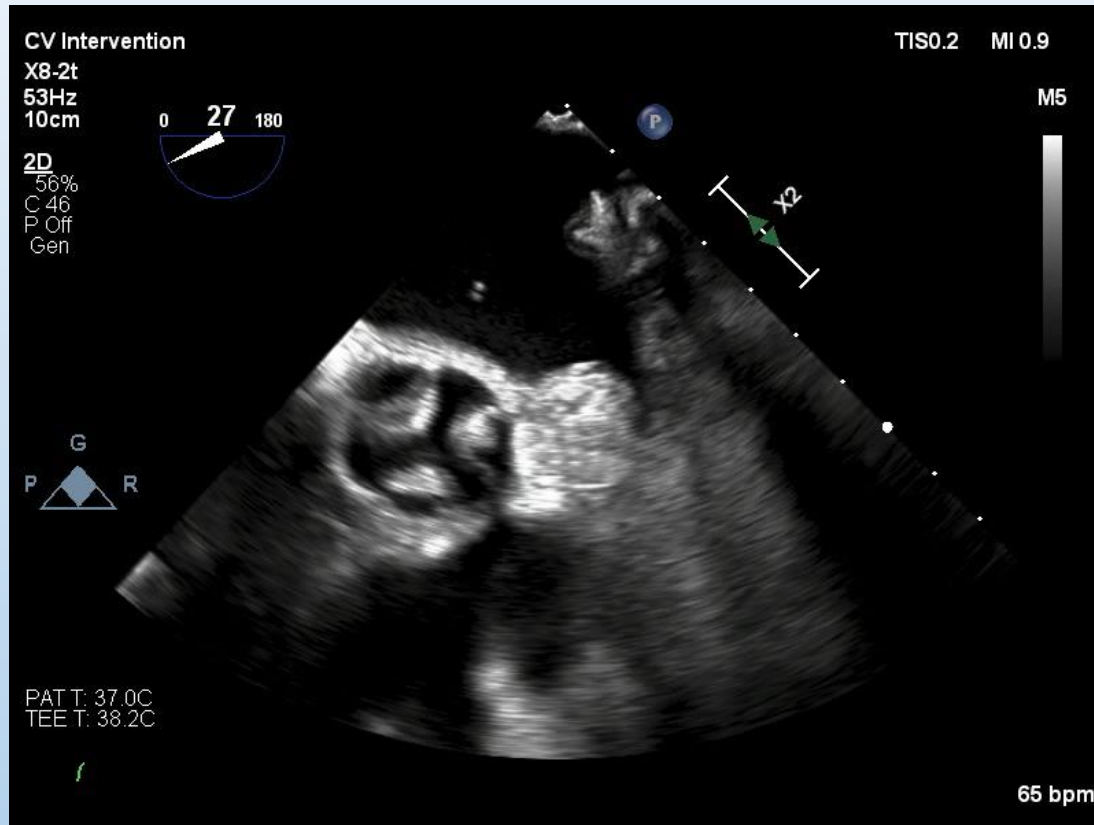


1. CTEPH
2. Fibrotizující plicní proces
3. Akutní plicní embolie
4. Zkratová vada na úrovni síní

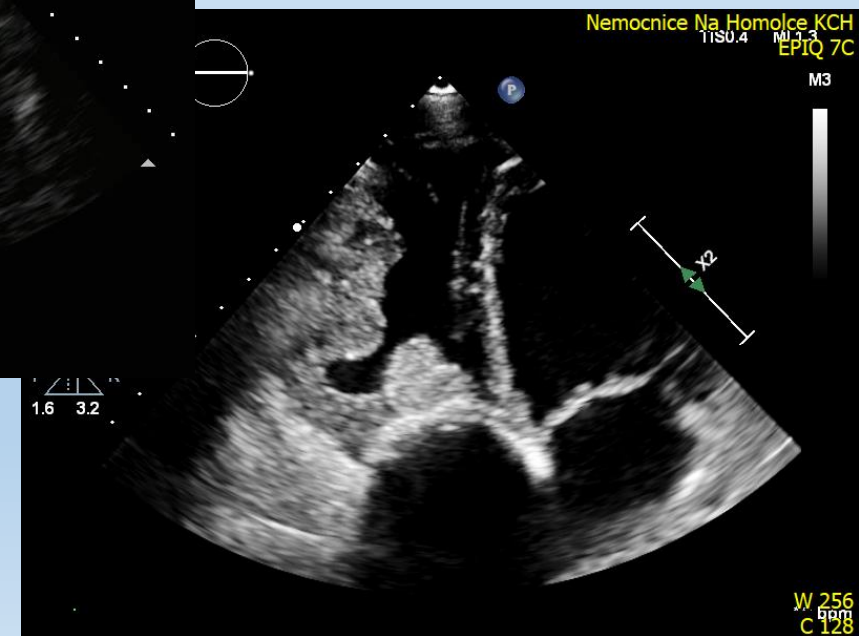
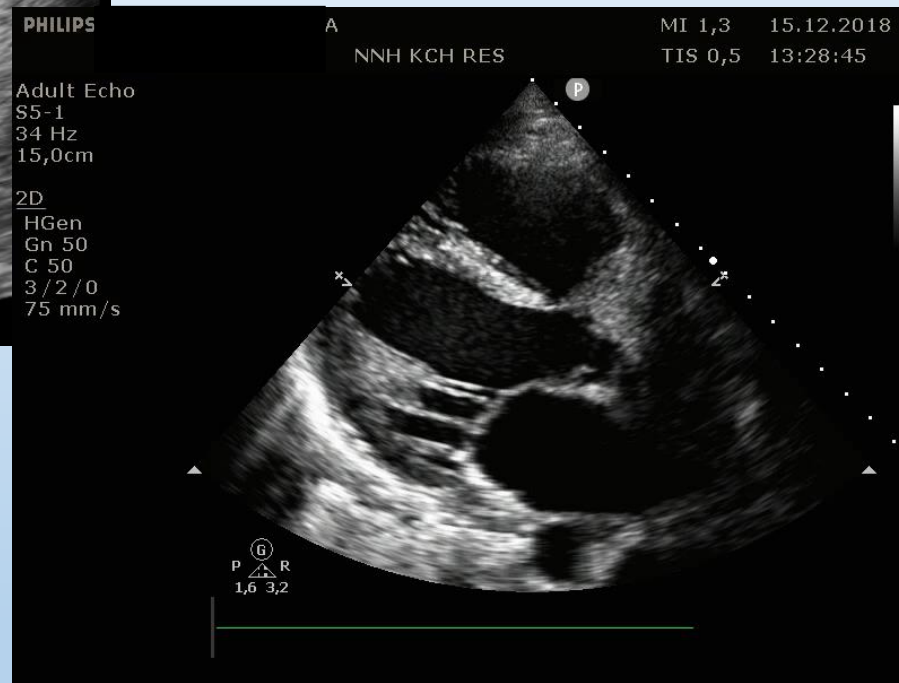
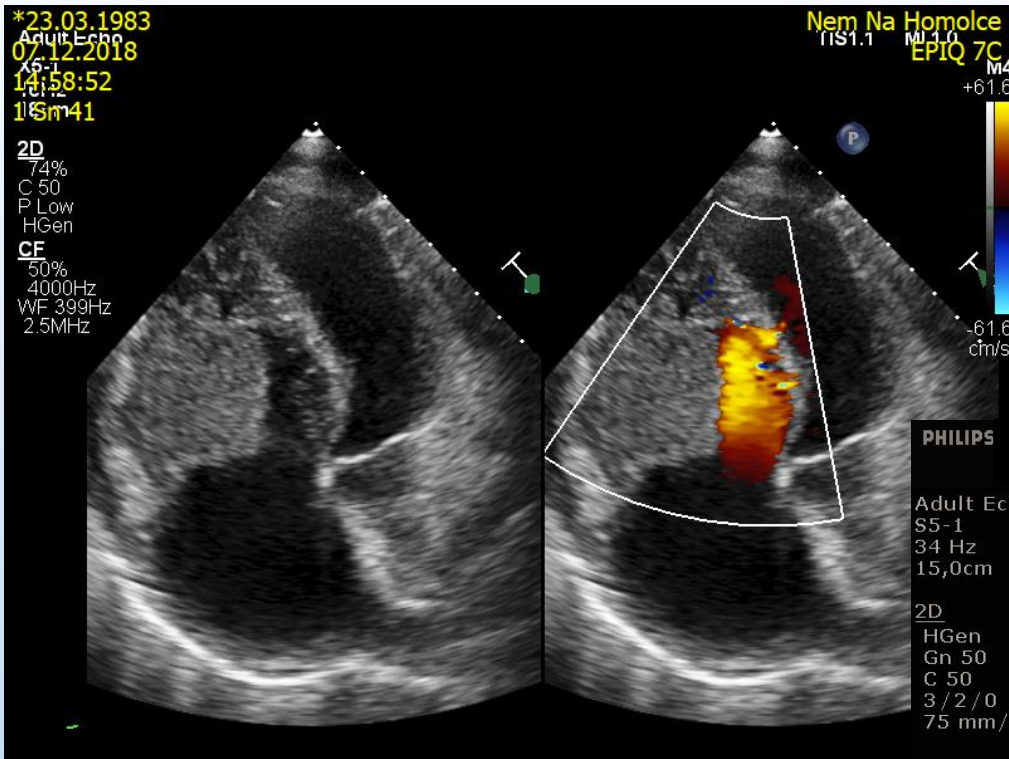


Útvar LS

1. Papilární fibroelastom
2. Myxom
3. Čerstvý trombus
4. Fibrozní reziduum trombu



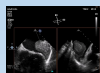
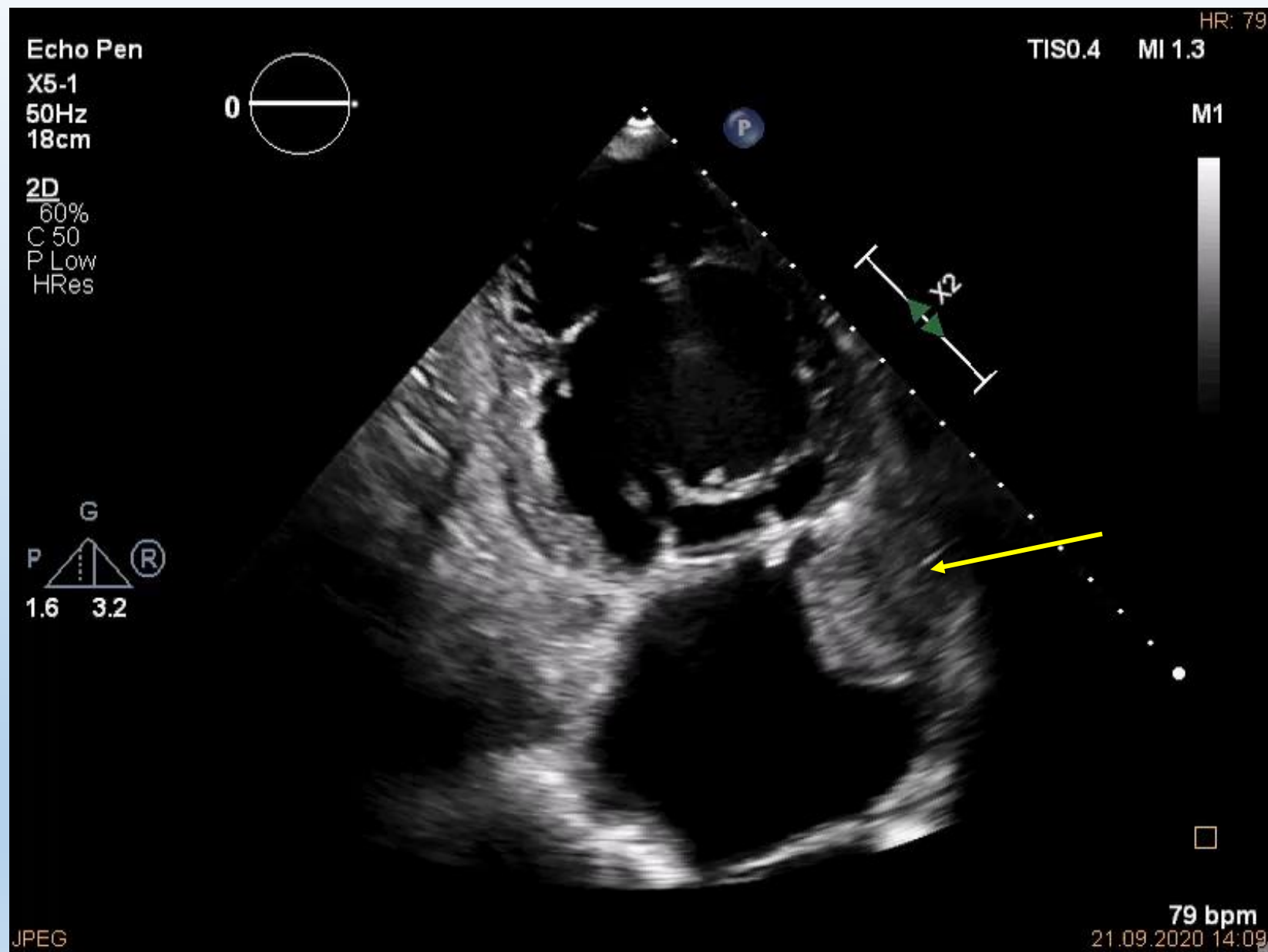
Útvar PK



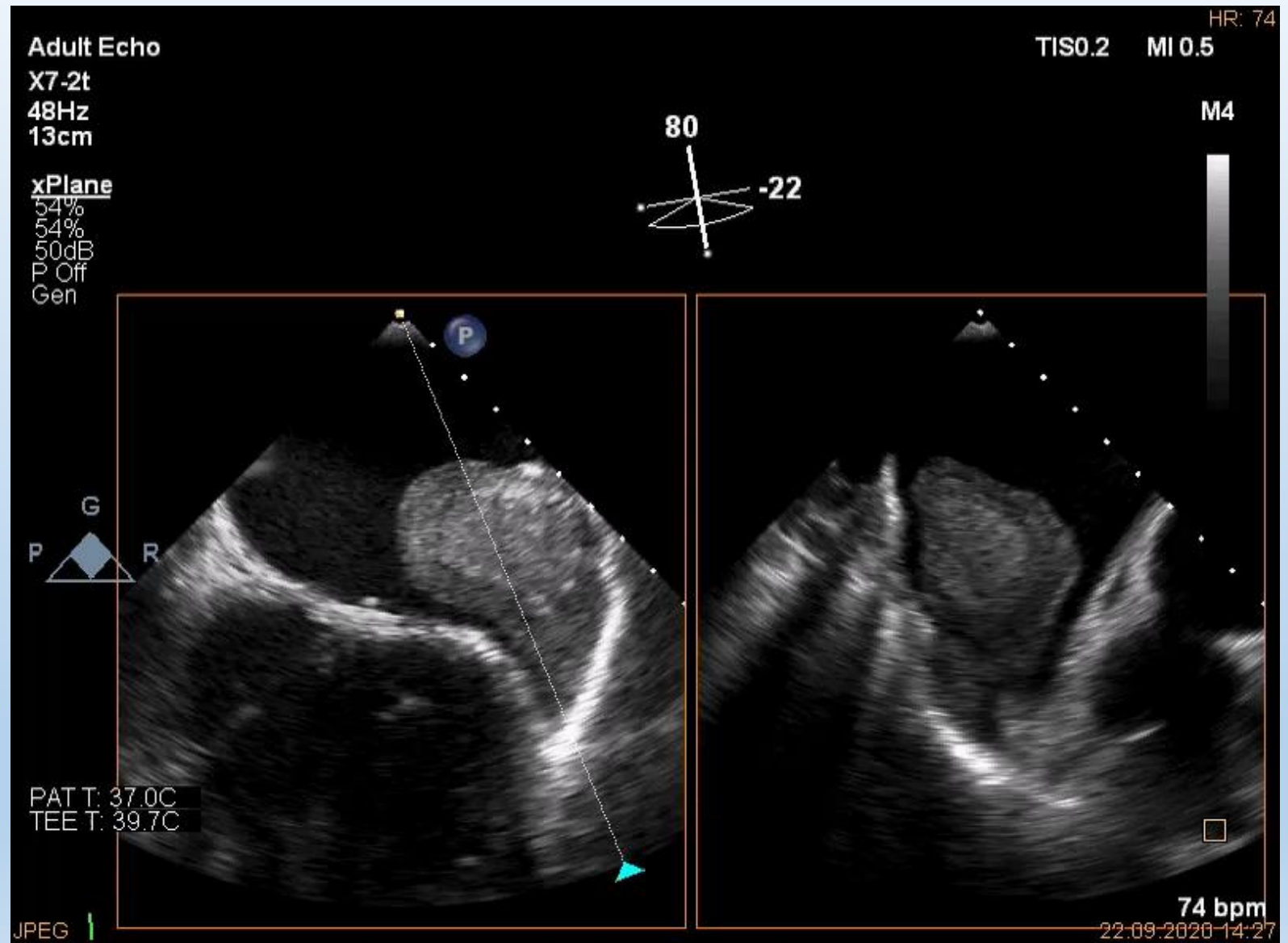
1. Trombus
2. Vřetenobuněčný sarkom
3. Lipom
4. Lymfom

Útvar LS

1. Kazeózní kalcifikace mitrálního anulu
2. Myxom
3. Trombus LAA
4. Angiosarkom



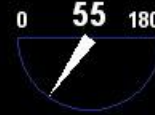Útvar LS



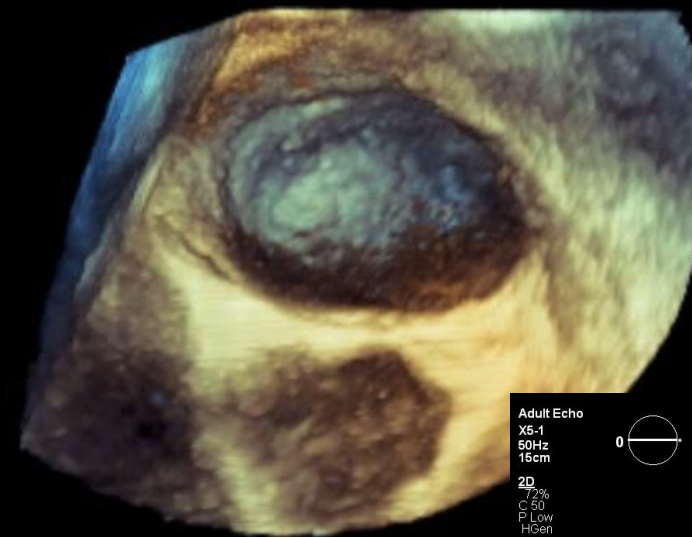
Útvar mitrální chlopně

Adult Echo
X8-2t
11Hz
6.1cm
3D Zoom
2D / 3D
% 68 / 45
C 47 / 30
Gen
XRES ON

3D Beats 1



TISO.2 MI 0.3



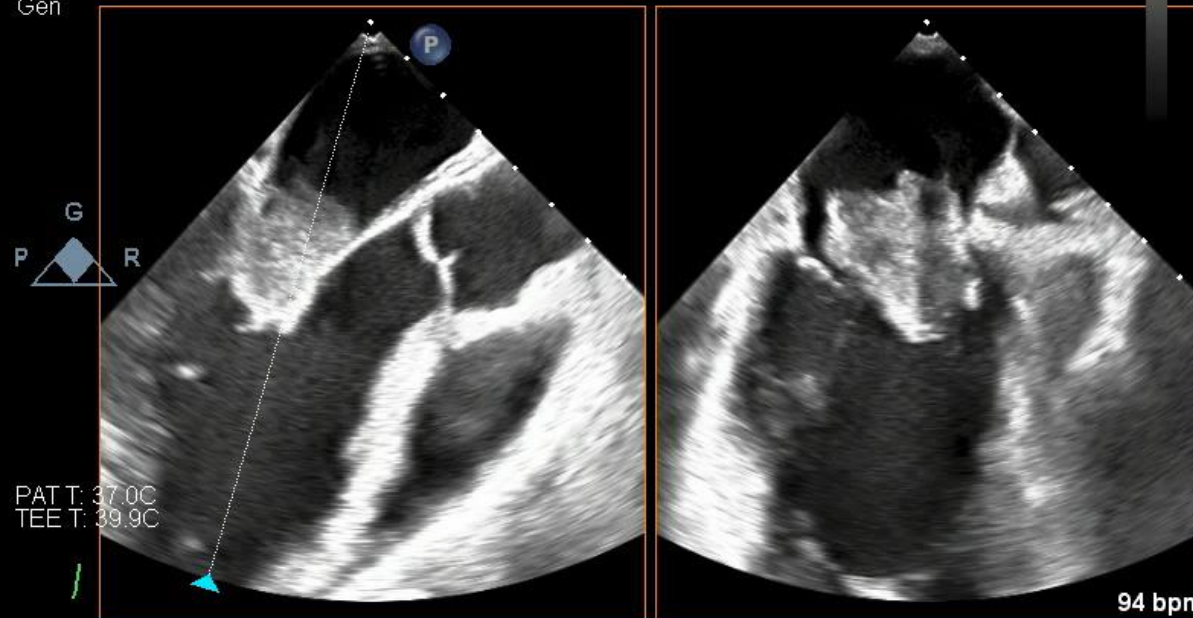
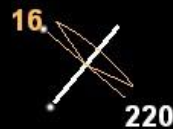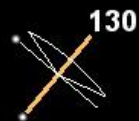Adult Echo
X8-2t
27Hz
11cm

3D Zoom Preview

68%
68%
50dB
P Off
Gen

TISO.2 MI 0.5

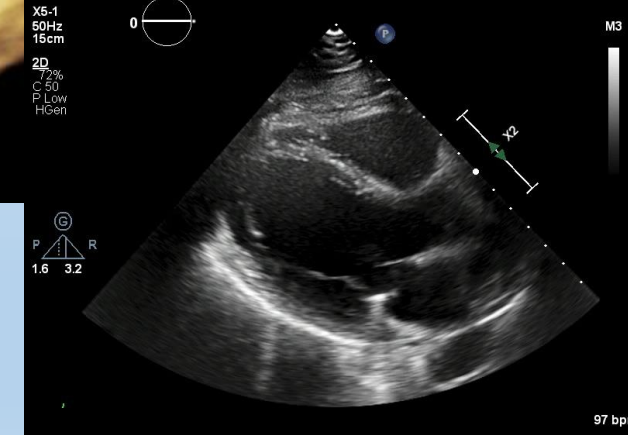
M4



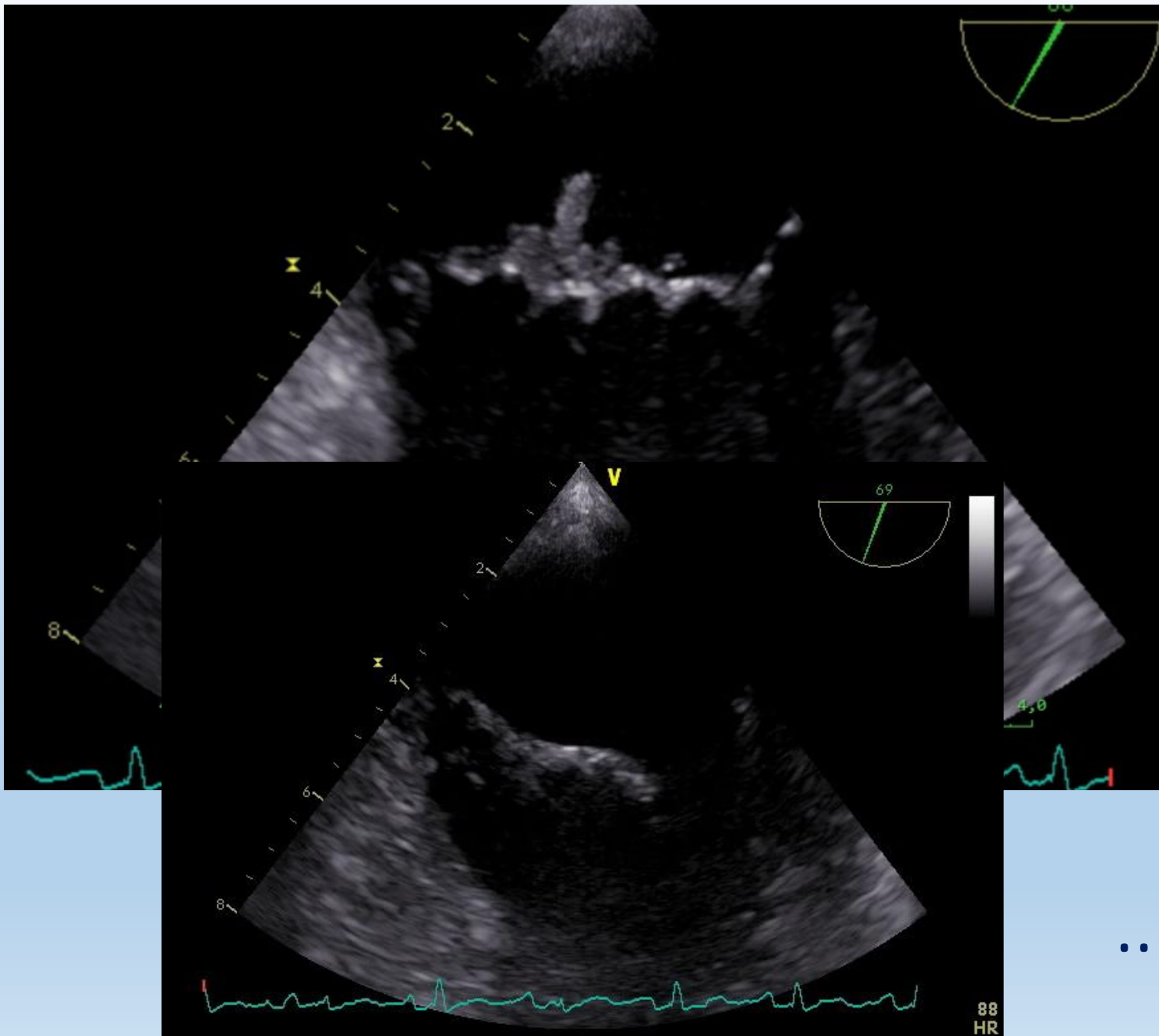
Adult Echo
X5-1
50Hz
15cm
2D
72%
C 50
P Low
HGen

TISO.4 MI 1.3

M3



1. Fibrosarkom
2. Trombus
3. Papilární fibroelastom
4. Myxom



1. Známý pozdrav z poslanecké sněmovny Miroslavu Kalouskovi

2. Endokarditis mitrální chlopně

...děkuji za pozornost