

5. listopadu 2022 Břevnovský klášter

**PRAHA**

PRAGUE SYMPOSIUM  
ON CONGENITAL  
HEART DISEASE 2022



# Children's Heart Centre: Achievements and Challenges

*J. Janoušek*

Children's Heart Centre

2<sup>nd</sup> Faculty of Medicine, Charles University  
in Prague and Motol University Hospital



# Open heart surgery for congenital heart disease at the St. Ann's Hospital in Brno, Czech Republic, 1966

Uryšilání

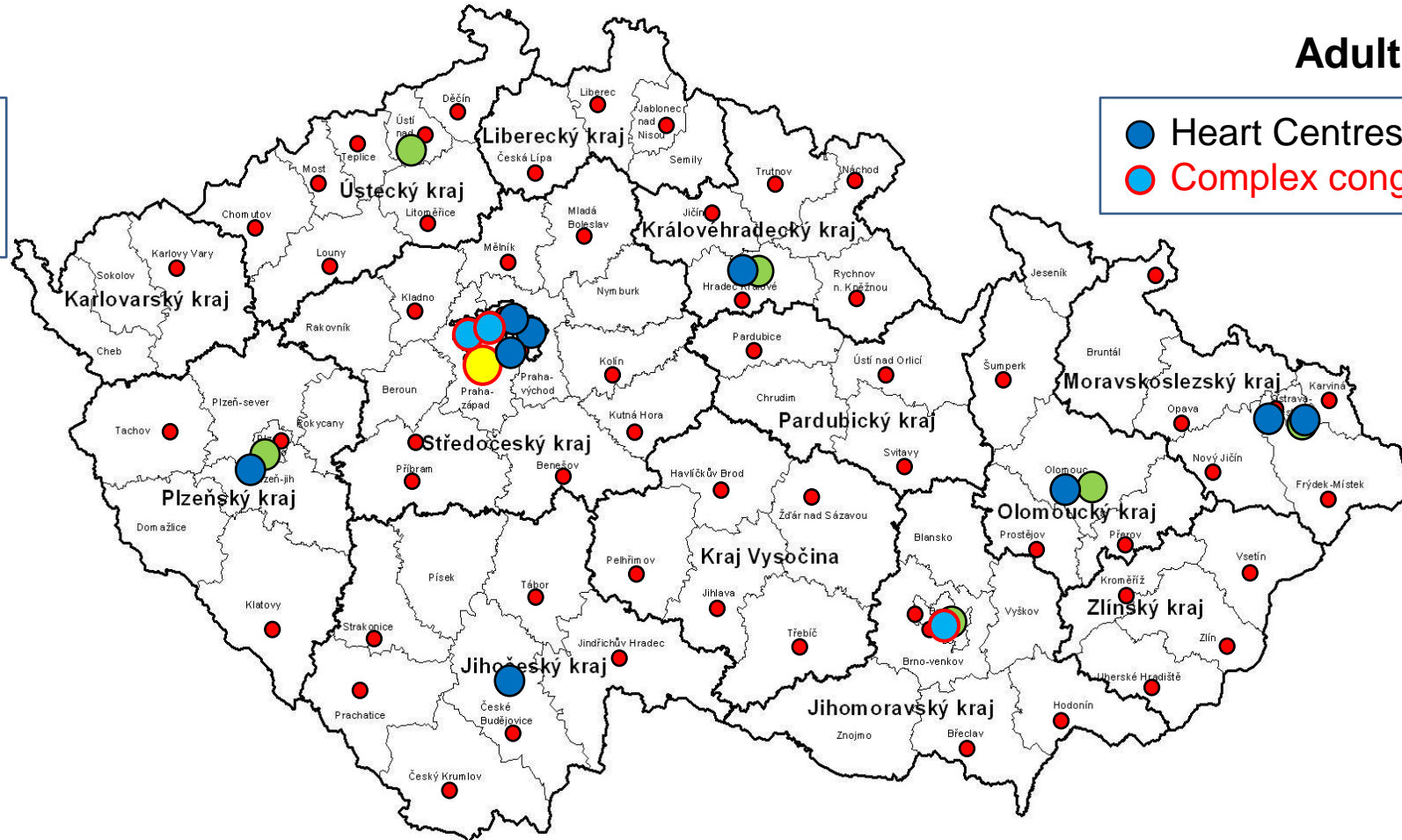
# Organization of congenital heart disease treatment in the Czech Republic

## Children

## Adults

- Outpatients
- Bed units
- Children's Heart Centre

- Heart Centres
- Complex congenital heart disease

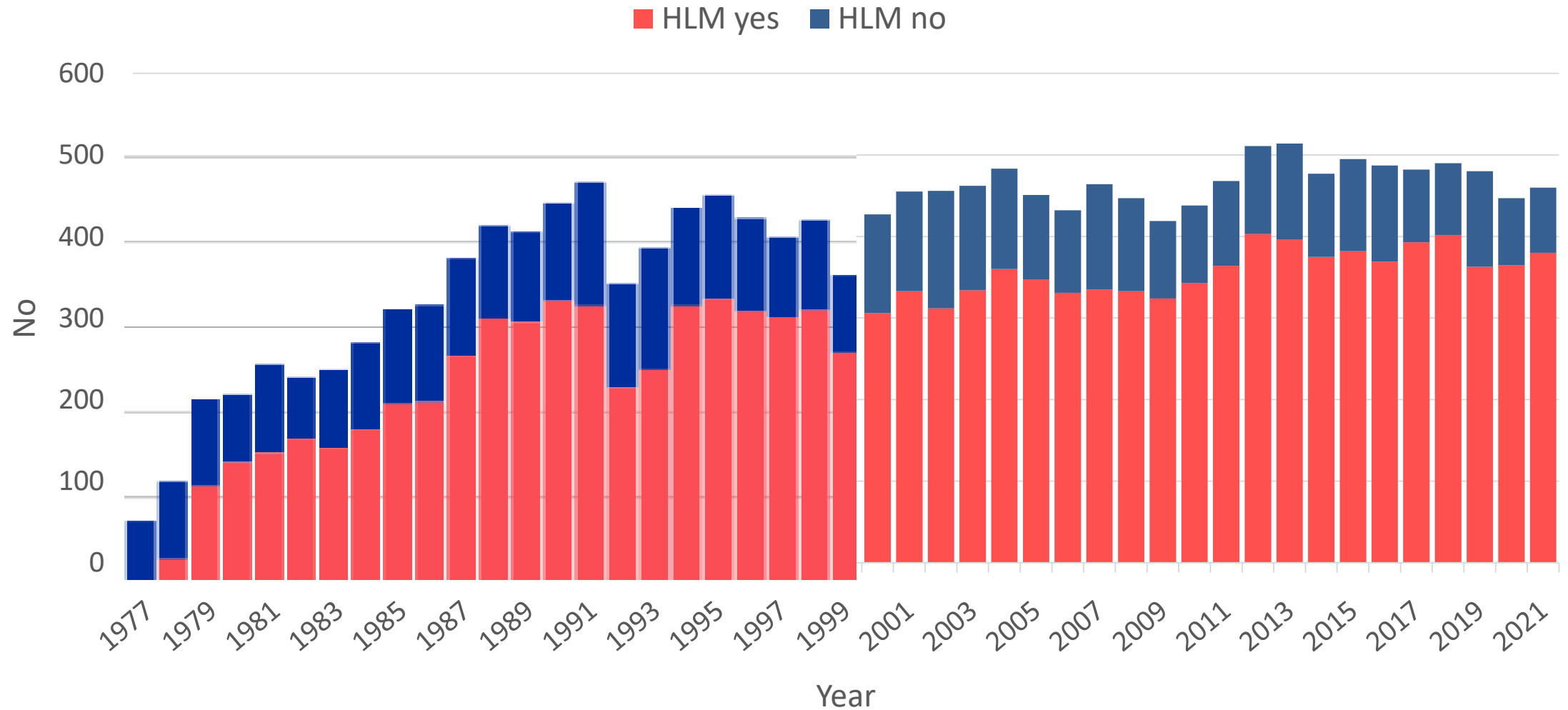




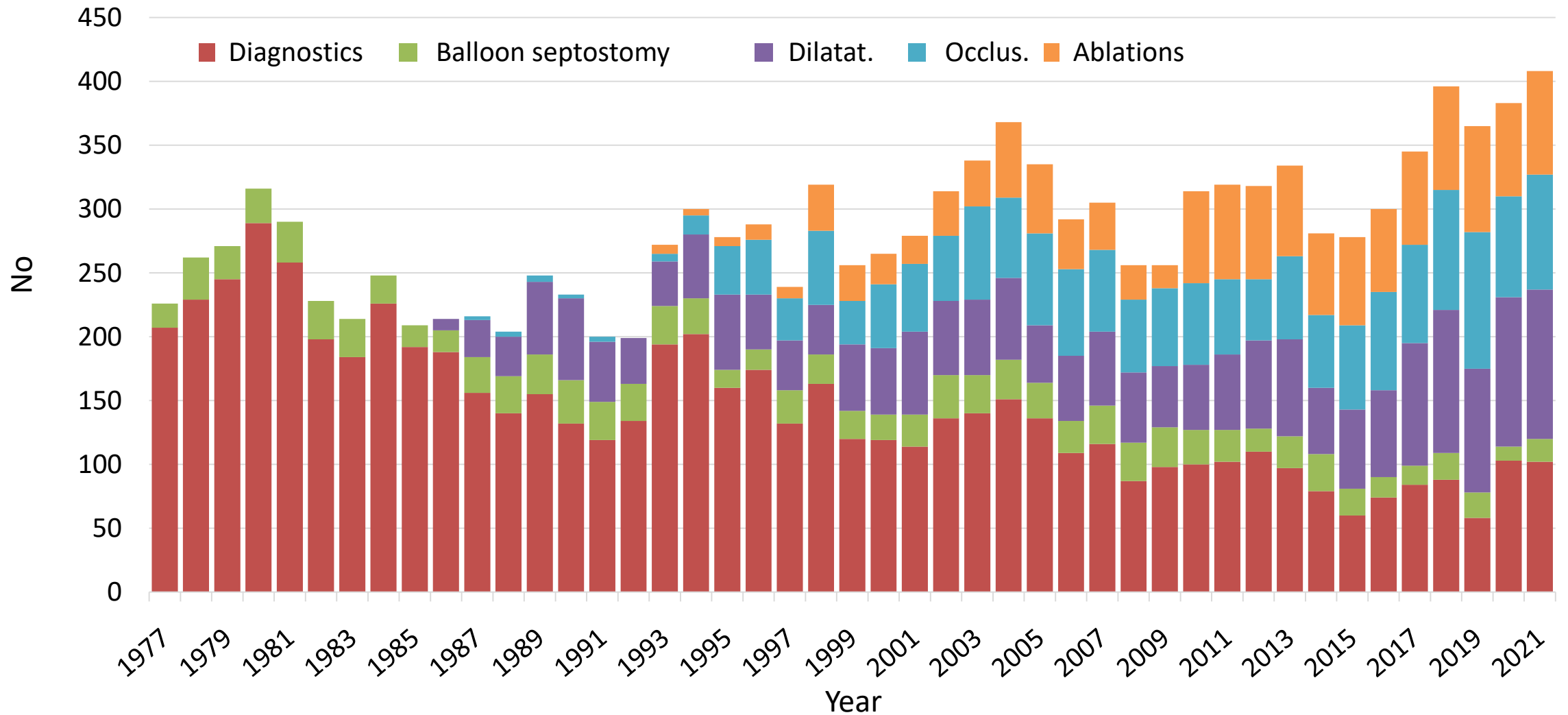
# Founders of organized centralized care



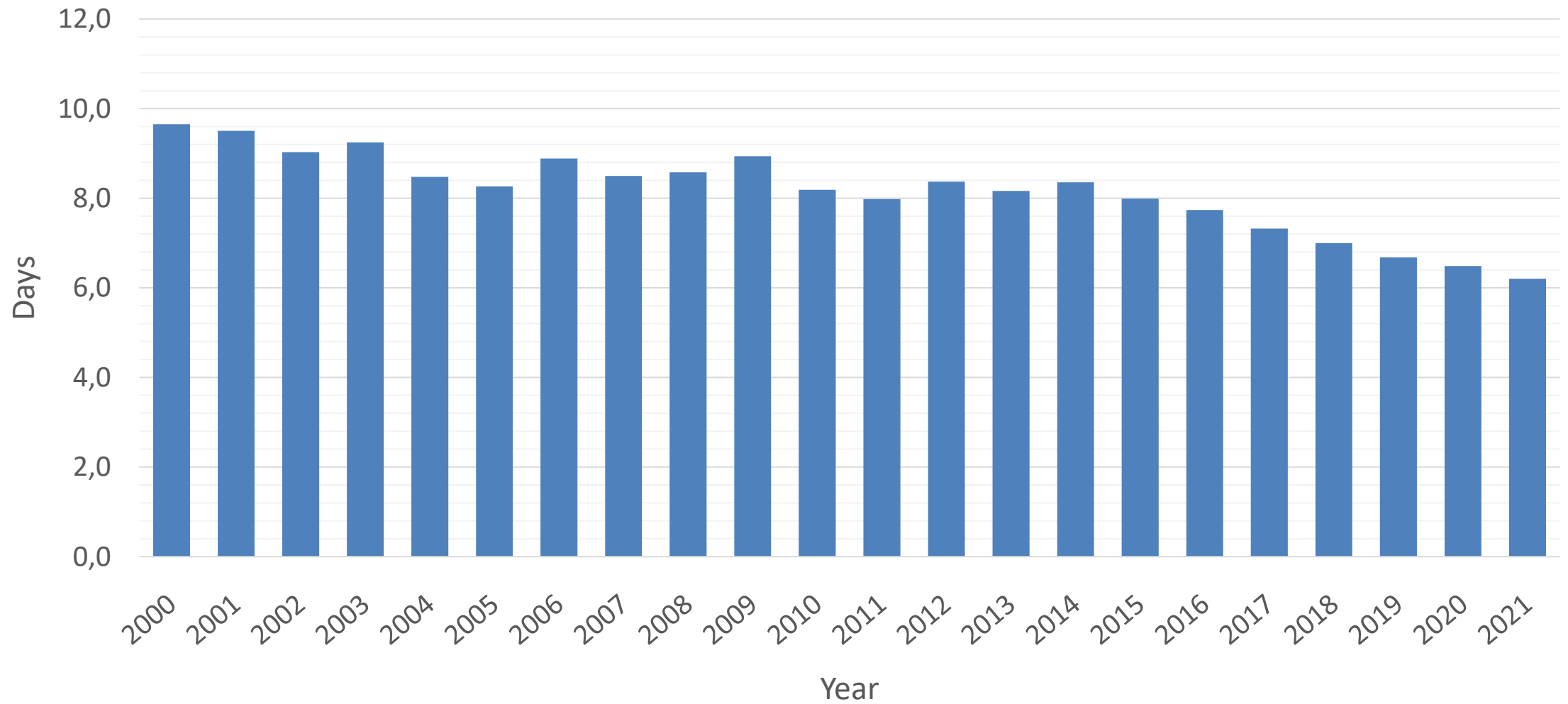
# Number and type of surgical procedures



# Number and type of catheter procedures

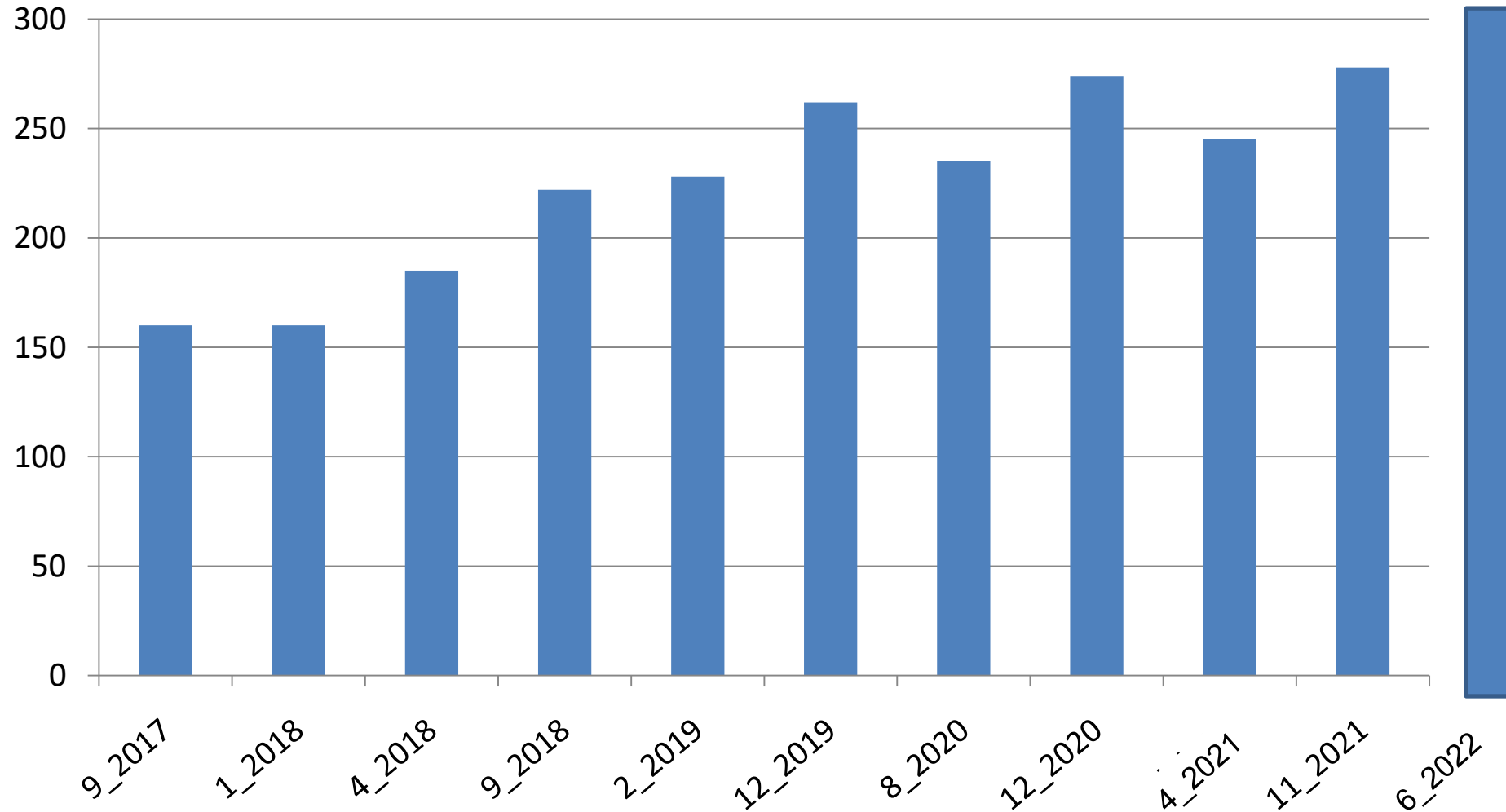


# Mean hospital stay



# But is it enough?

No of patients on surgical waiting list





# Reasons for higher demand

High survival  
in complex heart disease



*Re-do procedures*

New treatment programs



*End-stage heart failure*  
*Prenatal interventions (Linz)*

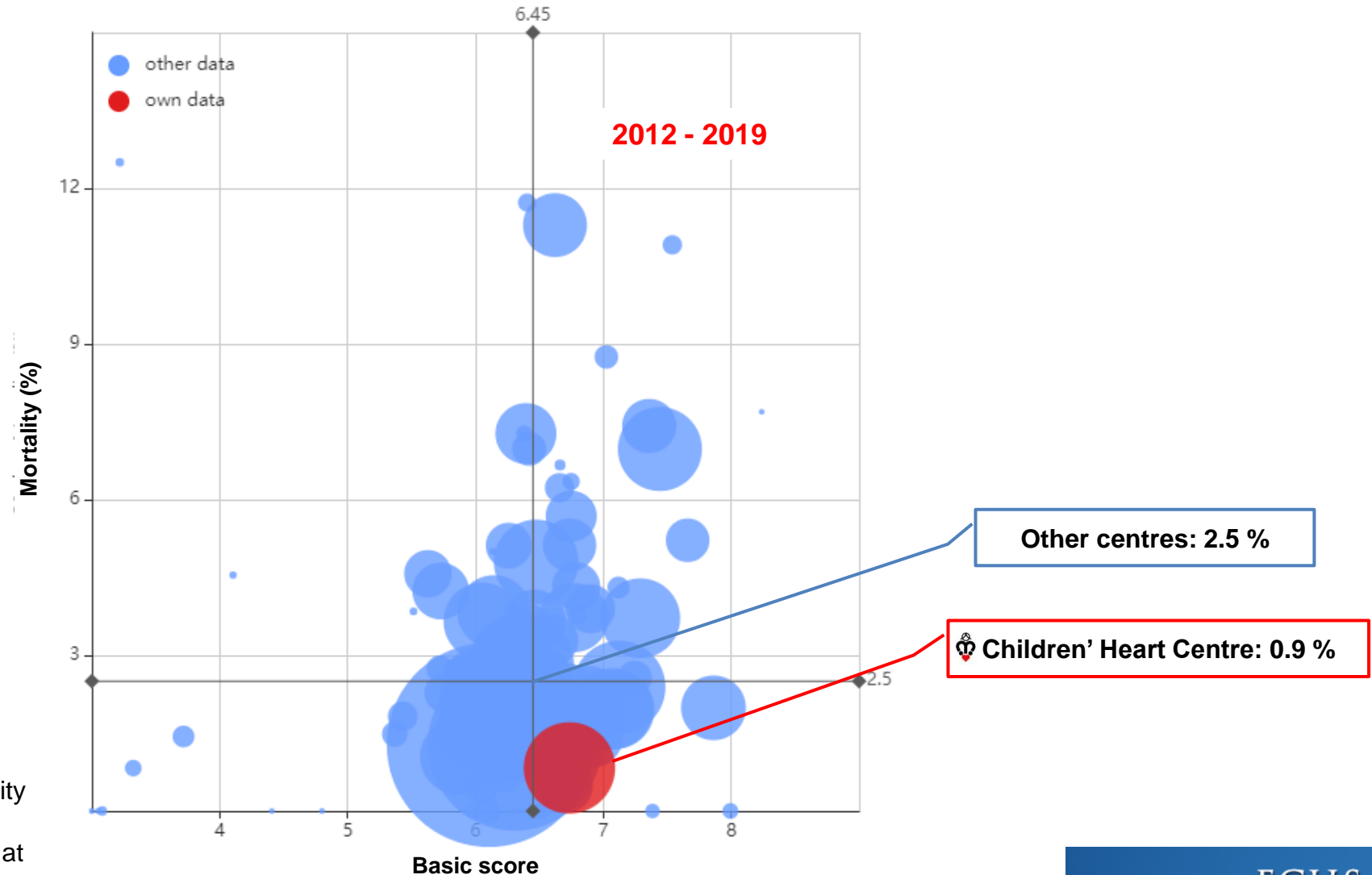
Ukraine war



*Refugees*

# 30-day surgical mortality and procedure complexity

ECHSA Congenital Database, Quality of Care Chart



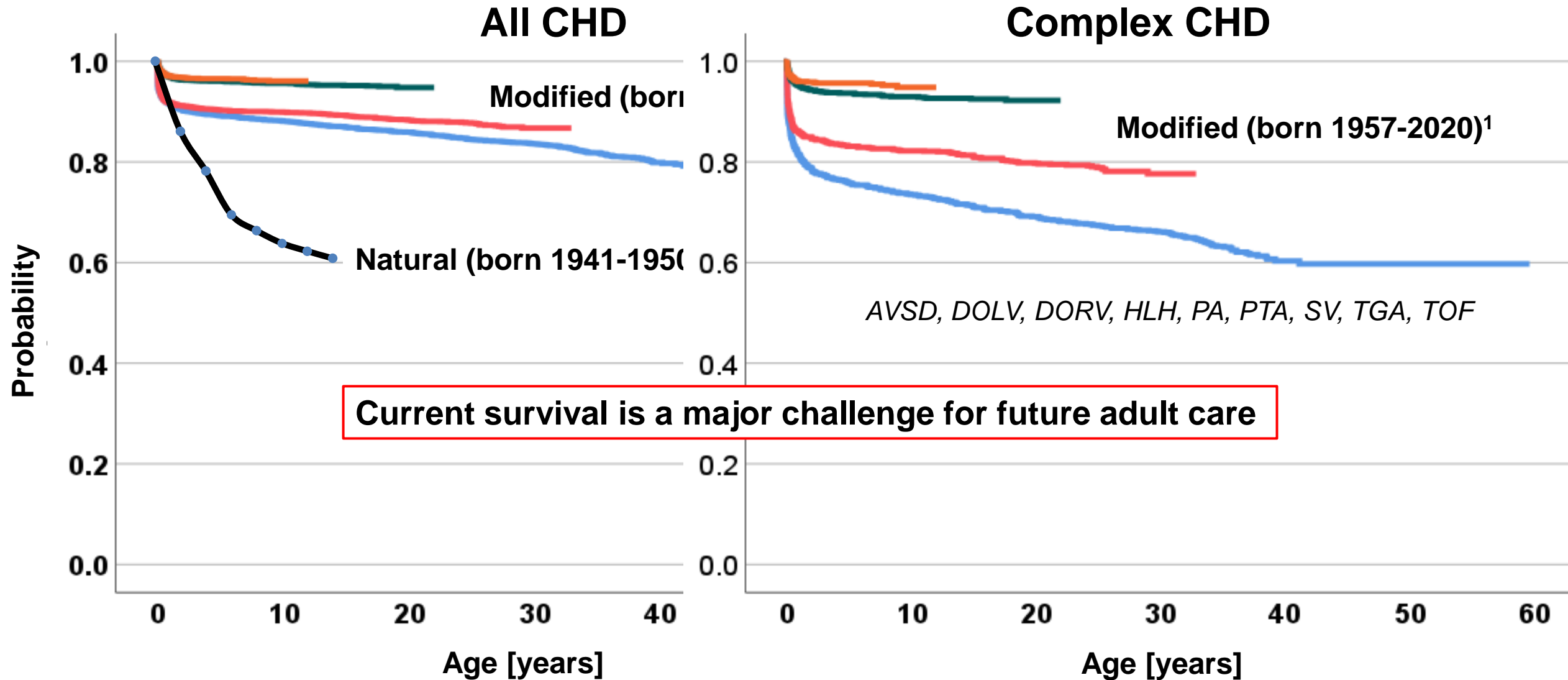
**Basic Score:** Higher No means higher complexity of surgical procedure.

**Bubble size:** Reflects No of surgical procedure at given centre.

**Coordinates:** Mean of database data.

Courtesy: R. Poruban, R. Gebauer

# Natural and modified survival in congenital heart disease



# Big data in medicine

Proprietary patient management system  
*From Old (1991)*  
*to New (2019)*

Patients: 65212  
Operations: 22674  
Catheterizations: 12669  
Outpatient visits: 129313  
Echocardiography: 141479



Informační systém  
Dětského kardiocentra

- Pacient
- Demografické údaje
- Ambulantní vyšetření
- Hospitalizace, operace a JIP
- Echokardiografie
- EKG a Holter
- Kardiostimulátor / ICD
- Katetrizace
- Diagnózy
- Výkony
- Seznamy
- Spádová kardiologové
- Administrace
- Lékaři
- Uživatelé
- Skupiny
- Exporty
- Žurnál
- Systémové informace
- Nápověda
- Hotline

Pacient > Echokardiografie

Zápis echokardiografie

Datum	Diagnózy		
	Hlavní	Vedlejší	
23.11.2021 9:45	HLH	SV/F, AI, COA	✘
11.05.2021 10:10	HLH	SV/F, AI, COA	✘
24.11.2020 9:55	HLH	SV/F, AI, COA	✘
26.03.2020 9:10	HLH	SV/F, AI, COA	✘
10.09.2019 0:00	HLH	SV/F, AI, COA	✘
04.02.2019 0:00	HLH	SV/F, AI, COA	✘
29.01.2019 0:00	HLH	SV/F, AI, COA	✘
06.11.2018 0:00	HLH	SV/F, AI, COA	✘
04.04.2018 0:00	HLH	SV/F, AI, COA, TI	✘
20.02.2018 0:00	HLH	SV/F, AI, COA, TI	✘
05.05.2017 0:00	HLH	SV/F, AI, COA, TI	✘
21.02.2017 0:00	HLH	SV/F, AI, COA, TI	✘
05.12.2016 0:00	HLH	SV/F, AI, COA, TI	✘
26.08.2016 0:00	HLH	SV/F, AI, COA, TI	✘
19.02.2016 0:00	HLH	SV/F, AI, COA, TI	✘
12.05.2015 0:00	HLH	SV/F, AI, COA, TI	✘
31.03.2015 0:00	HLH	SV/F, AI, COA, TI	✘
16.03.2015 0:00	HLH	SV/F, AI, COA, TI	✘
04.02.2015 0:00	HLH	SV/F, AI, COA, TI	✘
26.08.2014 0:00	HLH	SV/F, AI, COA, TI	✘

První Předchozí 1 2 3 4 Další Poslední

Pacient > Echokardiografie > Záznam echokardiografie

Zavřít

Výst. zpráva

— Základní údaje —

Datum: 23.11.2021 9:45

Kód: 38319

Oddělení: Amb.dr.Tavačová

Výška: 151cm

Váha: 40,30kg

BSA: 1,31

Důvod vyšetření: HLH/TCPC,TVR,LPA stent,PACE,fce RV,fce TV?

Vyšetřil: MUDr. Viktor Tomek, Ph.D.

Vyšetření v DKC FNM

— Diagnóza —

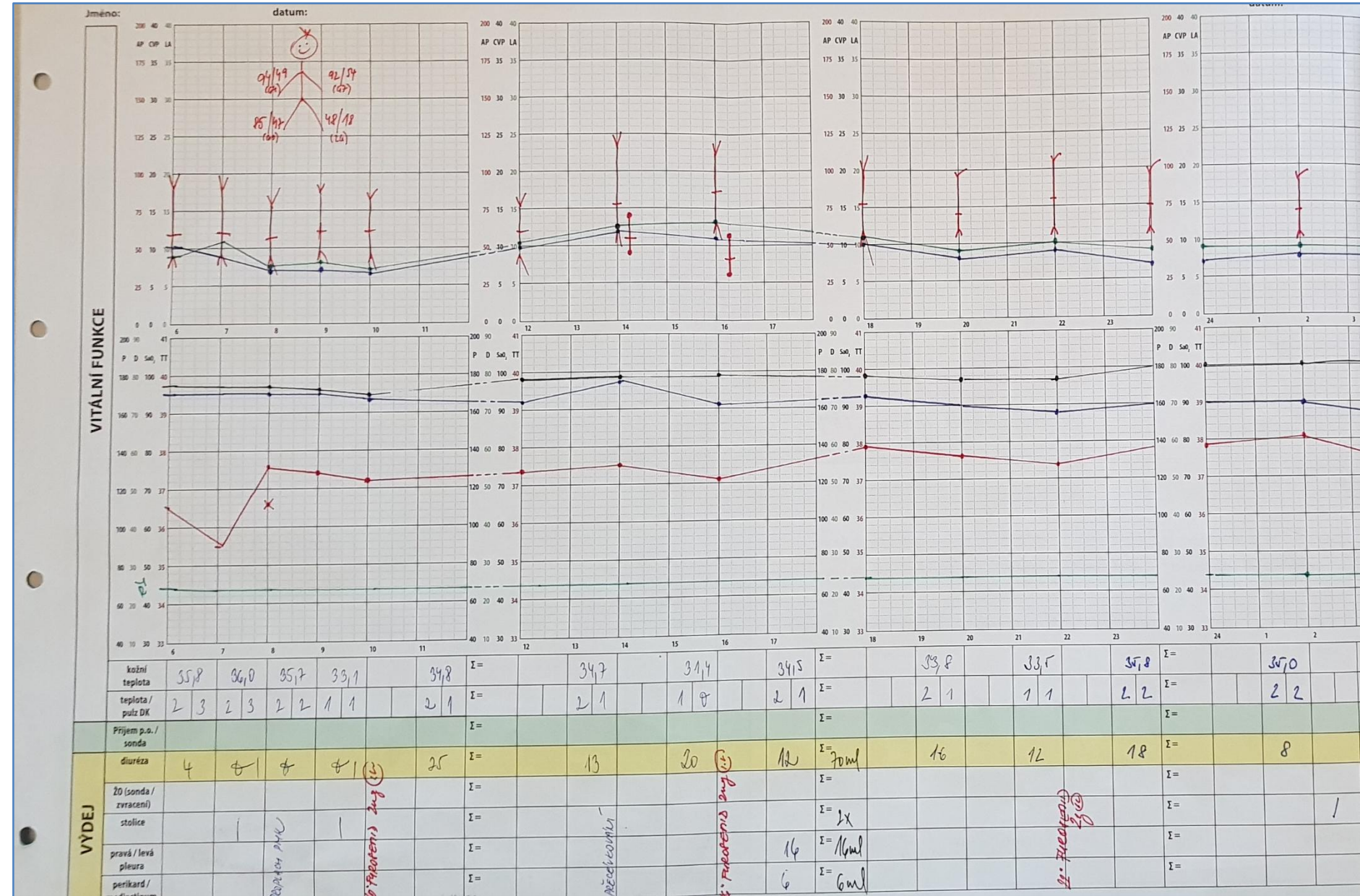
HLH Syndrom hypoplastického levého srdce  
SV/F Sdružená dg.: funkčně jediná komora  
AI Aortální insuficience  
COA Koarktace aorty

Stav pacienta: klid

Kvalita vyšetření: 3

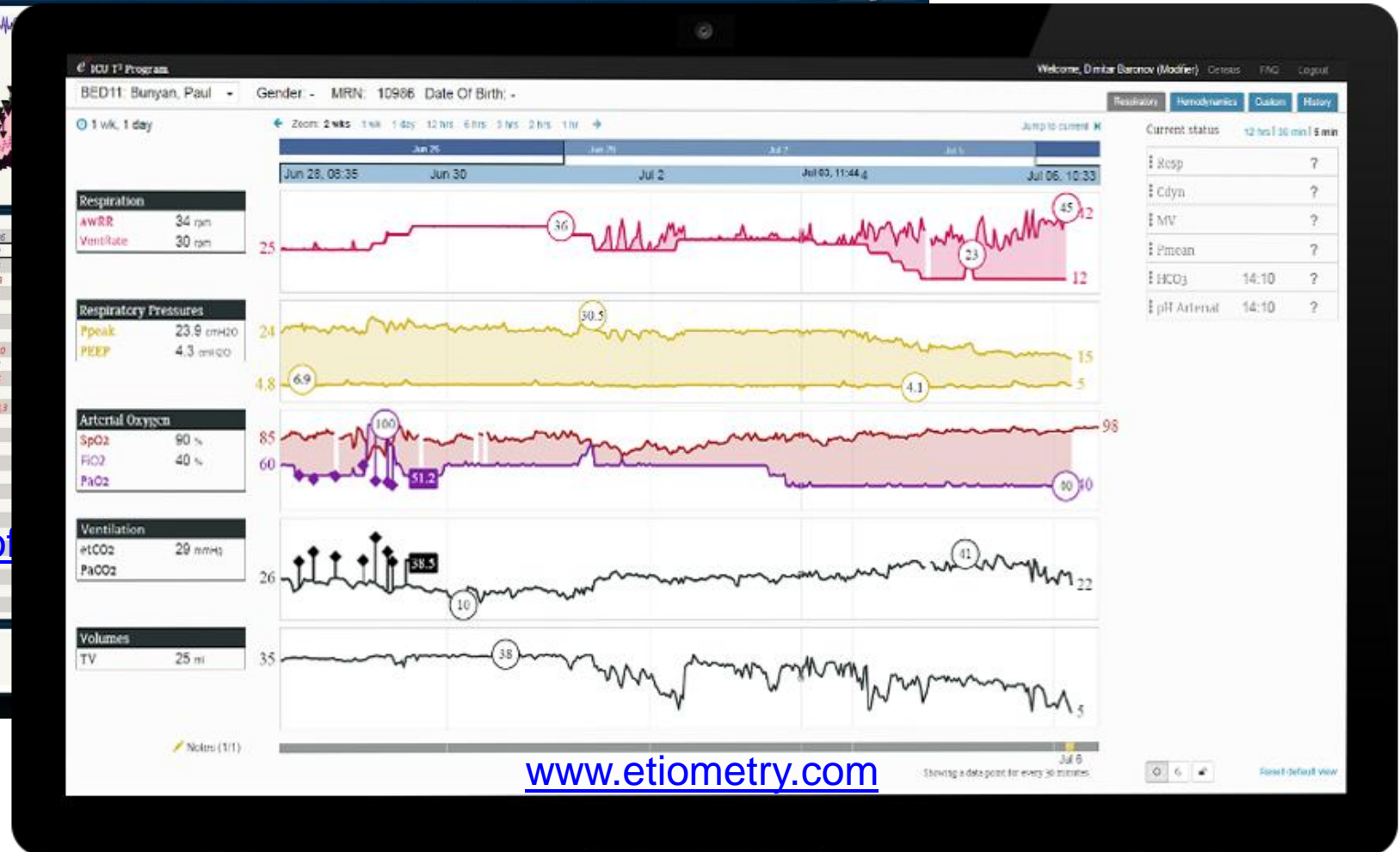
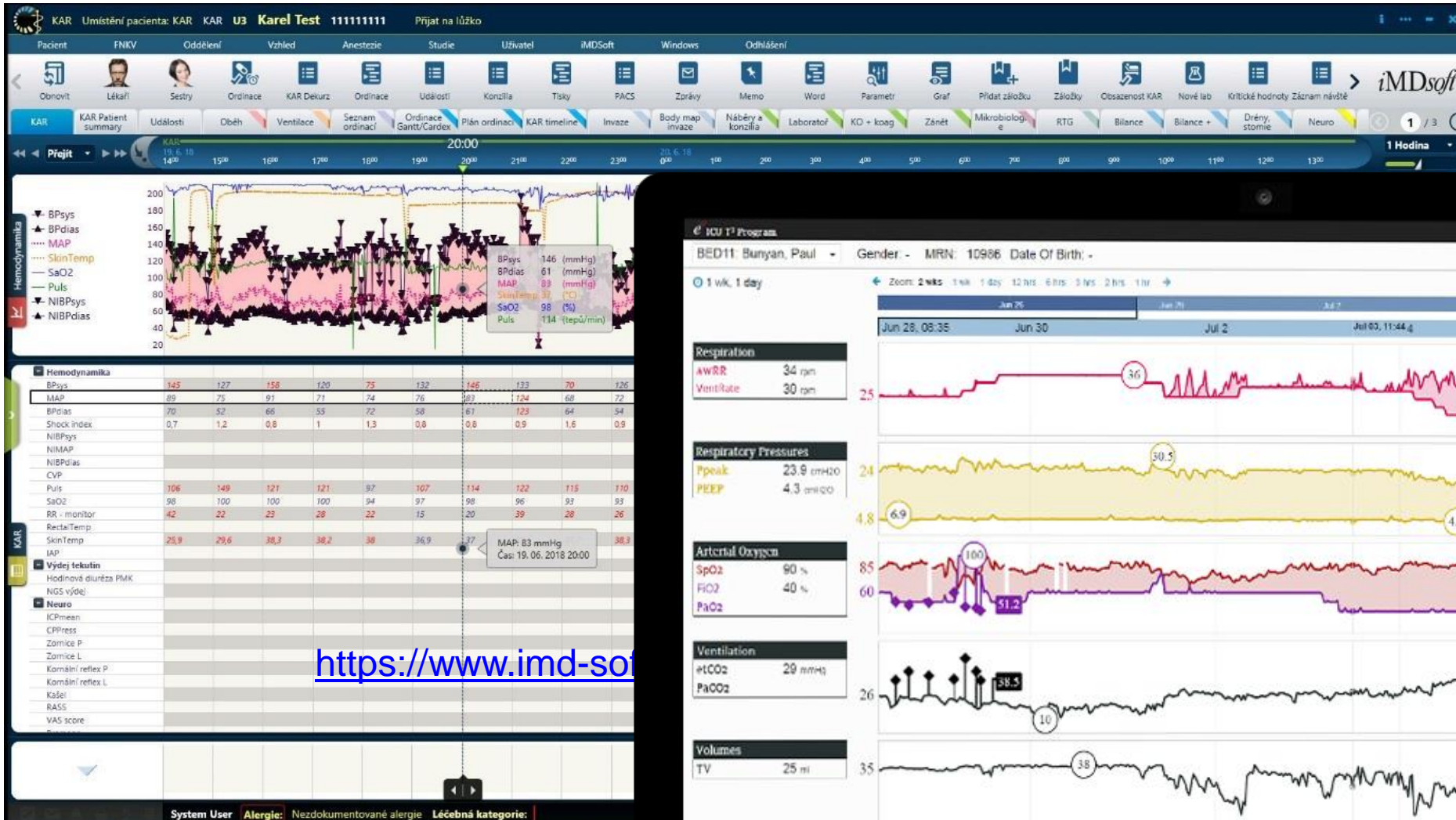
— Parametry —

# Proceeding ICU workflow as 40 years ago...





# Processing ICU data by clinical information systems and artificial intelligence





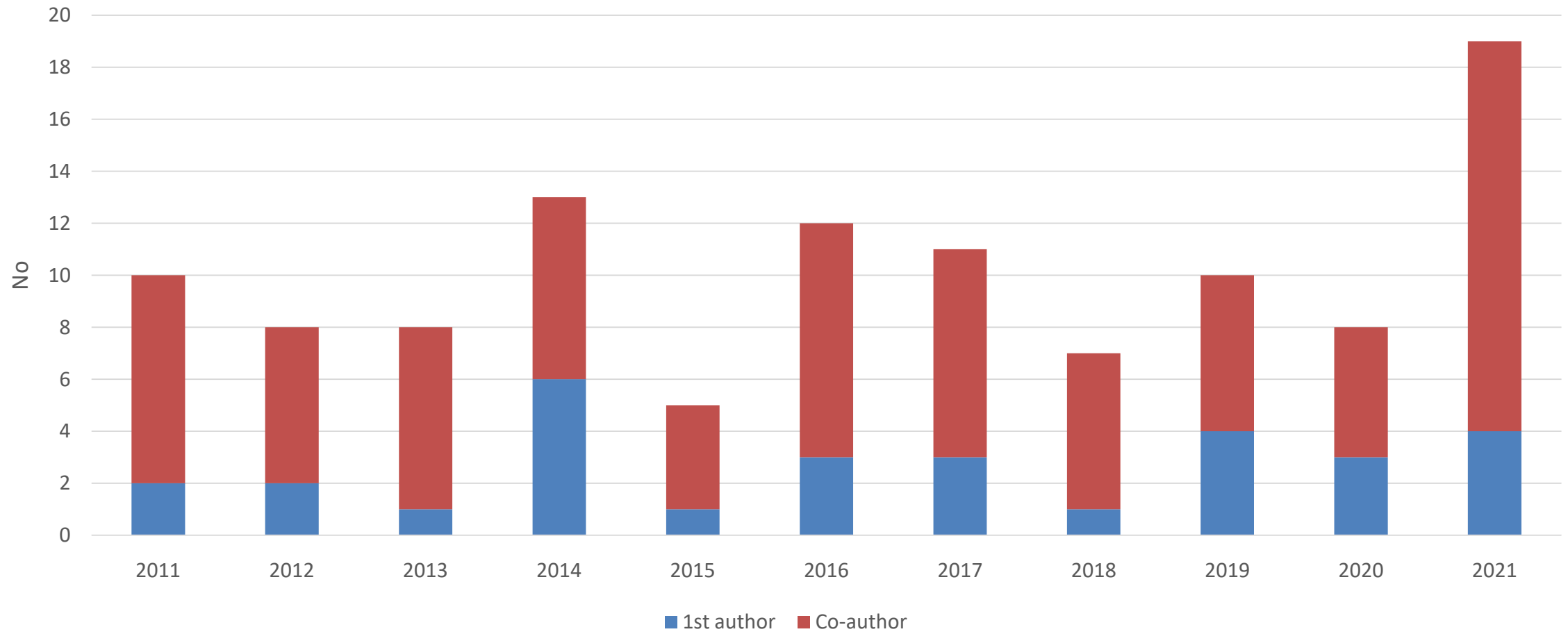


# An academic institution

- Pre-graduate/post-graduate teaching
- Original research
- Postgraduate doctoral studies

*Are an integral part of our work and continuing challenge  
on the top of clinical care*

# Impact journal publications



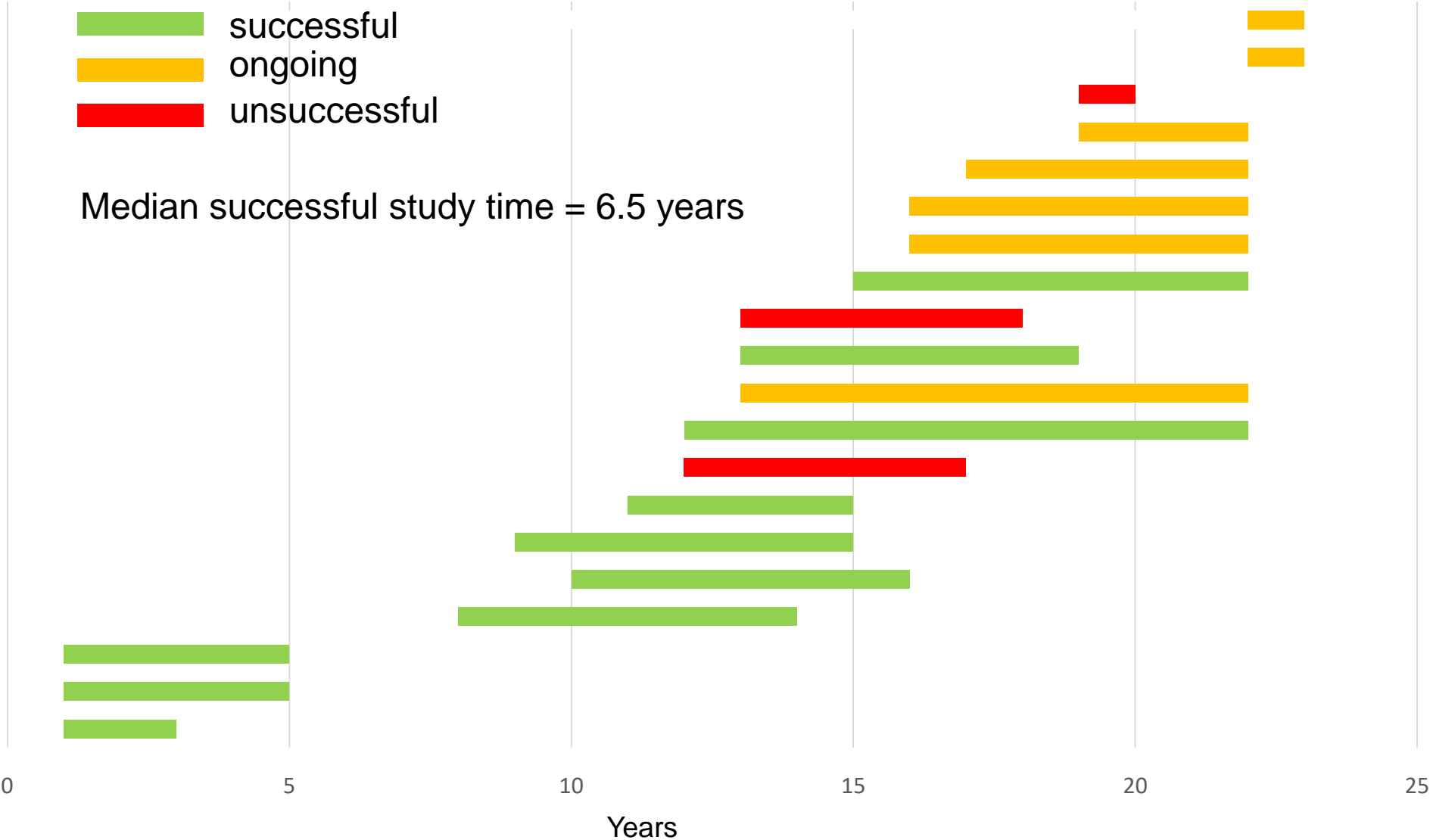
# Postgraduate doctoral studies

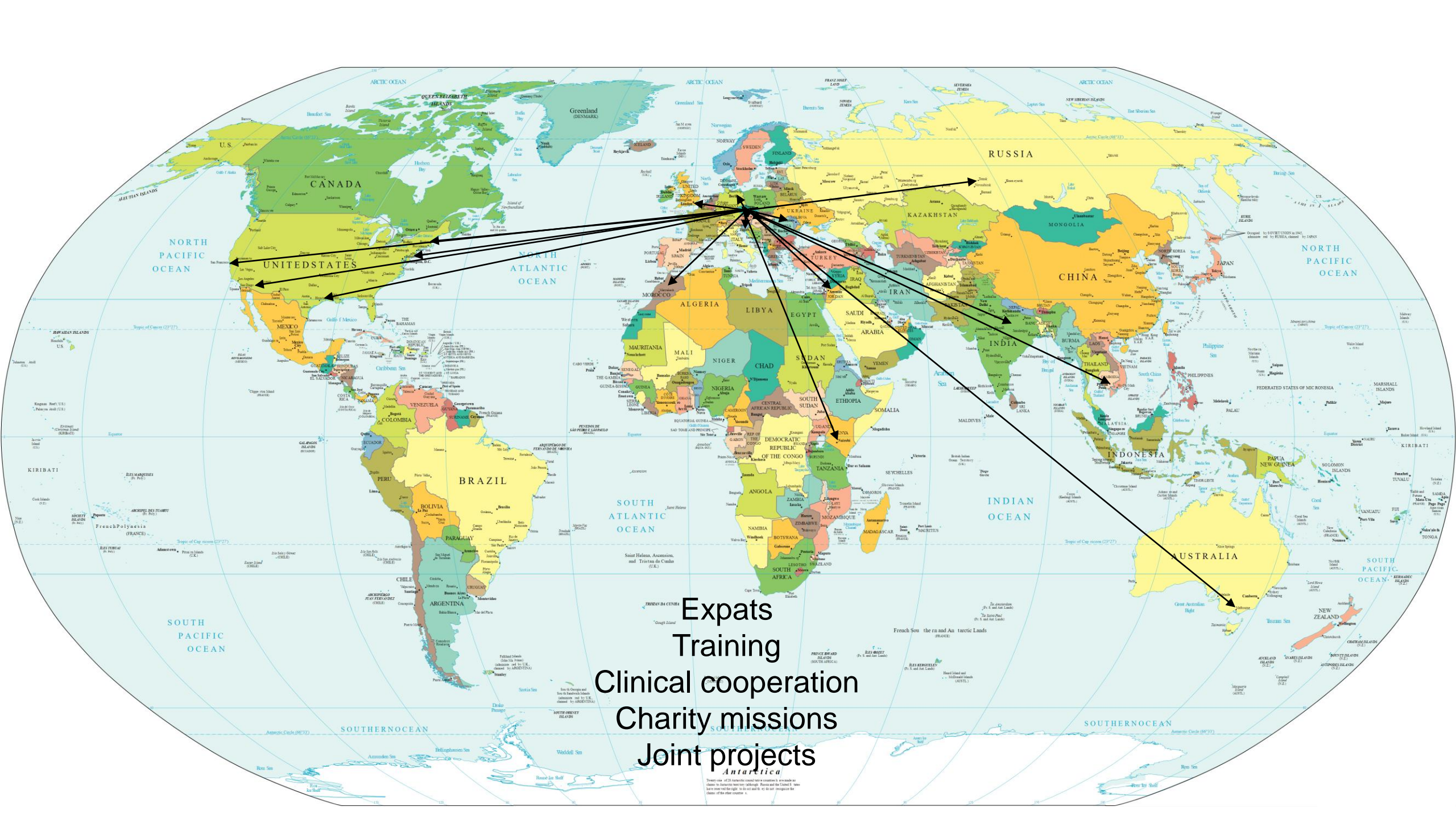
Postgraduate  
student No

1  
2  
3  
4  
5  
6  
7  
8  
9  
10  
11  
12  
13  
14  
15  
16  
17  
18  
19  
20

successful  
ongoing  
unsuccessful

Median successful study time = 6.5 years





Expats  
Training  
Clinical cooperation  
Charity missions  
Joint projects

Antarctica




A dirt road winding through a forest. The road is light-colored and leads into the distance. On either side of the road, there are tall, dry grasses and some evergreen trees. The background shows a dense forest of trees, some with bare branches and some with green needles. The sky is overcast and grey.

**Isn't it funny how day by day  
nothing changes, but when you  
look back, everything is different...**

C. S. Lewis



Tereza Beranová, 18 years: “*Together we like to help*”





The Children's Heart Centre  
celebrates its 45<sup>th</sup> birthday

*No time for nostalgia  
or middle age crisis....*

