



Sekce „jak na to“: Náhlá srdeční smrt u strukturálně normálního srdce

Súčasnú možnosti mapovania a katéetrovej ablácie pri kanálopatiách

Peter Hlivák

OAKS NÚSCH a LF SZU,

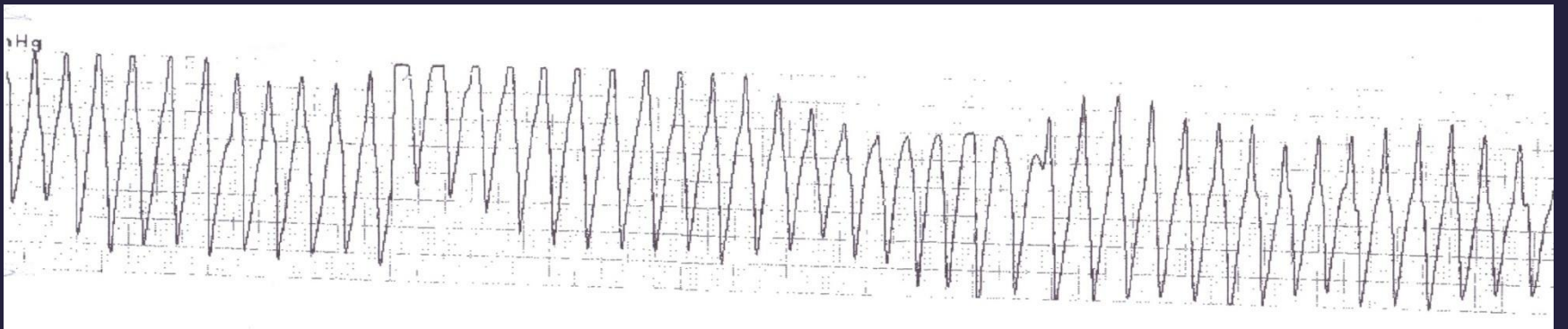
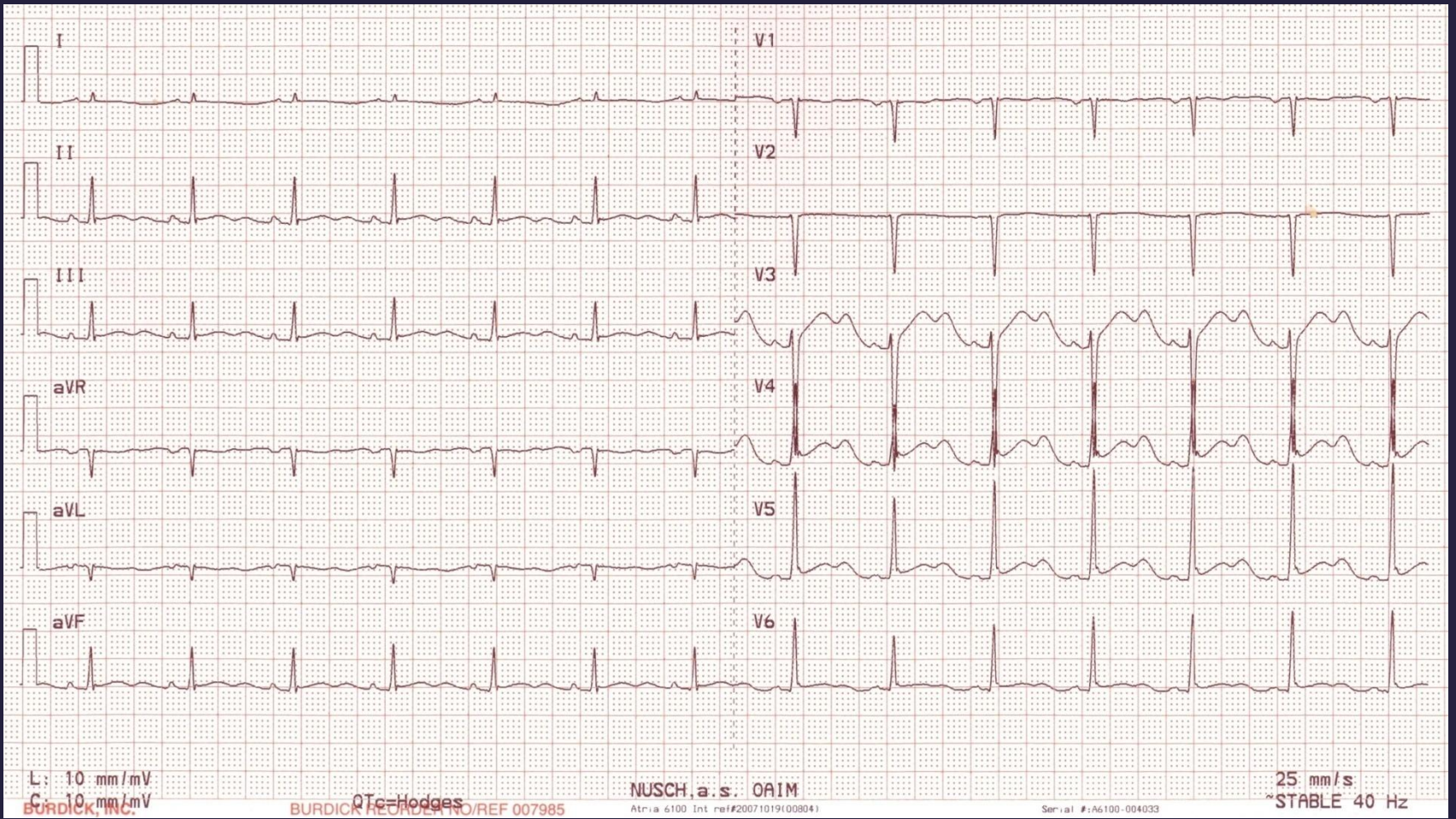
Bratislava,



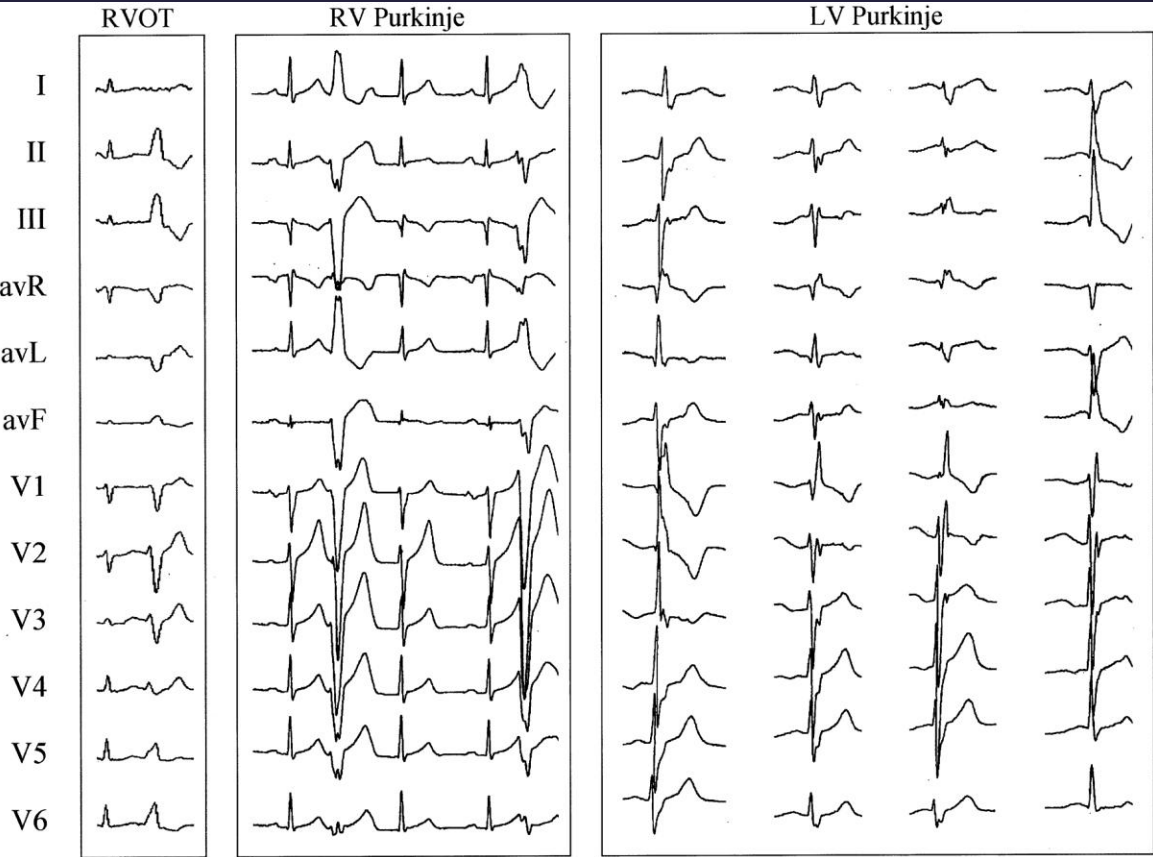
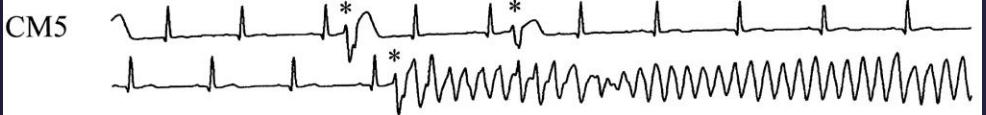
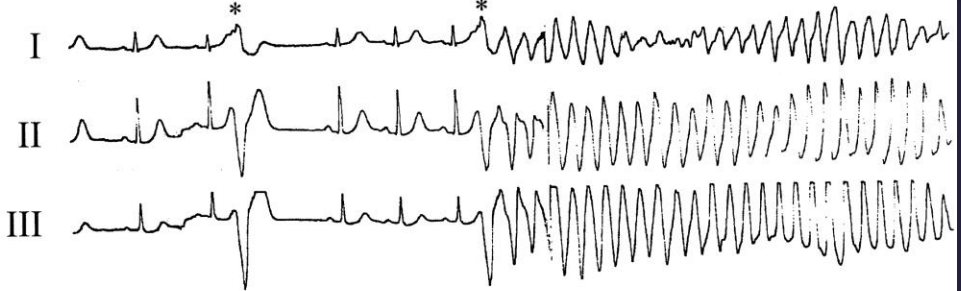
XVI. české a slovenské sympóziium o arytmiách a kardiostimulácii, Ostrava, 11-13.11.2018

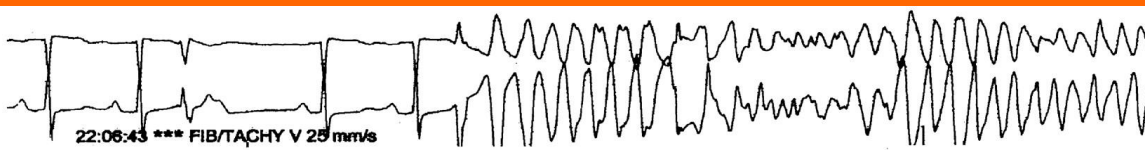
Vrodené primárne arytmičné syndrómy - "kanálopatie"

- Syndróm dlhého QT intervalu (LQT)
- Brugadaov syndróm
- Syndróm krátkeho QT intervalu (SQT)
- Syndróm včasnej repolarizácie
- Idiopatická fibrilácia komôr



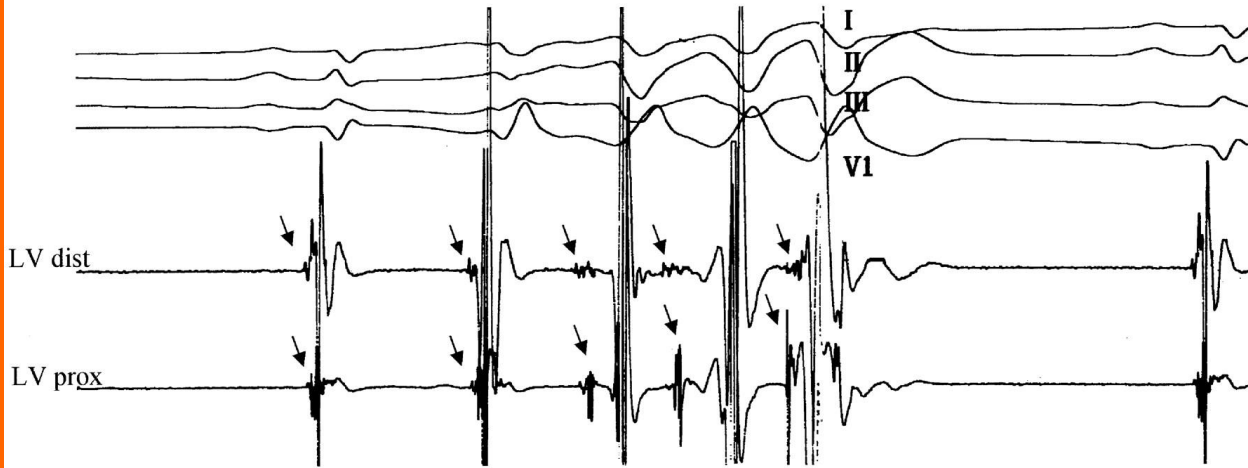
Catheter ablation in idiopathic VF





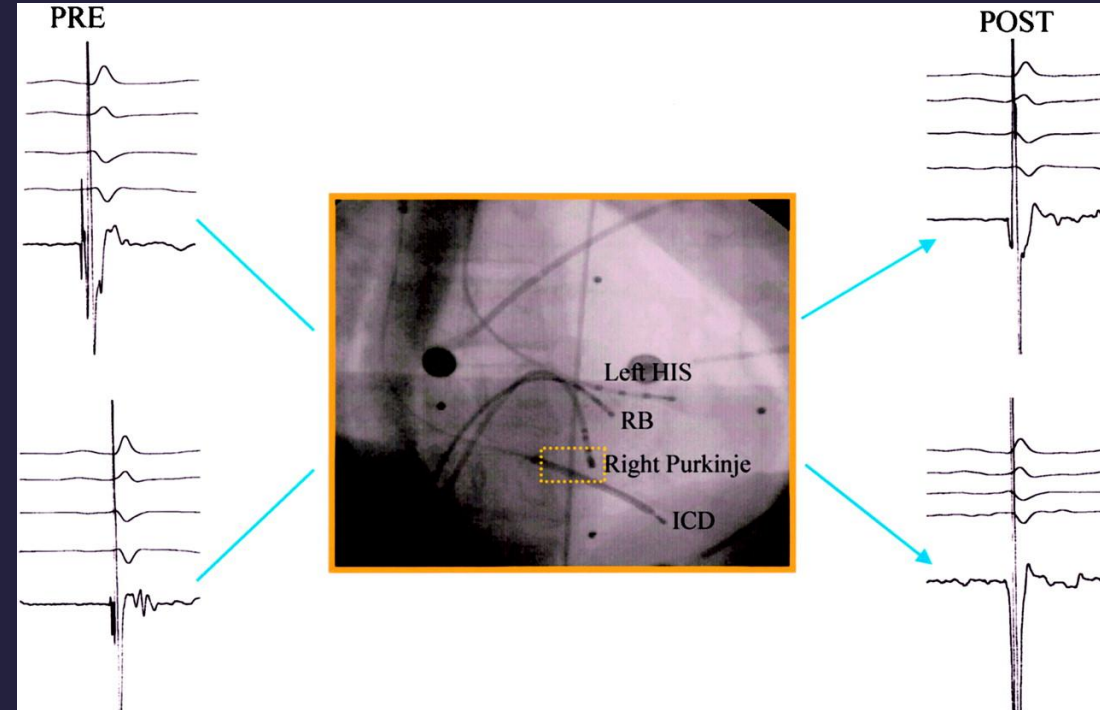
Catheter ablation in idiopathic VF

Haïssaguerre M et al. *Circulation*. 2002;106:962-967



- 38 pts (21 men), 42 ± 13 y
- median FU 63 months
- 7 (18%) experienced VF recurrence at a median of 4 months.
 - 5 of these 7 pts repeat ablation without VF recurrence
- Survival free of VF predicted only by transient bundle-branch block during EPS ($p < 0.0001$).
- number of significant events (confirmed VF or aborted SCD) reduced from 4 (interquartile range 3 to 9) before to 0 (IR 0 to 4) after ablation ($p = 0.01$).

Knecht S et al. *Am Coll Cardiol* 2009;54:522-8

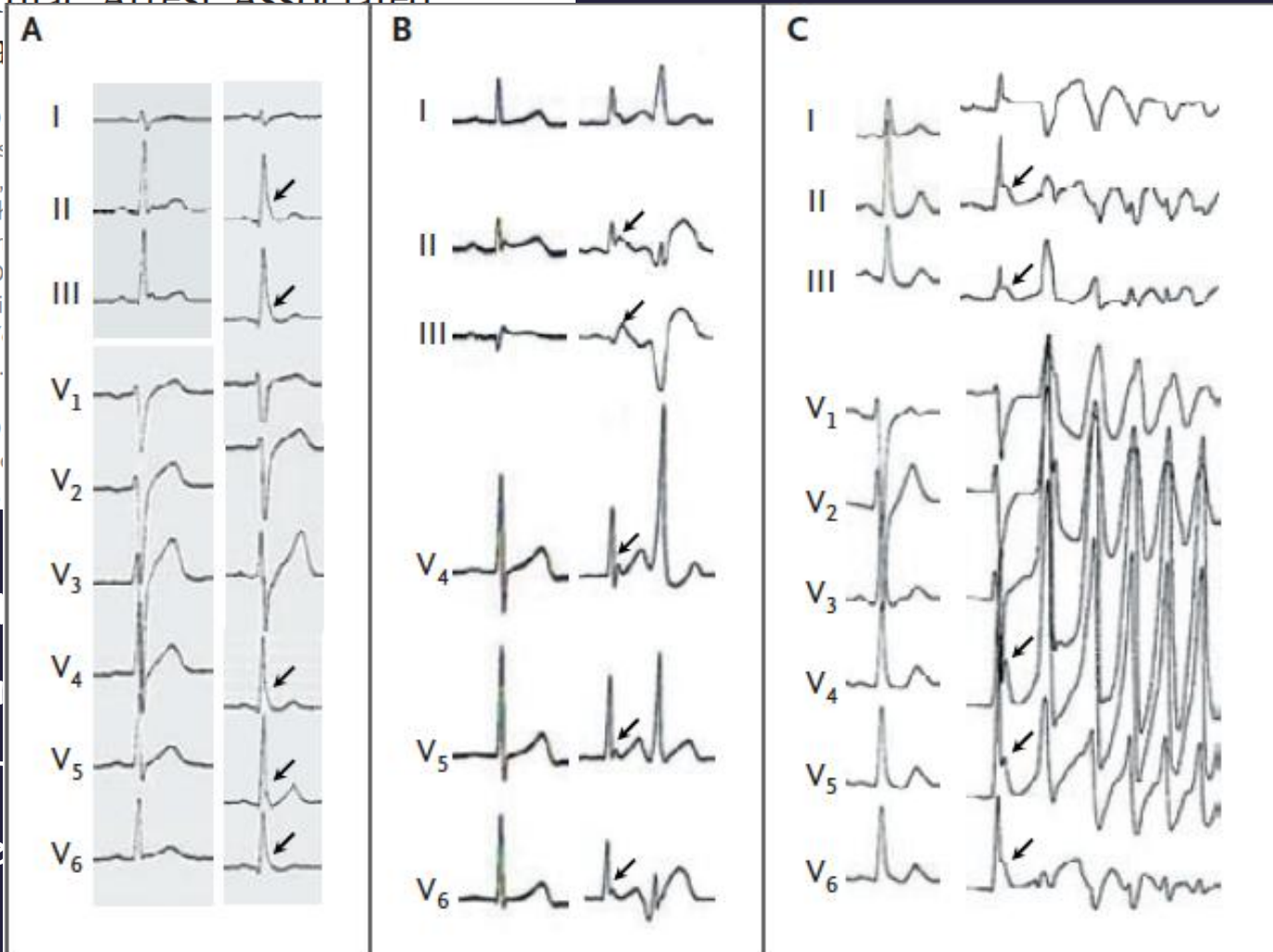


ORIGINAL ARTICLE

Sudden Cardiac Arrest Associated with Epsilon Waves

Michel Haïssaguerre, M.D.
Laurence Jesel, M.D., Is
Jean-Luc Pasquié, M.D., Ph.D.,
Sinikka Yli-Mayry, M.D., Ch
Philippe Mabo, M.D., Seich
Solena Le Scouarnec, Ph.D.
Thomas Rostock, M.D., Domi
Thomas Lavergne, M.D., Y
Frederic Anselme, M.D.
Kang Teng Lim,
George D. Veenhuyzen, M.D.
Pierre Jais, M.D., Gaell
George J. Klein,

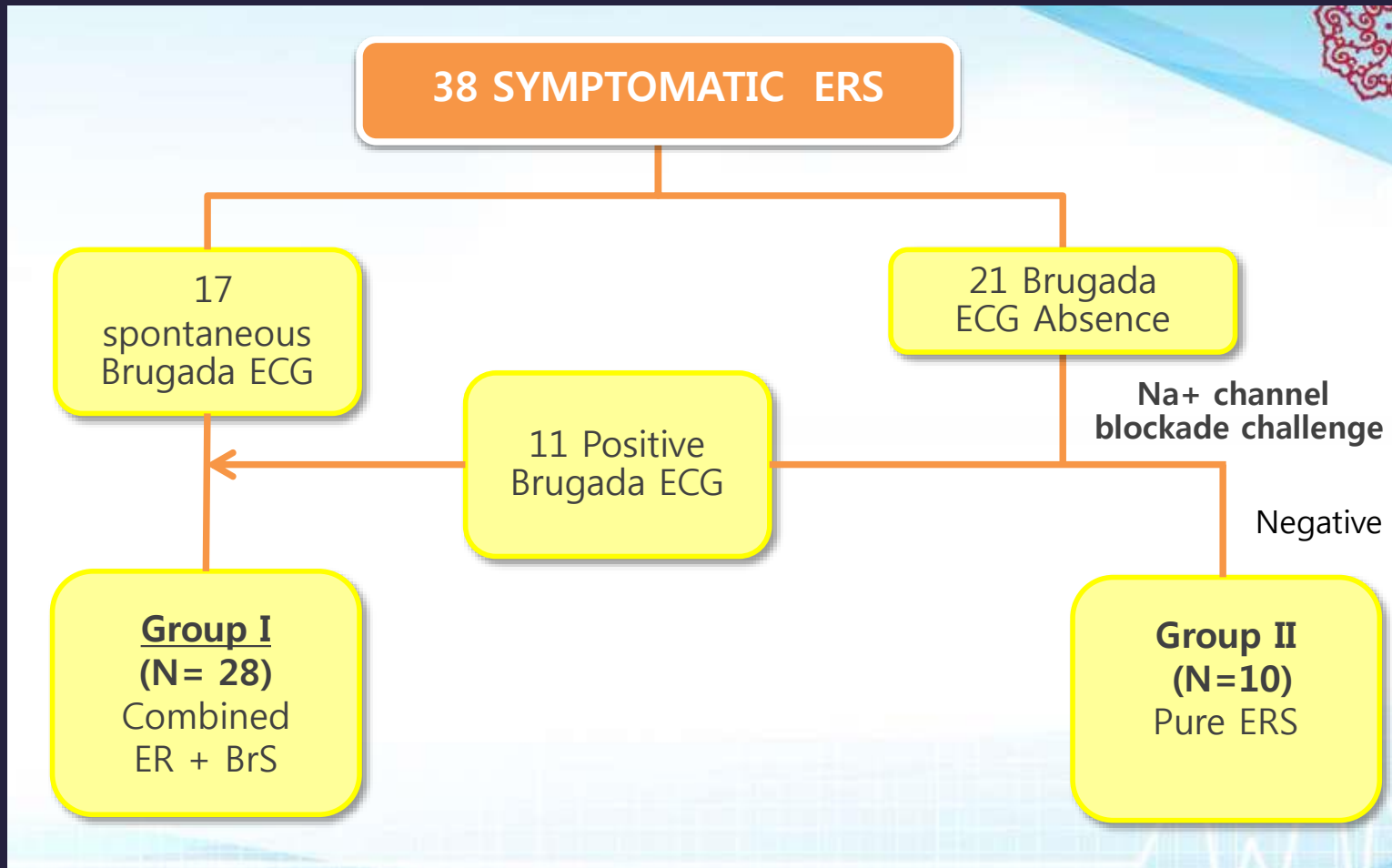
- 206 cases, 22 cent
- idiopathic ventricu
- Among patients wi
- is an increased pre



Early Repolarization Syndrome

- Are the underlying electrophysiologic mechanisms underlying ERS the same in experiments/animal models and in humans?
- What are the VF triggers and what is the substrate in ER syndrome?
- Could ablation be effective in ERS as alternative treatment modality from quinidine ?

Mapping and ablation



Symptomatic ERS

1. Electroanatomical Mapping.
2. ECGI Mapping

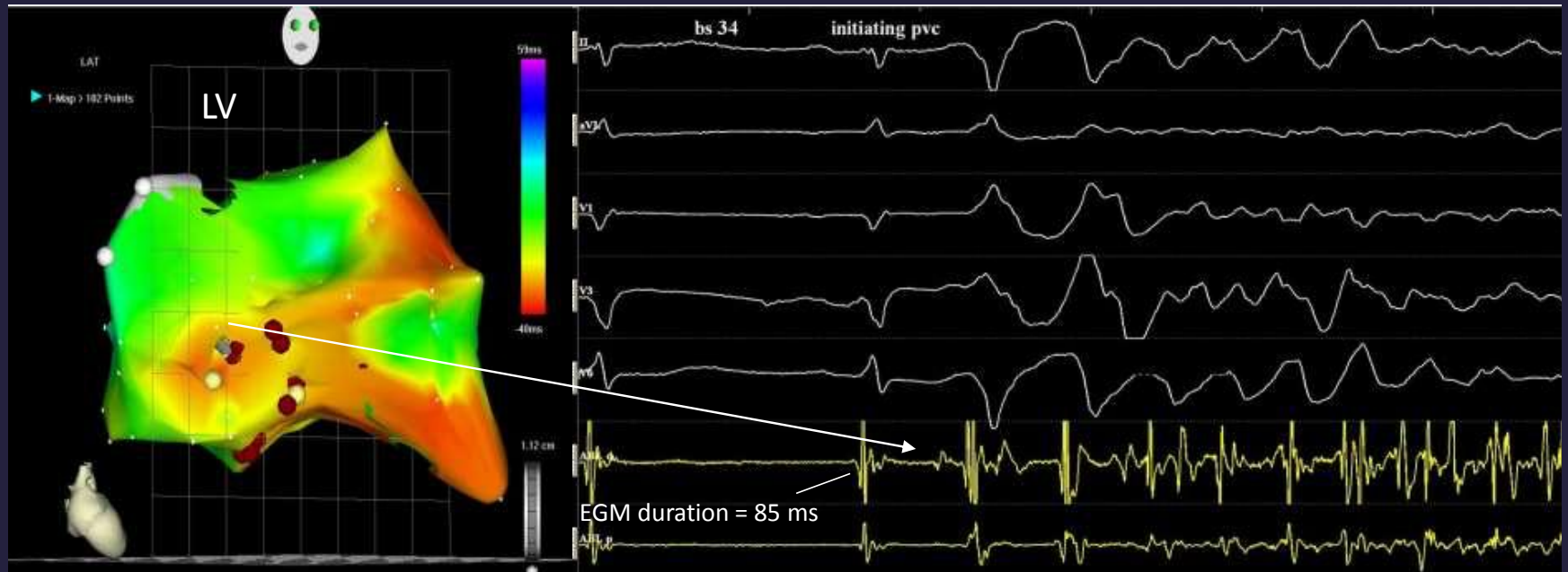
VF Triggers

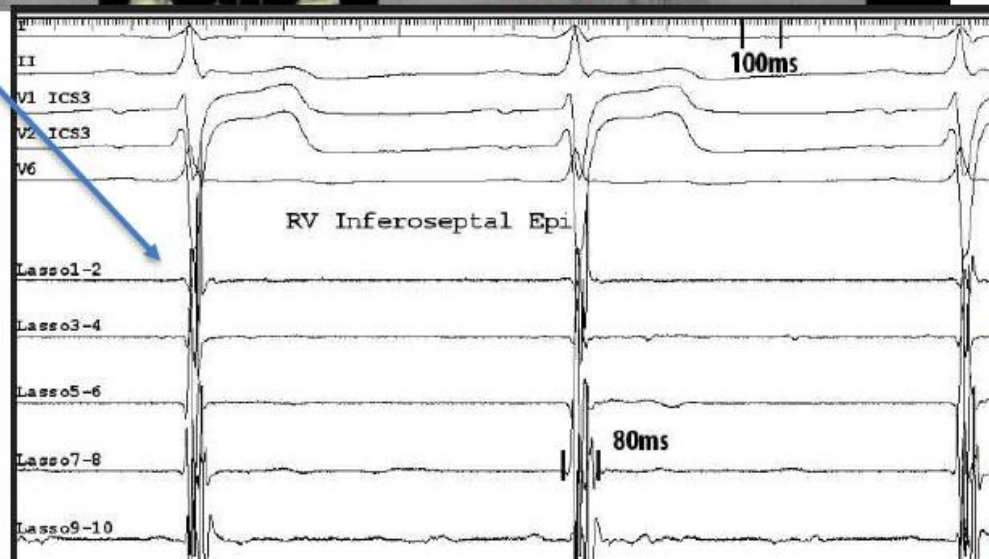
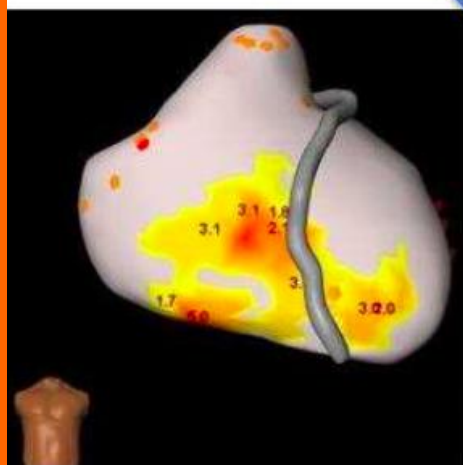
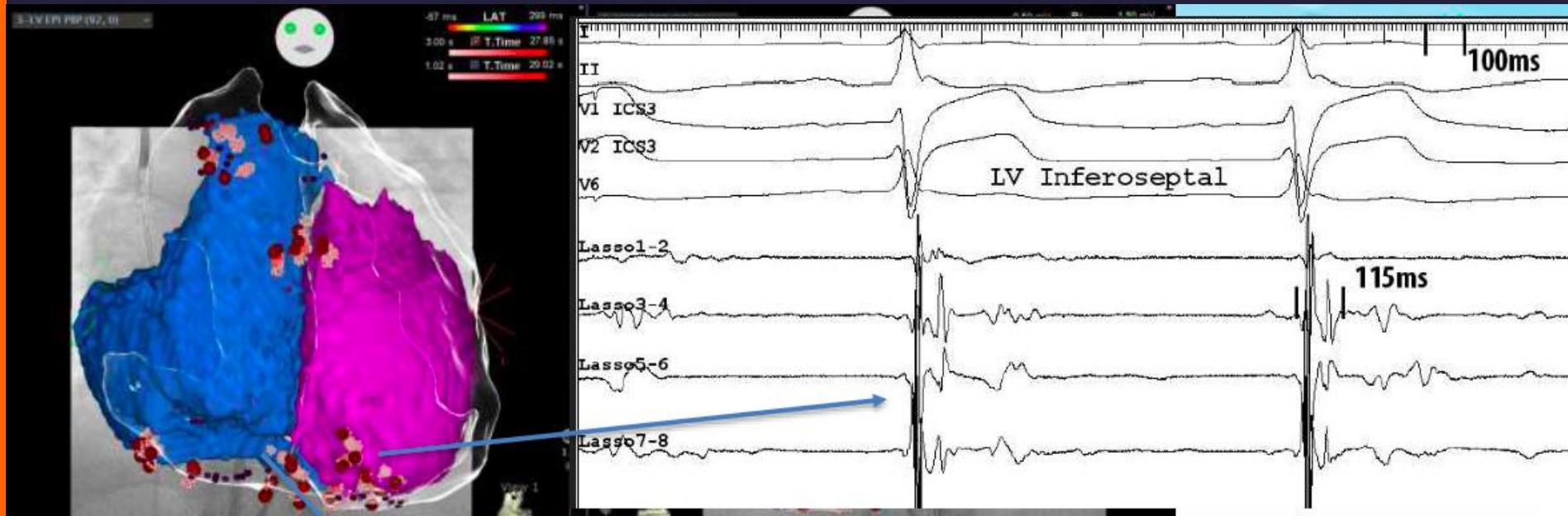
Abnormal Purkinje system

VF substrates

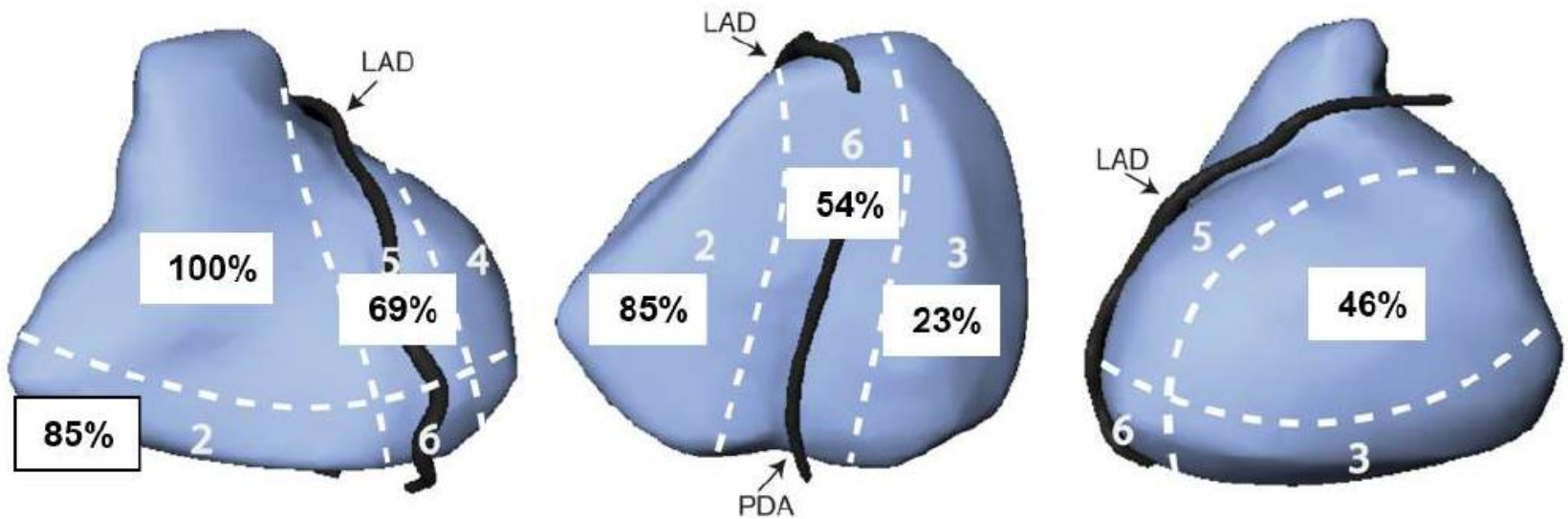
Endo- Epicardial mapping during NSR at baseline and after Na⁺ Channel Blockade and during VF

VF triggers





Anatomical Distribution of VF Drivers



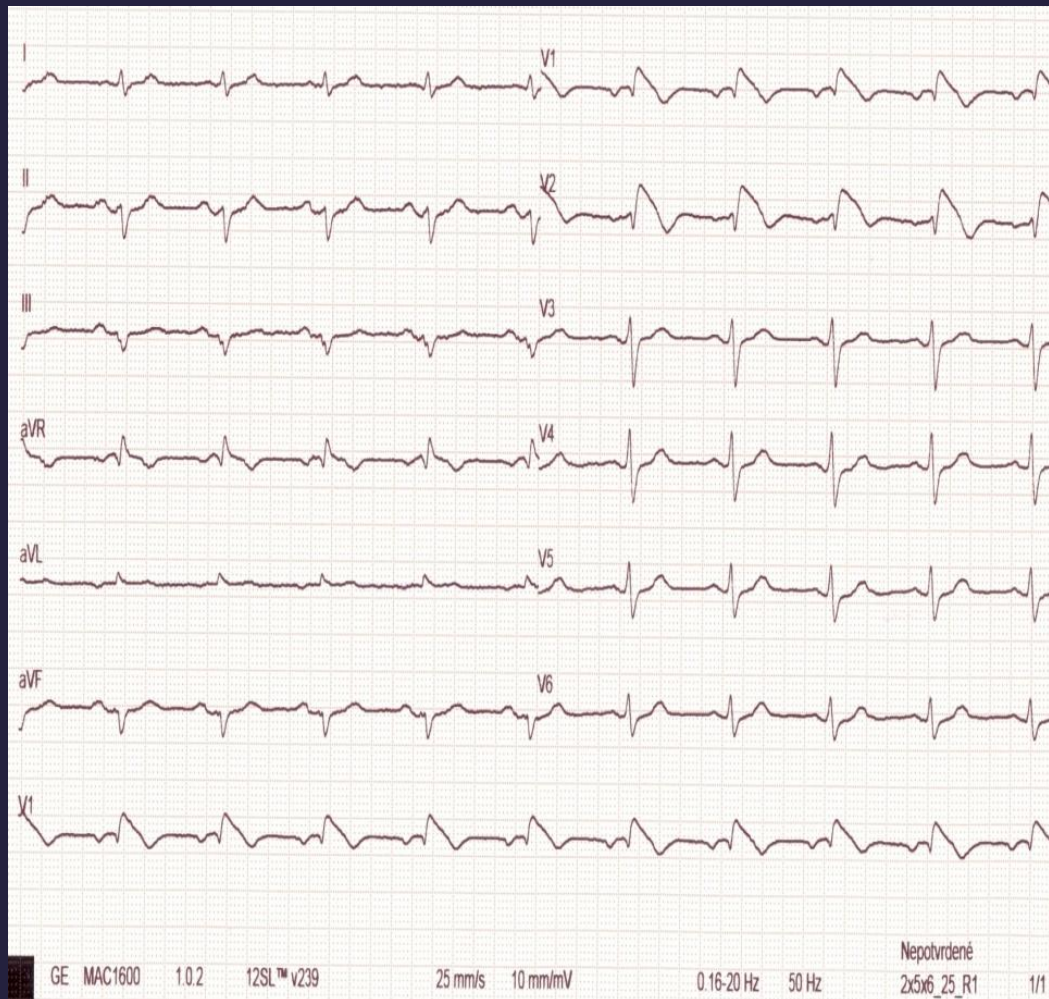
Záver: Syndróm včasnej repolarizácie

- **Syndróm včasnej repolarizácie typ 1:** Syndróm so substrátom pre FK, ktorá je charakterizovaný abnormalitami depolarizácie: s dôkazom oblastí s nízko voltážovými frakcionovanými signálmi ktoré korešpondujú s fokálnymi aktivitami a rotormi detekovanými pomocou ECGI → reprezentujú excelentný substrát pre katétrovú abláciu
- **Syndróm včasnej repolarizácie typ 2:** Syndróm bez identifikovateľného substrátu pre FK no s prítomnosťou abnormálneho Purkyňovho systému ako spúšťača a iniciátora FK, výlučne sa vyskytujúcom pri "čistom" syndróme včasnej repolarizácie.
- *alebo skutočná abnormalita repolarizácie ?*

Mapovanie a ablácia pri syndróme včasnej repolarizácie

- **KES**, ktoré spúšťajú FK bežne vychádzajú **z Purkyňovho systému ĽK aj PK** a predstavujú cieľ ablácie
- Dobrý cieľ pre abláciu predstavuje sieť Purkyňových vlákien pozdĺž inferoseptálnej a anteroseptálnej steny ĽK, ktorá je súčasťou substrátu pre FK, osobitne u pacientov, ktorí nemajú identifikovateľné spúšťače FK a FK substrát
- Substrát pre FK sa nachádza **dominantne na anteriórnom RVOT a epikarde PK** (inferolaterálne a voľná stena), no tiež na epikarde ĽK a/alebo zriedka endokardiálne v PK aj ĽK.
- EKG zobrazovanie (CardioInsight - ECGI) a elektroanatomické mapovanie sú užitočné pri identifikácii uvedených substrátov pre FK

Syndróm Brugadovcov



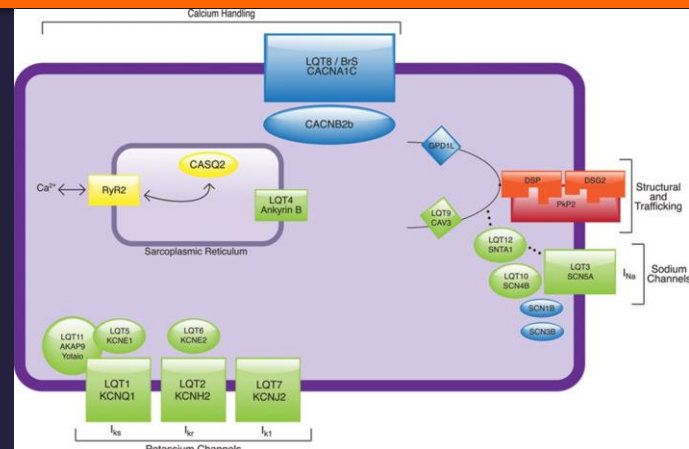
Radiofrequency Catheter Ablation in BrS

HRS/EHRA/APHRS Expert Consensus Statement on the Diagnosis and Management of Patients with Inherited Primary Arrhythmia Syndromes

Silvia G. Priori, MD, PhD, (HRS Chairperson)¹, Arthur A. Wilde, MD, PhD, (EHRA Chairperson)², Minoru Horie, MD, PhD, (APHRS Chairperson)³, Yongkeun Cho, MD, PhD, (APHRS Chairperson)⁴, Elijah R. Behr, MA, MBBS, MD, FRCP⁵, Charles Berul, MD, FHRS, CCDS⁶, Nico Blom, MD, PhD^{7,*}, Josep Brugada, MD, PhD⁸, Chern-En Chiang, MD, PhD⁹, Heikki Huikuri, MD¹⁰, Prince Kannankeril, MD^{11,†}, Andrew Krahn, MD, FHRS¹², Antoine Leenhardt, MD¹³, Arthur Moss, MD¹⁴, Peter J. Schwartz, MD¹⁵, Wataru Shimizu, MD, PhD¹⁶, Gordon Tomaselli, MD, FHRS^{17,†}, Cynthia Tracy, MD^{18,%}

After the demonstration that VF events were triggered by ventricular ectopy of similar morphology, **radiofrequency ablation of ventricular ectopy** has been postulated as a therapeutic approach in BrS patients. Few anecdotal cases in high-risk BrS implanted with an ICD have shown no short-term recurrence of VF, syncope or SCD. **Nademanee et al** have presented the first series showing that electrical **epicardial substrate ablation in the RVOT** can prevent VF inducibility in a high-risk population. However, randomized data on the effect of catheter ablation on spontaneous arrhythmic events are lacking.

Catheter ablation in inherited primary arrhythmia syndromes



- Ablation of Purkinje potentials may be considered in patients with a diagnosis of IVF presenting with uniform morphology PVCs in conjunction with ICD implantation or when ICD implantation is contraindicated or refused (Class IIb)
- Catheter ablation of the bidirectional VPBs that trigger VF may become an adjunctive therapy in patients with refractory CPVT. However, the published experience is very limited and therefore is not discussed in the recommendation

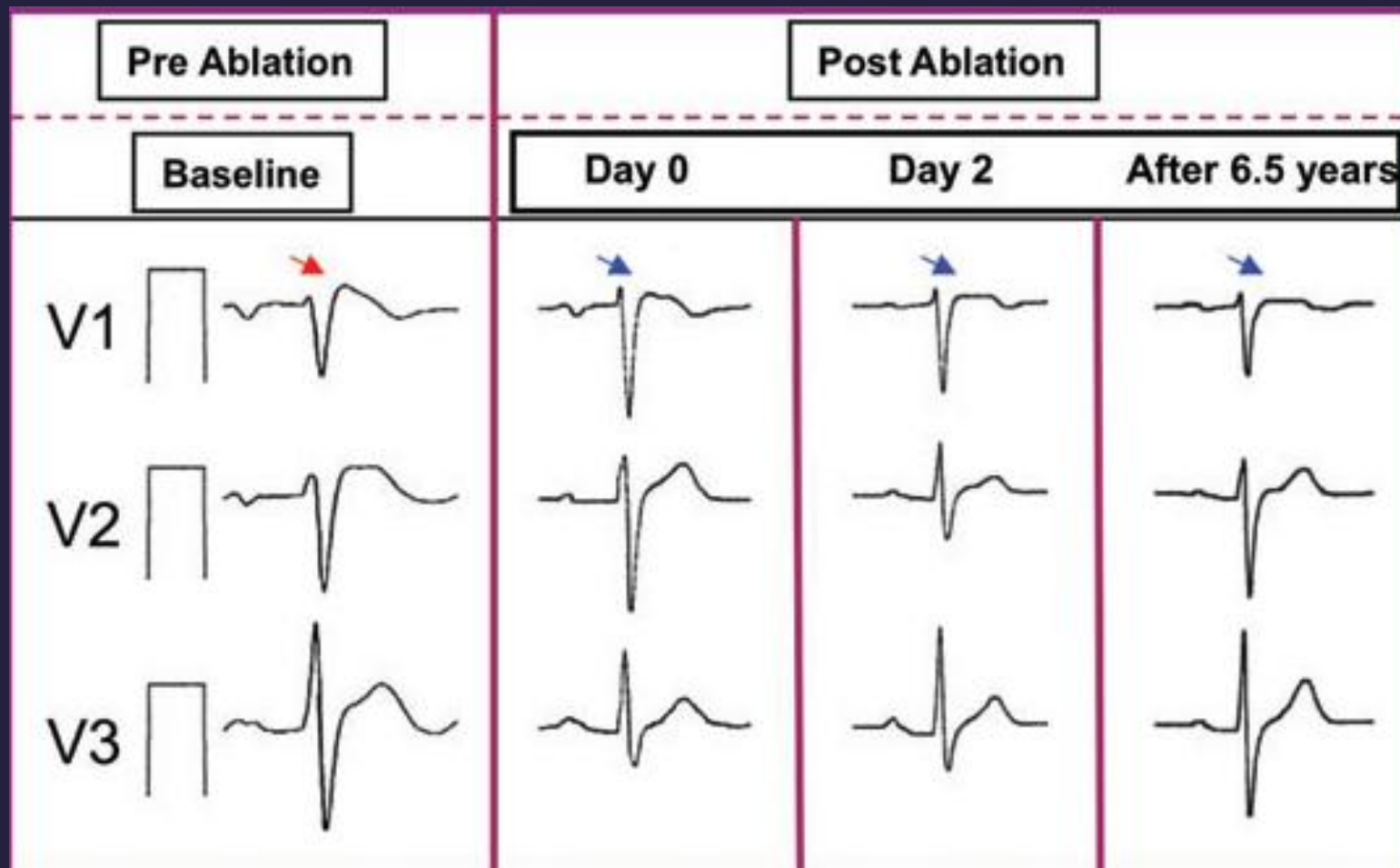
Expert Consensus Recommendations on Brugada Syndrome Therapeutic Interventions

- Class I
1. The following lifestyle changes **are recommended** in all patients with diagnosis of BrS:
 - a) Avoidance of drugs that may induce or aggravate ST-segment elevation in right precordial leads (for example, visit Brugadadrugs.org),
 - b) Avoidance of excessive alcohol intake.
 - c) Immediate treatment of fever with antipyretic drugs.
 2. ICD implantation **is recommended** in patients with a diagnosis of BrS who:
 - a) Are survivors of a cardiac arrest and/or
 - b) Have documented spontaneous sustained VT with or without syncope.
- Class IIa
3. ICD implantation **can be useful** in patients with a spontaneous diagnostic type I ECG who have a history of syncope judged to be likely caused by ventricular arrhythmias.
 4. Quinidine **can be useful** in patients with a diagnosis of BrS and history of arrhythmic storms defined as more than two episodes of VT/VF in 24 hours.
 5. Quinidine **can be useful** in patients with a diagnosis of BrS:
 - a) Who qualify for an ICD but present a contraindication to the ICD or refuse it *and/or*
 - b) Have a history of documented supraventricular arrhythmias that require treatment.
 6. Isoproterenol infusion **can be useful** in suppressing arrhythmic storms in BrS patients.
- Class IIb
7. ICD implantation **may be considered** in patients with a diagnosis of BrS who develop VF during programmed electrical stimulation (inducible patients).
 8. Quinidine **may be considered** in asymptomatic patients with a diagnosis of BrS with a spontaneous **type I ECG**.
 9. Catheter ablation **may be considered** in patients with a diagnosis of BrS and history of arrhythmic storms or repeated appropriate ICD shocks.
- Class III
10. ICD implantation **is not indicated** in asymptomatic BrS patients with a drug-induced **type I ECG** and on the basis of a family history of SCD alone.

Regional Substrate Ablation Abolishes Brugada Syndrome

ASHOK J. SHAH, M.D.,* MELEZE HOCINI, M.D.,* DOMINIQUE LAMAISON, M.D.,†
FREDERIC SACHER, M.D.,* NICOLAS DERVAL, M.D.,* and MICHEL HAISSAGUERRE, M.D.*

From the *Hôpital Cardiologique du Haut-Lévêque and the Université Bordeaux II, Bordeaux, France; and †Hôpital Gabriel Montpied – Complexe Hospitalier St Jacques – CHU, Clermont-Ferrand, France



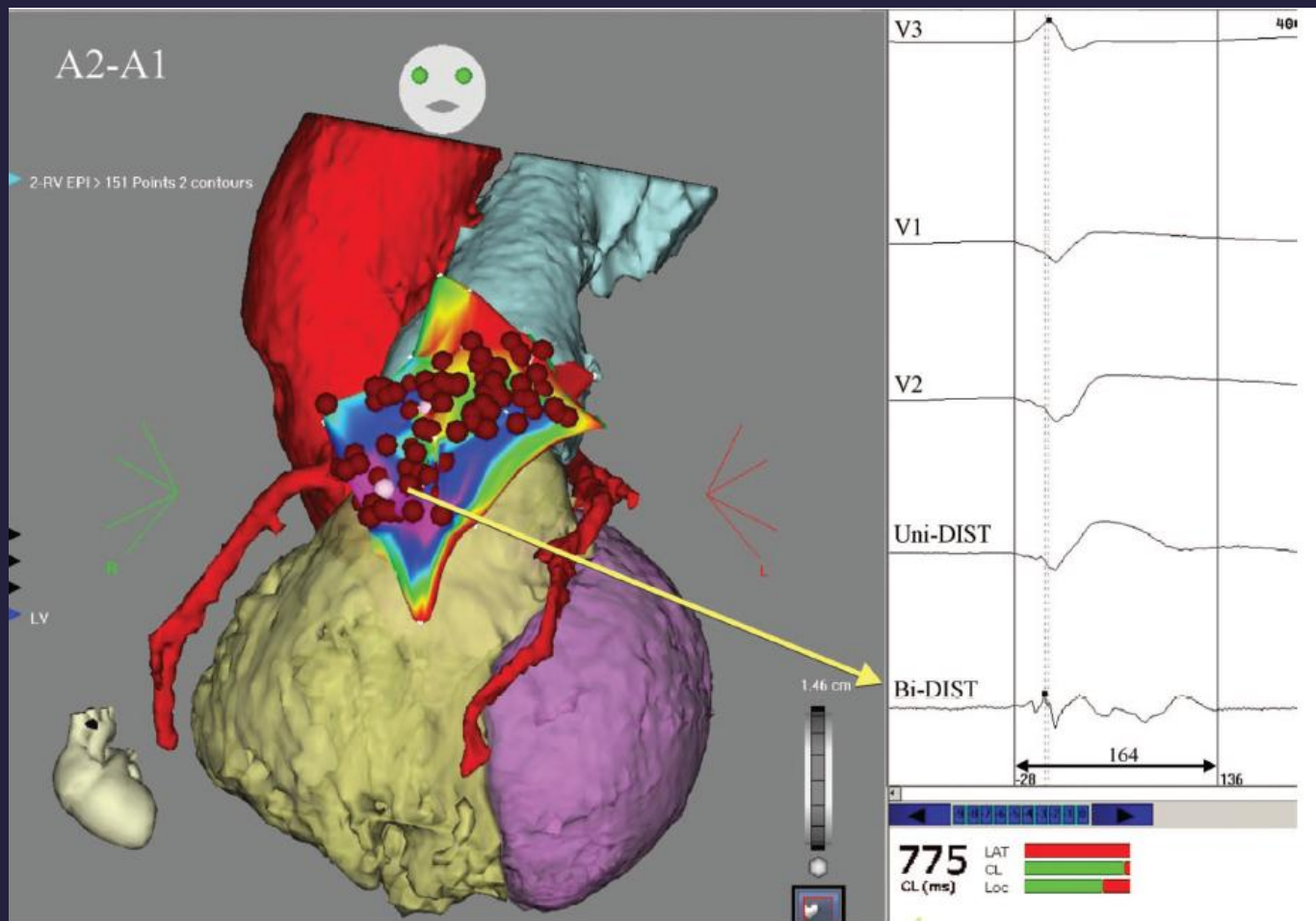
Arrhythmia/Electrophysiology

Prevention of Ventricular Fibrillation Episodes in Brugada Syndrome by Catheter Ablation Over the Anterior Right Ventricular Outflow Tract Epicardium

Koonlawee Nademanee, MD; Gumpanart Veerakul, MD; Pakorn Chandanamatha, MD;
Lertlak Chaothawee, MD; Aekarach Ariyachaipanich, MD; Kriengkrai Jirasirojanakorn, MD;
Khanchit Likittanasombat, MD; Kiertijai Bhuripanyo, MD; Tachapong Ngarmukos, MD

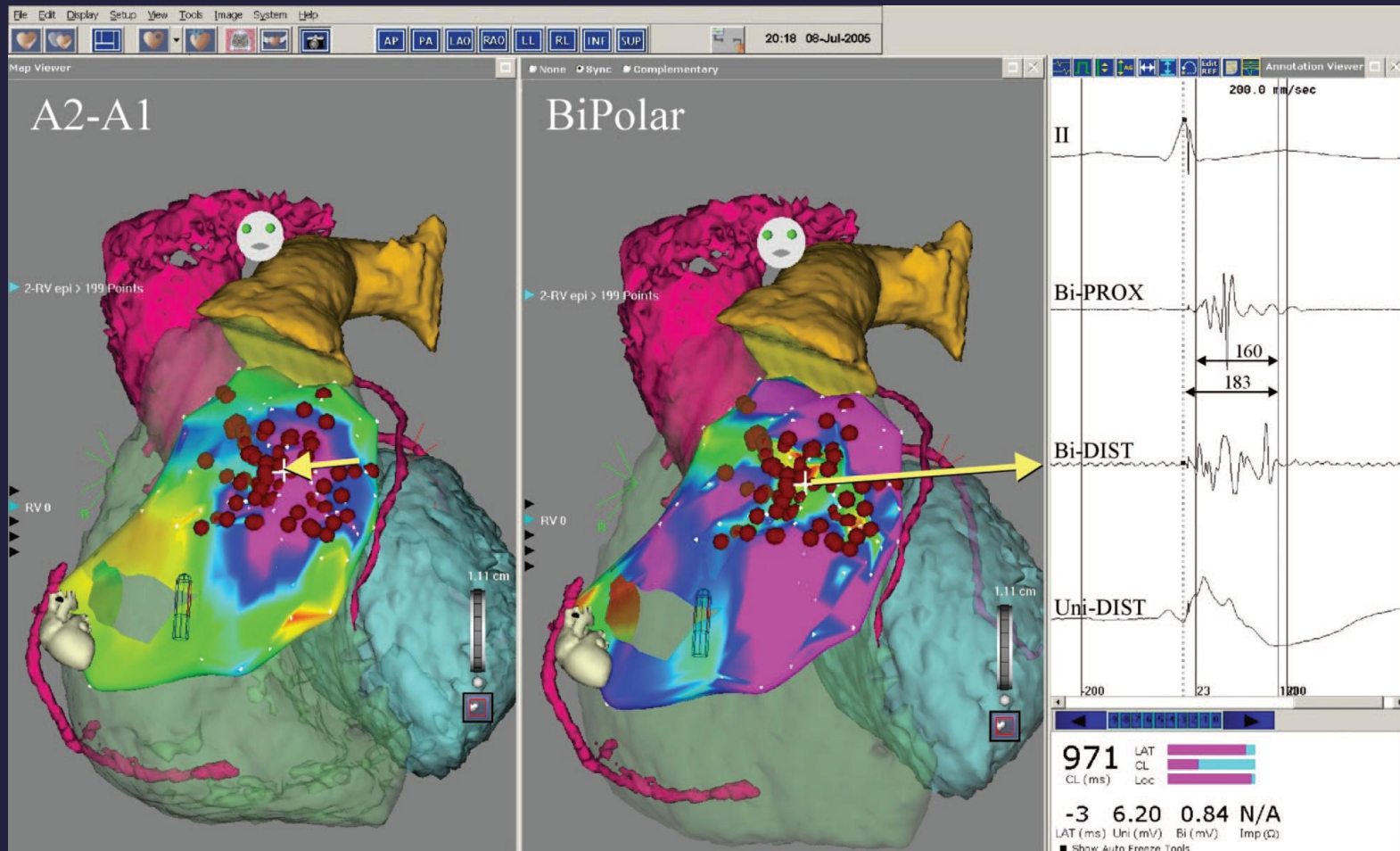
- 9 symptomatic patients with the BrS (all men; median age 38 years)
- all pts had typical type 1 Brugada ECG pattern and inducible VT /VF
- **unique abnormal low voltage** (0.94 ± 0.79 mV)
- **prolonged duration** (132 ± 48 ms)
- **fractionated late potentials** (96 ± 47 ms beyond QRS complex) clustering exclusively in the **anterior** aspect of the **RVOT** epicardium.
- Ablation :
 - VT /VF noninducible (7 of 9 patients [78%])
 - normalization of the Brugada ECG pattern in 89%
 - no recurrent VT /VF in all patients off medication during FU of 20 ± 6 months (except 1 patient on amiodarone).

Epicardial catheter ablation of ventricular arrhythmias over RVOT



Abnormal prolonged duration of the ventricular electrograms in the anterior RVOT (the purple = the longest duration (160 ms) during SR, left).

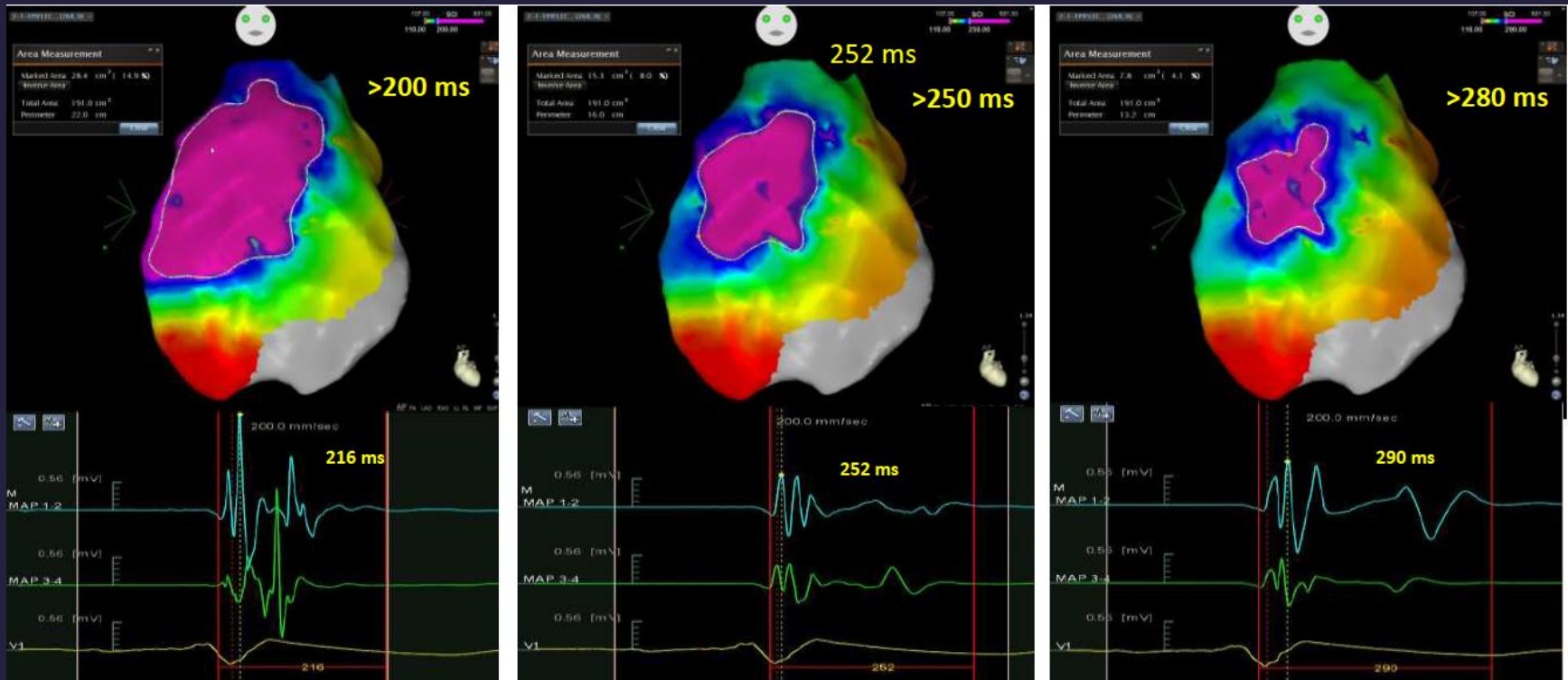
The voltage map, shown in the middle, low voltage in red and high voltage in purple.



C. Pappone and J. Brugada et al.

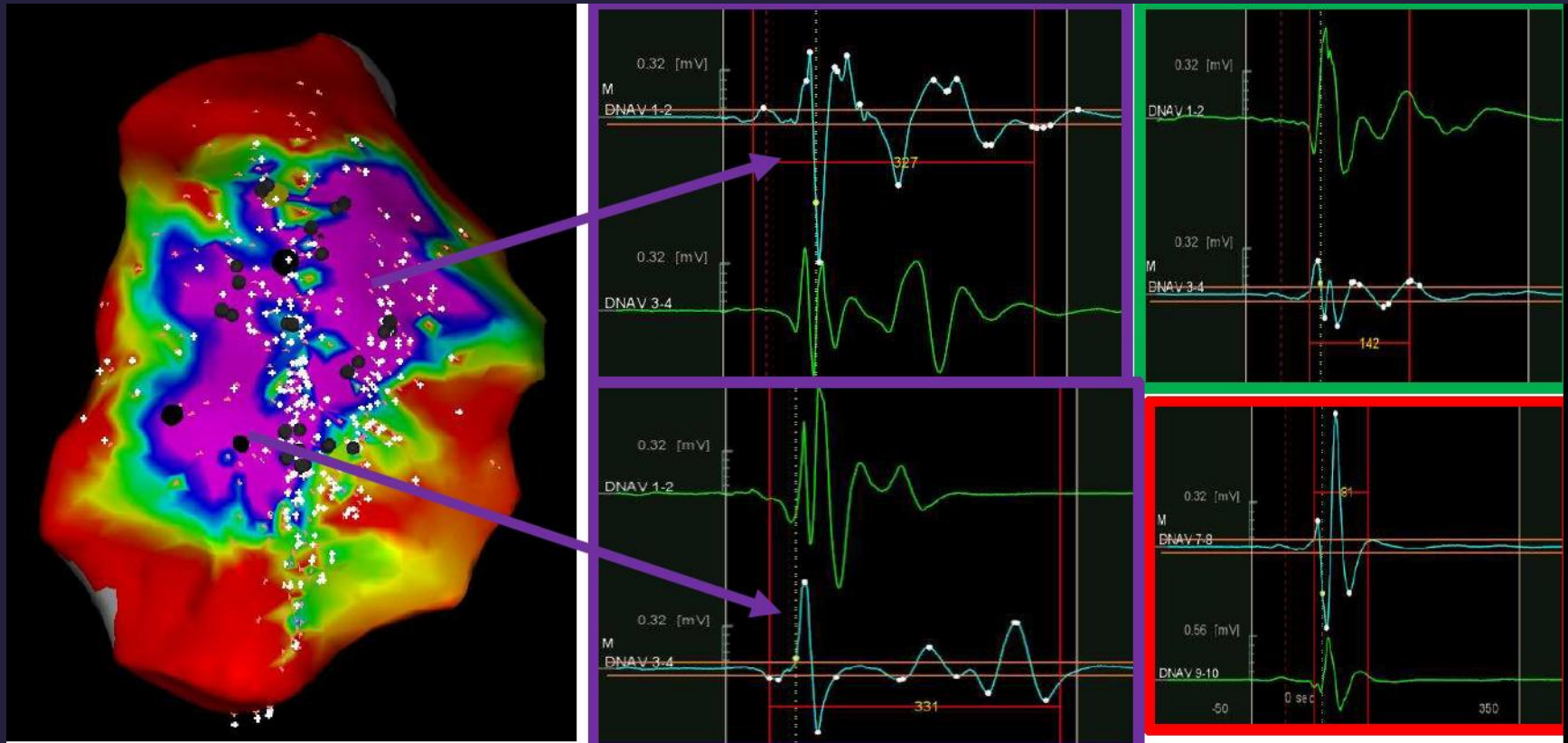
- 14 patients were enrolled (ICD was implanted in all patients)
- target: fragmented and delayed potentials and low voltage areas in basal condition and after flecainide test
- In 14/14 pts Brugada pattern disappeared immediately after the RFA.
- In 14/14 pts pharmacological test (flecainide or ajmaline) after RFA resulted negative
- In 14/14pts VT/VF was not inducible after RFA (EP Test up to three extrastimuli until refractoriness or to 200 msec)
- In 14/14pts during FU Brugada ECG pattern was not evident anymore in basal condition and after drug challenge
- In 14/14pts during FU no recorded VT/VF episodes

Potential duration map



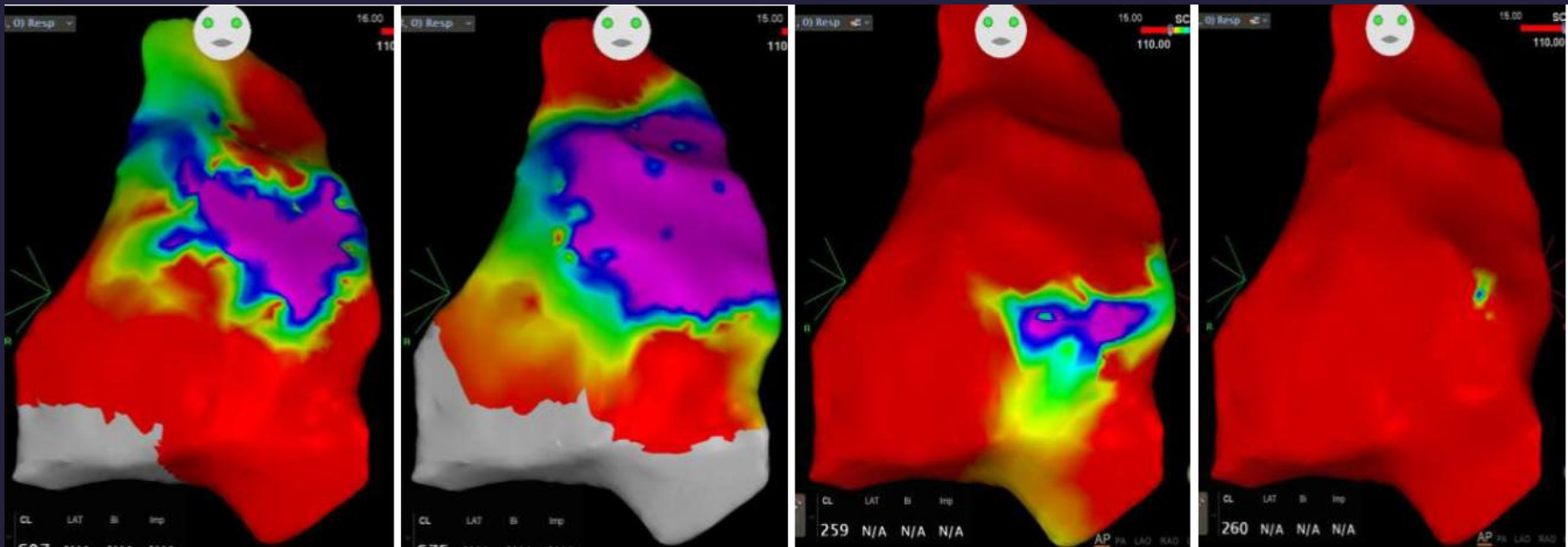

Brugada J et al. *Circ Arrhythm Electrophysiol* 2015;8:1373-81.
Pappone C et al. *Circ Arrhythm Electrophysiol* 2017;10:e00505.
Pappone C et al. *J Am Coll Cardiol* 2018;71:1631-46

Potential duration map and signal annotation



Brugada J et al. *Circ Arrhythm Electrophysiol* 2015;8:1373-81.
Pappone C et al. *Circ Arrhythm Electrophysiol* 2017;10:e00505.
Pappone C et al. *J Am Coll Cardiol* 2018;71:1631-46

Epicardial 3D maps of electrogram duration

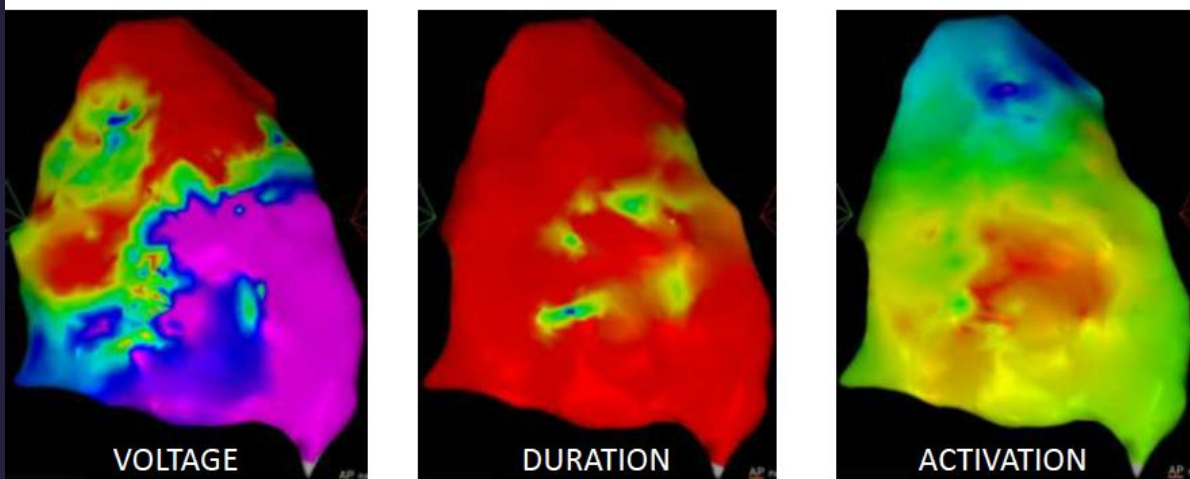
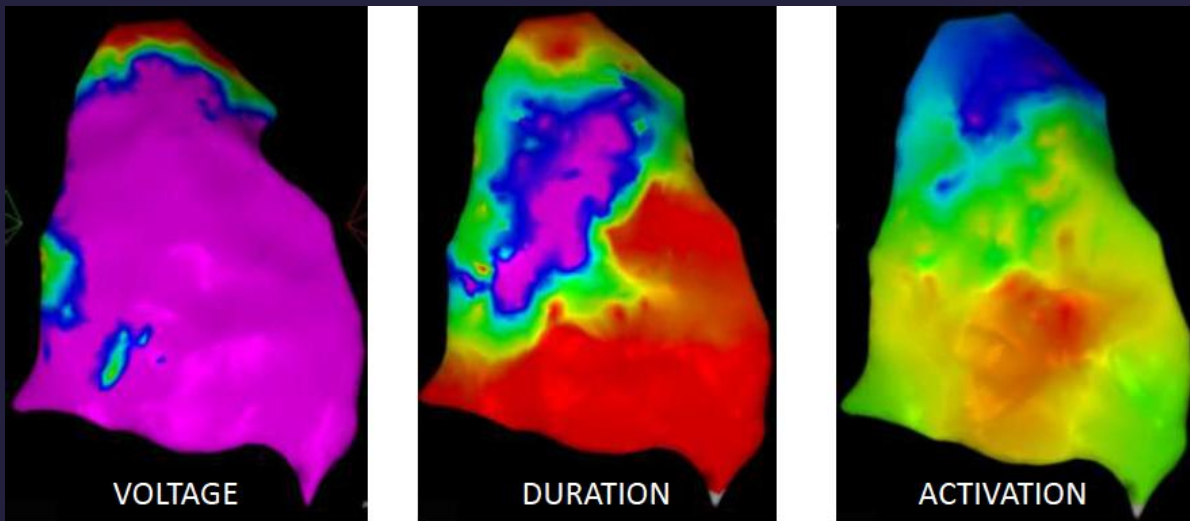


Basal

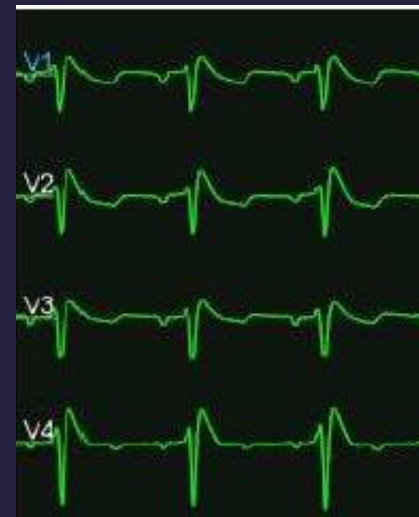Flecainide

Post RF1

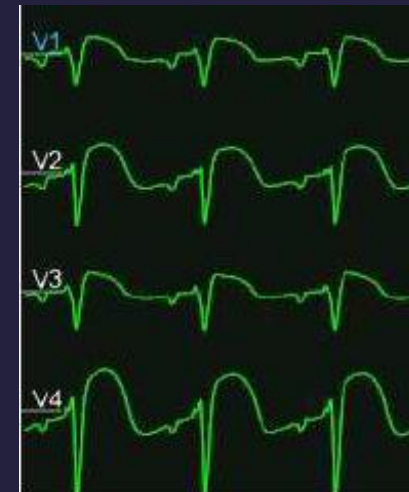Post RF2



basal



post RF

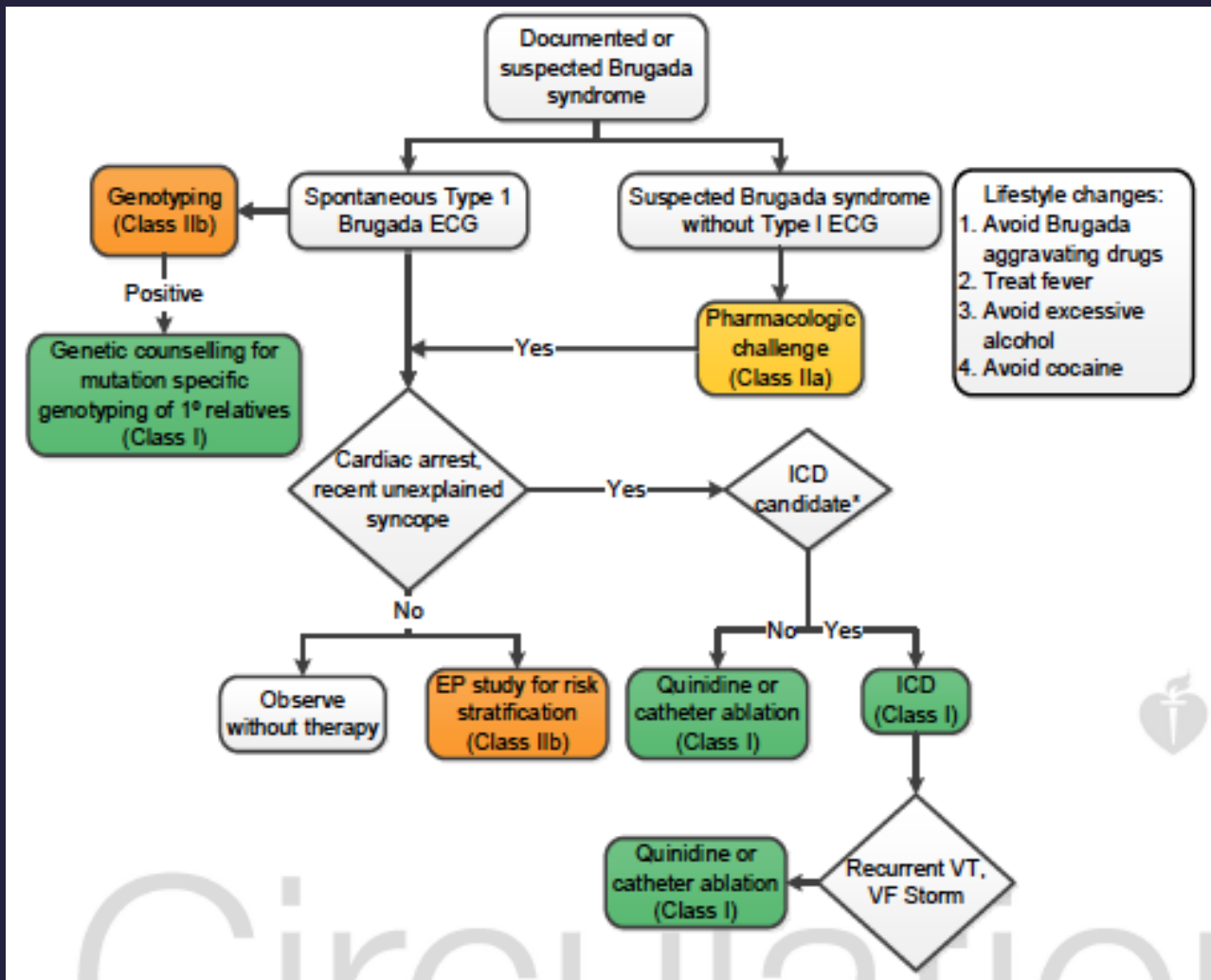


Brugada J et al. *Circ Arrhythm Electrophysiol* 2015;8:1373-81.
 Pappone C et al. *Circ Arrhythm Electrophysiol* 2017;10:e00505.
 Pappone C et al. *J Am Coll Cardiol* 2018;71:1631-46

Recommendations for Brugada Syndrome

COR	LOE	Recommendations
I	B-NR	3. In patients with Brugada syndrome experiencing recurrent ICD shocks for polymorphic VT, intensification of therapy with quinidine or catheter ablation is recommended (7-11).
I	B-NR	4. In patients with spontaneous type 1 Brugada electrocardiographic pattern and symptomatic VA who either are not candidates for or decline an ICD, quinidine or catheter ablation is recommended (7, 9-11).

Prevention of SCD in Patients With Brugada Syndrome



Geneticky podmienené primárne arytmičné syndrómy

- Podrobná osobná a rodinná anamnéza - synkopy/presynkopy, náhle úmrtia (typické situácie)....
- EKG → kľúčom a základným kameňom diagnózy
- Odporúčania úpravy životného štýlu
- Odoslanie do špecializovaného centra
- Špeciálne vyšetrenia (provokačné testy, EFV, genetika,...)
- Betablokátory, AA triedy I A, ICD,
- **katéetrová ablácia**

Ďakujem za pozornosť

hlivakp@gmail.com

Syndróm dlhého QT intervalu LQTS

Diagnóza LQTS :

1. V prípade ak je rizikové skóre LQTS > 3.5 pri absencii sekundárnej príčiny predĺženia QT intervalu
a/ alebo
2. V prípade jednoznačne patogénnej mutácie niektorého z LQTS génov
alebo
3. V prípade ak je opakovane $QT_c > 500$ ms na 12-zvodovom EKG pri absencii sekundárnej príčiny predĺženia QT intervalu

LQTS Diagnostické kritéria

TABLE 2. 1993 LQTS Diagnostic Criteria

	Points
ECG findings*	
A. QT _c †	
≥480 msec ^{1/2}	3
460-470 msec ^{1/2}	2
450 msec ^{1/2} (in males)	1
B. Torsade de pointes‡	2
C. T-Wave alternans	1
D. Notched T wave in three leads	1
E. Low heart rate for age§	0.5
Clinical history	
A. Syncope‡	
With stress	2
Without stress	1
B. Congenital deafness	0.5
Family history 	
A. Family members with definite LQTS#	1
B. Unexplained sudden cardiac death below age 30 among immediate family members	0.5

LQTS, long QT syndrome.

*In the absence of medications or disorders known to affect these electrocardiographic features.

†QT_c calculated by Bazett's formula, where $QT_c = QT / \sqrt{RR}$.

‡Mutually exclusive.

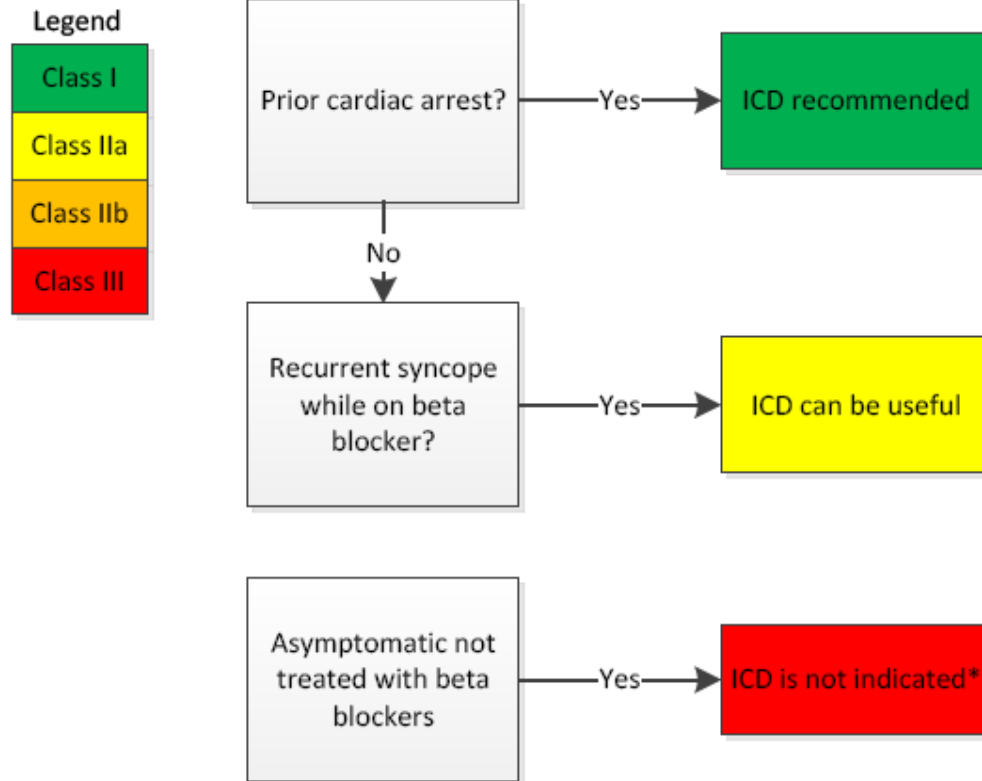
§Resting heart rate below the second percentile for age.²⁵

||The same family member cannot be counted in A and B.

#Definite LQTS is defined by an LQTS score ≥4.

Scoring: ≤1 point, low probability of LQTS; 2 to 3 points, intermediate probability of LQTS; ≥4 points, high probability of LQTS.

ICD pri syndrôme LQT



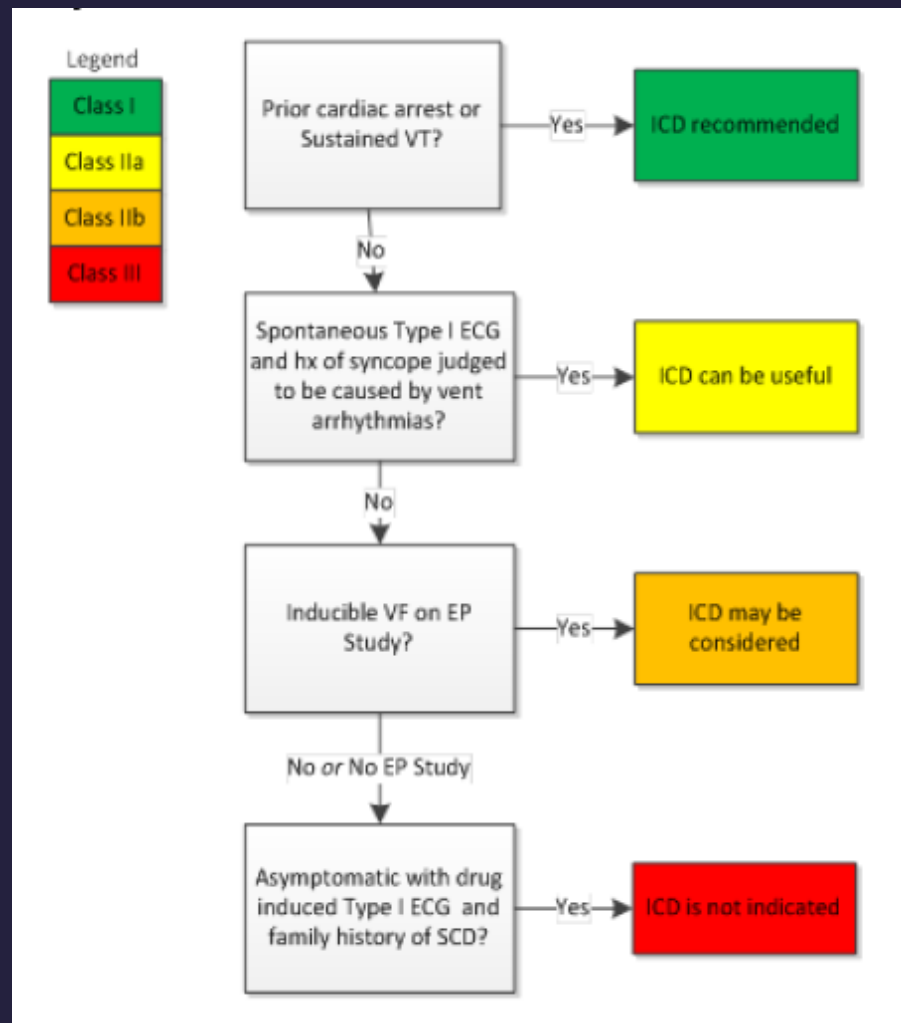
*Except under special circumstances, ICD implantation is not indicated in asymptomatic patients who have not been tried on beta-blocker therapy

Brugadov syndróm (BrS)

BrS je diagnostikovaný

- U pacientov s eleváciou ST segmentu morfológie typu 1 s eleváciou > 2 mm v ≥ 1 zvode v pravých prekordiálnych zvodoch V1, V2, ktoré sú naložené v 2., 3. alebo 4. medzirebrovom priestore, pričom elevácia sa môže vyskytovať spontánne *alebo* sa môže objaviť po provokatívnom teste i.v. antiarytmikami triedy I
- U pacientov s eleváciou ST segmentu s morfológiou typu 2 alebo 3 vo > 1 prekordiálnom zvode V1, V2, ktoré sú naložené v 2., 3. alebo 4. medzirebrovom priestore, v prípade ak provokatívny test i.v. antiarytmikami triedy I indukuje typ 1 EKG morfológiu

ICD pri syndróme Brugada



Brugadov syndróm (BrS) - ICD

- V súčasnosti jediná dokázaná účinná terapeutická stratégia v prevencii NKS
- Nevýhody ICD
 - Aktívni mladí ľudia vyžadujú mnohopočetnú výmenu ICD
 - Nízke percento adekvátnych výbojov (8-15%, medián sledovania 45 mes.) a vysoké percento komplikácií, hlavne neadekvátnych výbojov (20-36% v 21-47 mesačnom sledovaní) ^{1,2,3}
- U asymptomatických pacientov s BrS nie je vzhľadom na veľmi nízke riziko život-ohrozujúcej príhody implantácia ICD indikovaná⁴