
Co musíte znát k praktické části atestační zkoušky? ECHOKARDIOGRAFIE

Martin Hutyra

1. interní klinika – kardiologická, Lékařská fakulta Univerzity Palackého a Fakultní nemocnice Olomouc

XXV. výroční sjezd ČKS

10. květen 2012



17:00-18:30 **Imaging pro mladé kardiology**
Předsedající: A. Linhart, M. Pazderník (Praha)

17:00 278. **ECHOKVÍZ**
J. Pudich (Ostrava)

17:28 **Diskuze**

17:30 279. **ZÁKLADY ECHOKARDIOGRAFIE KE KARDIOLOGICKÉ
ATESTACI**
J. Marek (Praha)

17:58 **Diskuze**

18:00 280. **ZOBRAZOVACÍ METODY V AKUTNÍ KARDIOLOGII**
M. Kotrč (Praha)

18:28 **Diskuze**

Echokardiografie před atestací Kurz pro neplavce II

MUDr. Josef Marek



Echokardiografie před atestací Kurz pro neplavce I - PLAX

MUDr. Josef Marek

**II. interní klinika
kardiologie a angiologie**
**Komplexní
kardiovaskulární centrum**
VFN a 1. LF UK
Praha



**II. interní klinika
kardiologie a angiologie**
**Komplexní
kardiovaskulární centrum**
VFN a 1. LF UK
Praha



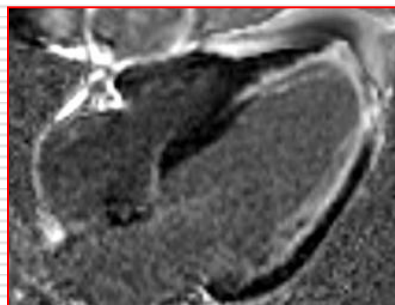
Zobrazovací metody srdce

Echokardiografie

- Dobutaminová zátěžová, deformace myokardu LK...

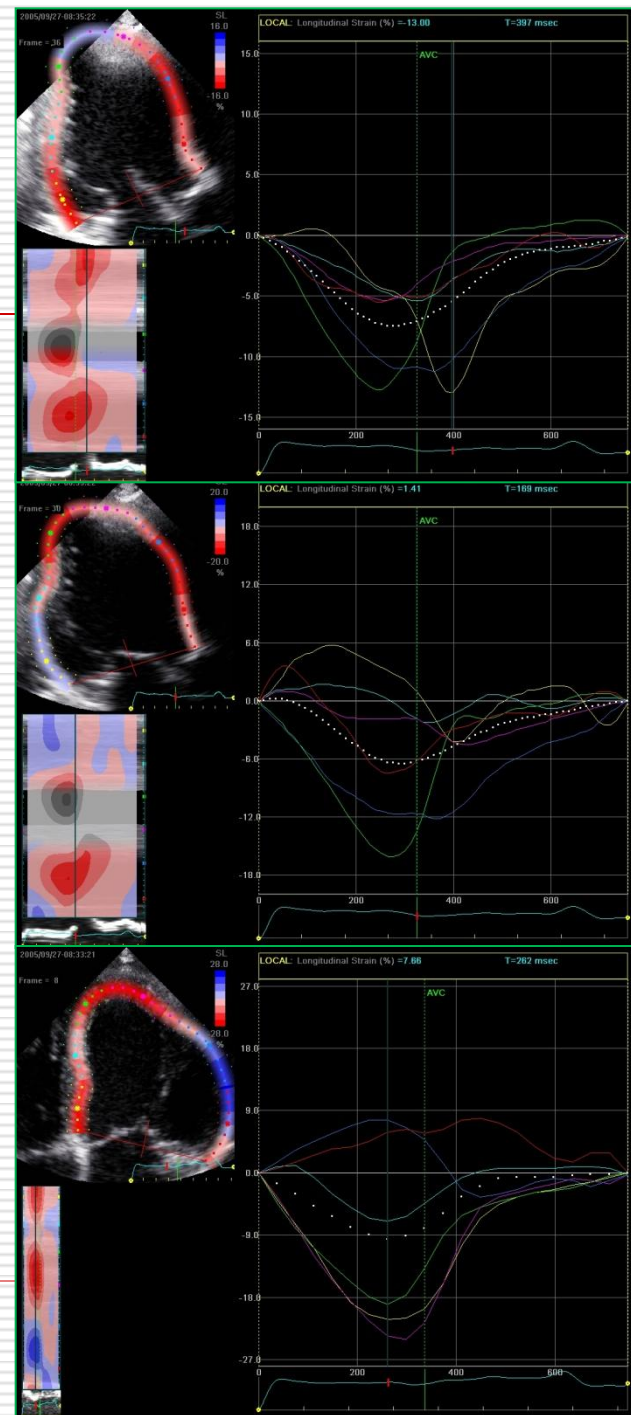
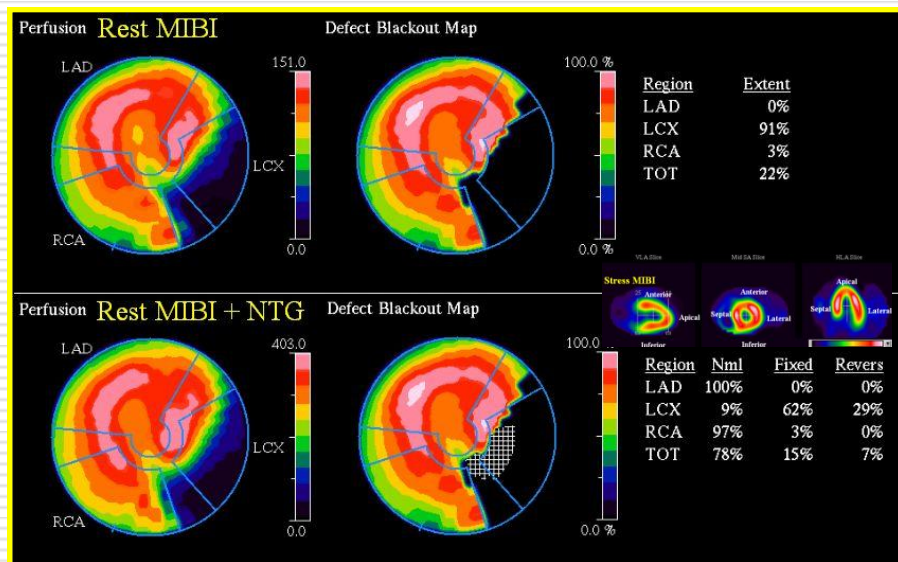
Magnetická rezonance

- T1, T2, LGE...



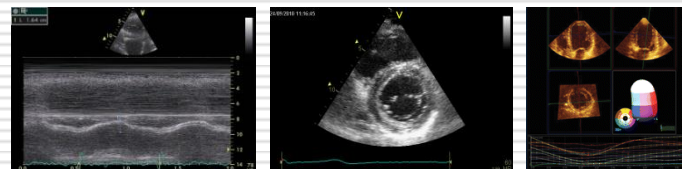
SPECT a PET myokardu

- Perfuzní scintigrafie myokardu
- metabolismmus

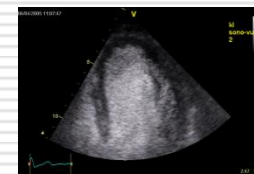

Echokardiografie - metody

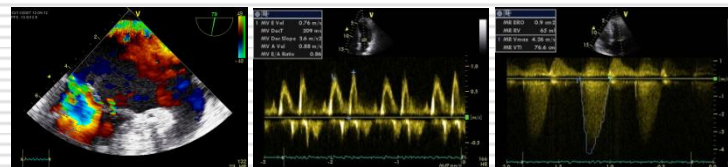
- **MM/2DE/RT 3DE**



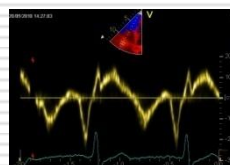
- **CEE**



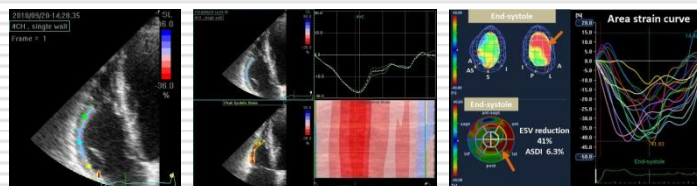
- **Doppler (CFM, PWD, CWD)**



- **Tissue Doppler imaging**



- **2D/3D strain**



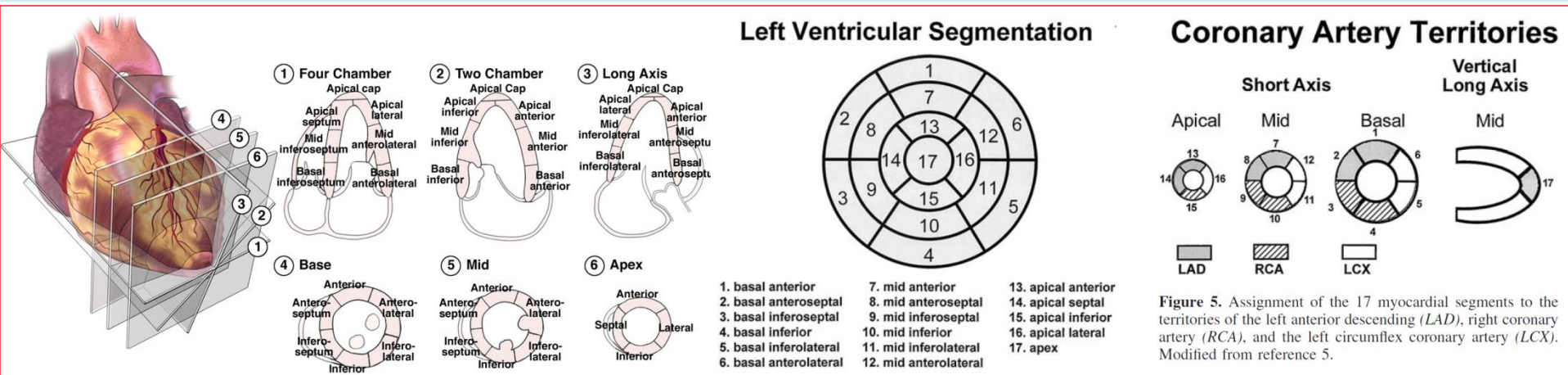


Standardized myocardial segmentation and nomenclature for tomographic imaging of the heart: A statement for healthcare professionals from the Cardiac Imaging Committee of the Council on Clinical Cardiology of the American Heart Association

Recommendations for chamber quantification ☆

Roberto M. Lang, Michelle Bierig, Richard B. Devereux, Frank A. Flachskampf*, Elyse Foster, Patricia A. Pellikka, Michael H. Picard, Mary J. Roman, James Seward, Jack Shanewise, Scott Solomon, Kirk T. Spencer, Martin St. John Sutton, William Stewart

Manuel D. Cerqueira, MD,^b Neil J. Weissman, MD,^a Vasken Dilsizian, MD,^b Alice K. Jacobs, MD,^d Sanjiv Kaul, MD,^a Warren K. Laskey, MD,^d Dudley J. Pennell, MD,^e John A. Rumberger, MD,^c Thomas Ryan, MD,^a Mario S. Verani, MDH^{†,b} and American Heart Association Writing Group on Myocardial Segmentation and Registration for Cardiac Imaging^{a,b,c,d,e}

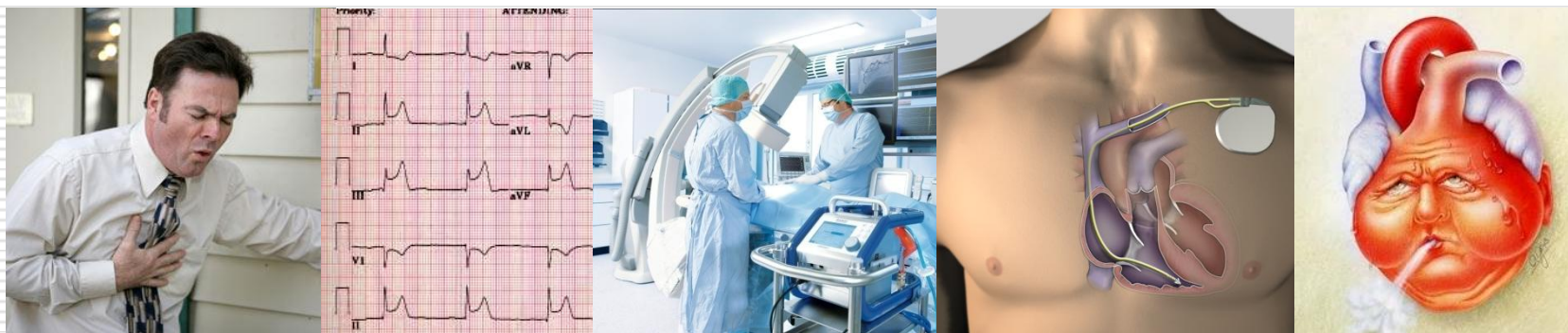



ESC Guidelines for the management of acute myocardial infarction in patients presenting with ST-segment elevation

The Task Force on the management of ST-segment elevation acute myocardial infarction of the European Society of Cardiology (ESC)

Kdy, komu a proč?



Hospitalizace - přijetí

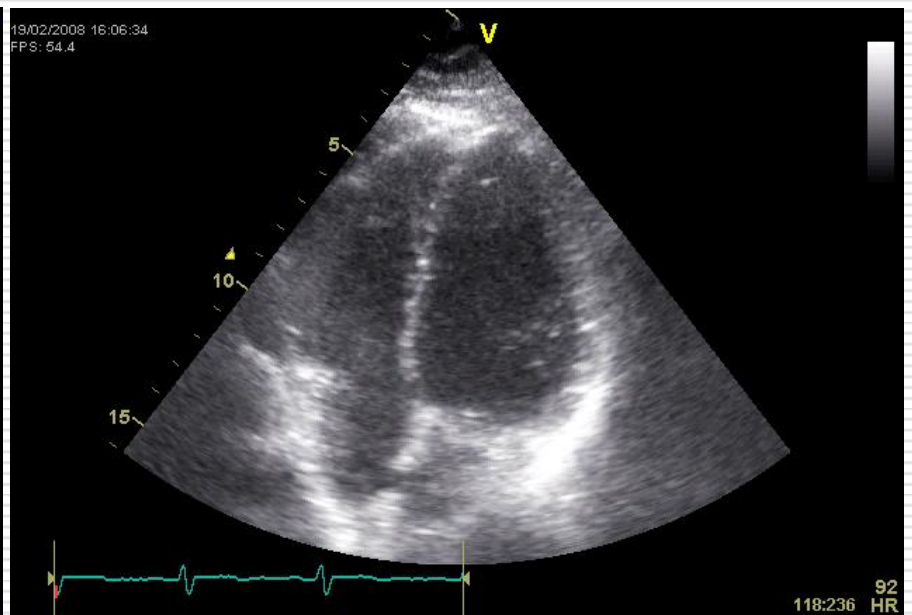
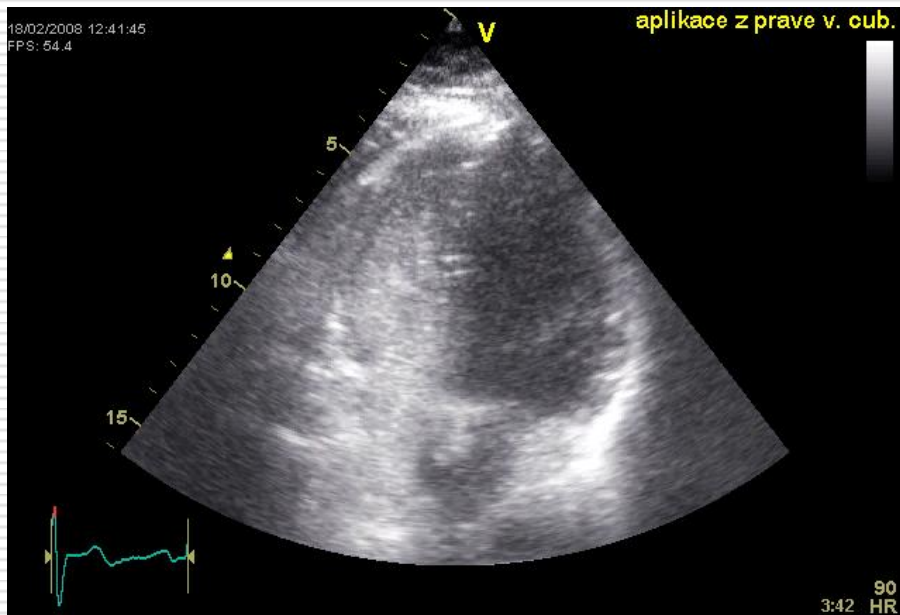
- dimise ...

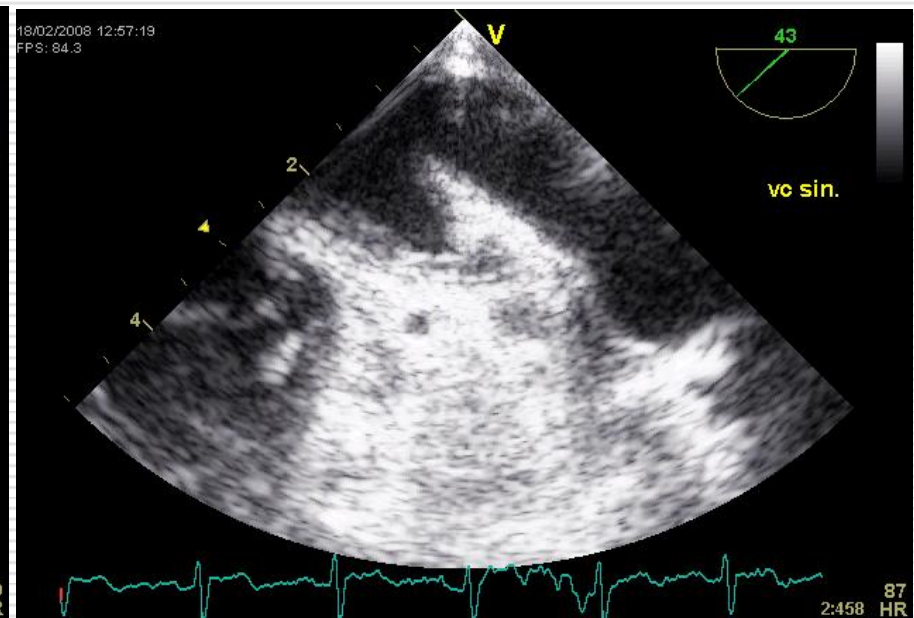
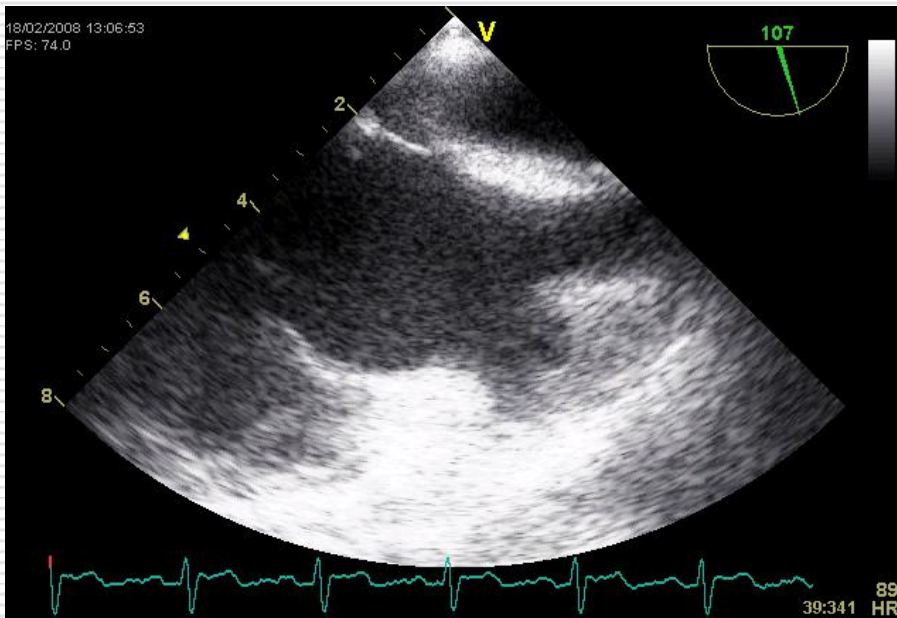
40. den od vzniku IM

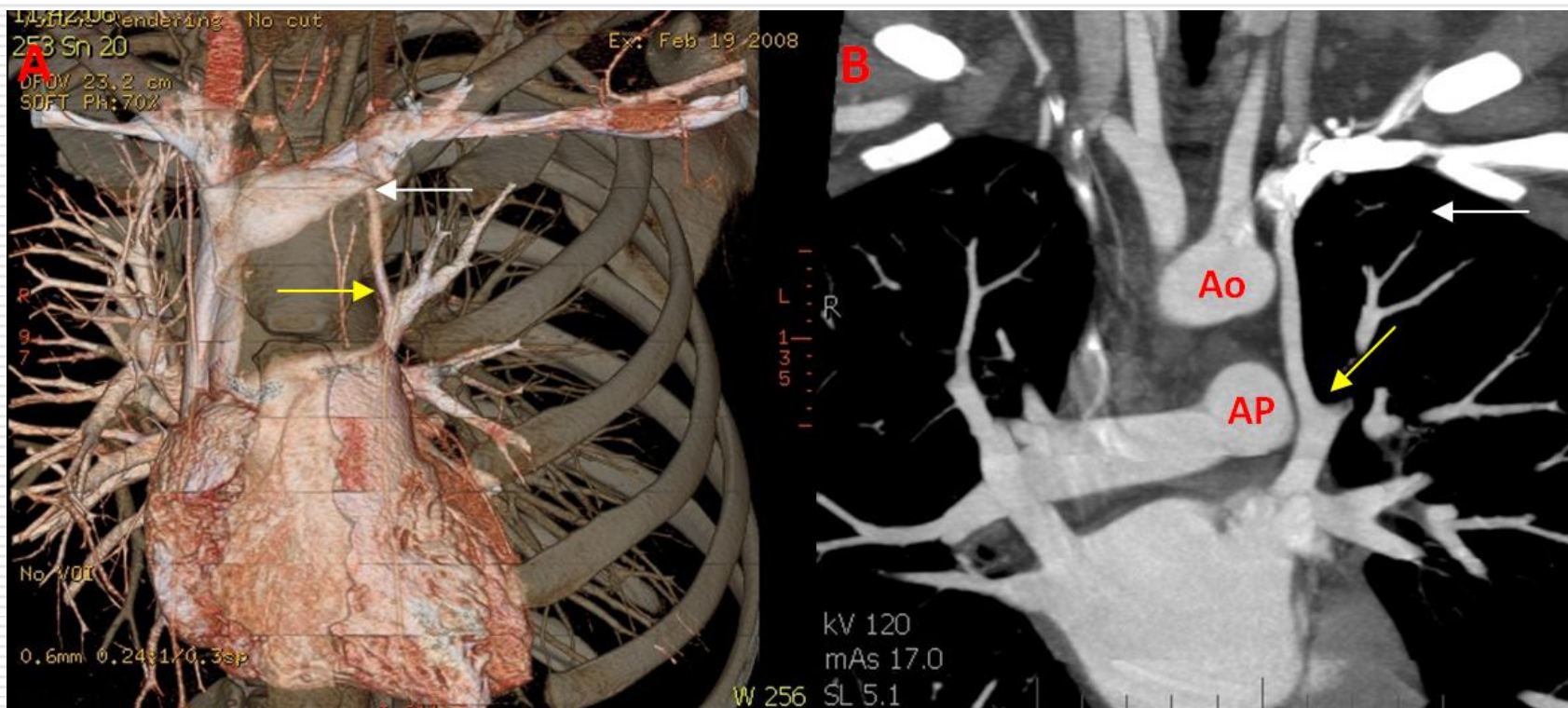
	At presentation	Within 48 h	Before or after discharge	Recommendations	Class ^a	Level ^b
Echo at rest	If required for diagnosis	For LV function and presence of thrombus	For LV function, heart failure, shock, or new murmur	In the acute phase, when diagnosis is uncertain, emergency echocardiography may be useful. However, if inconclusive or unavailable and persistent doubt, emergency angiography should be considered.	I	C
Stress ECG			For ischaemia	After the acute phase		
Stress perfusion SPECT			For viability and ischaemia, infarct size	All patients should have an echocardiography for assessment of infarct size and resting LV function.	I	B
Stress echo			For viability and ischaemia	If echocardiography is not feasible, MRI may be used as an alternative.	IIb	C
PET (rest)			For viability	Before or after discharge		
MRI (rest, stress, contrast-enhanced)			For LV function, infarct size, viability, and ischaemia	For patients with multivessel disease, or in whom revascularization of other vessels is considered, stress testing or imaging (e.g. using stress myocardial perfusion scintigraphy, stress echocardiography, positron emission tomography or MRI) for ischaemia and viability is indicated.	I	A
				Computed tomography angiography has no role in the routine management of STEMI patients.	III	C

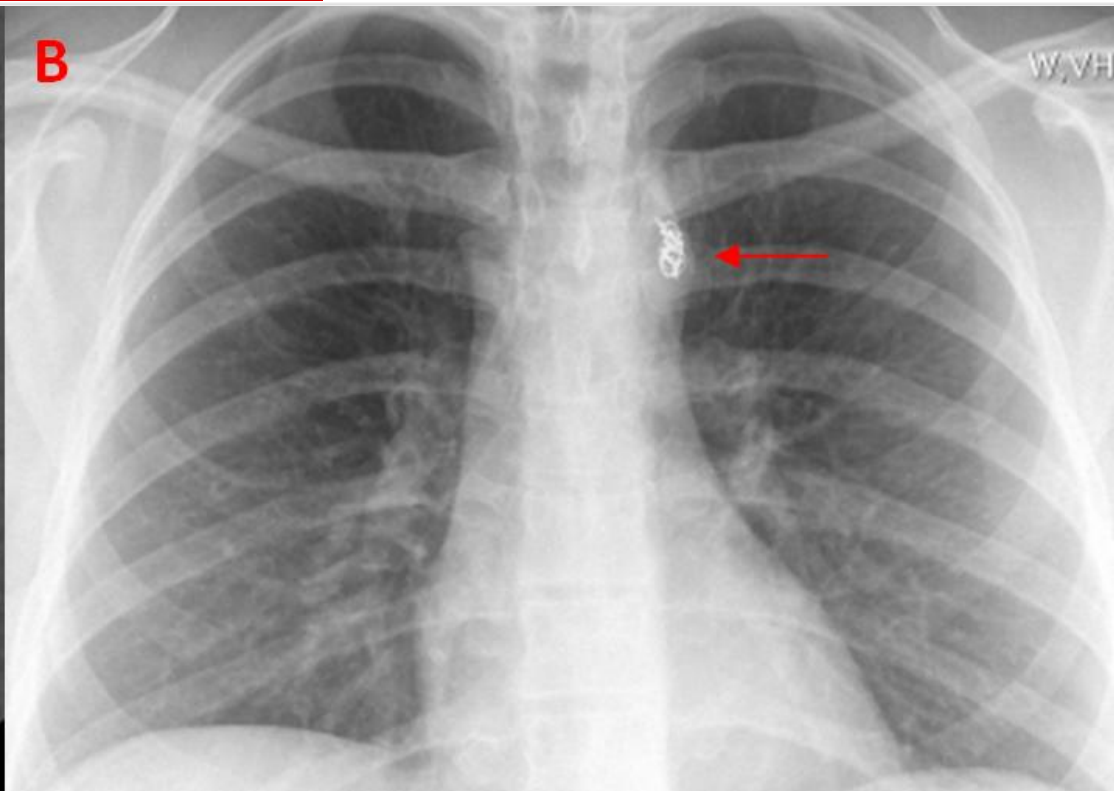
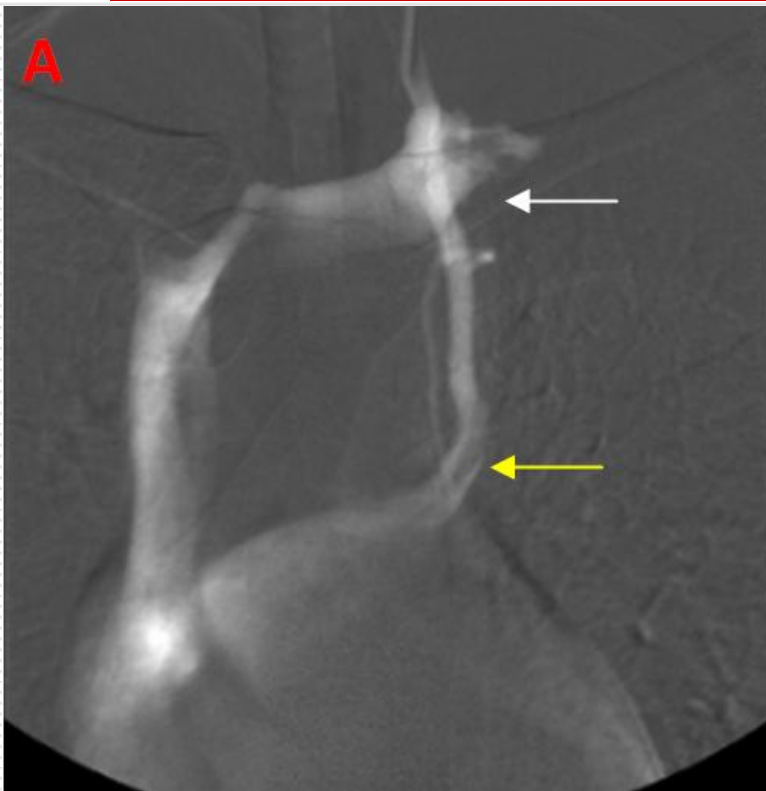
Van de Werf F. et al. Acute Myocardial Infarction in patients presenting with ST-segment elevation. EHJ 2008;29:2909-2945



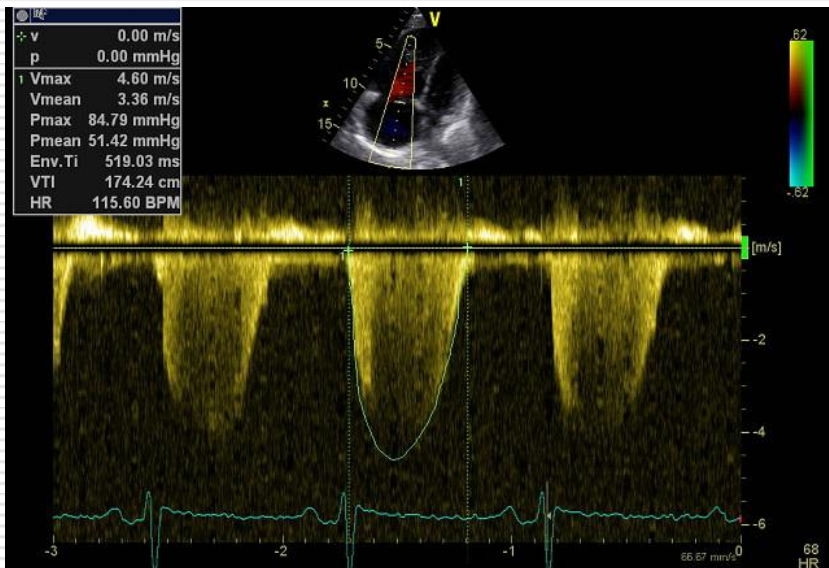
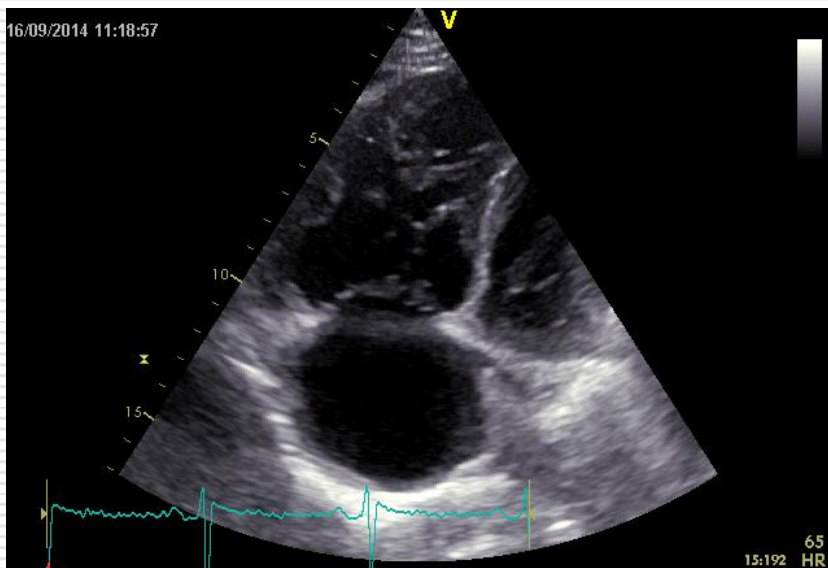
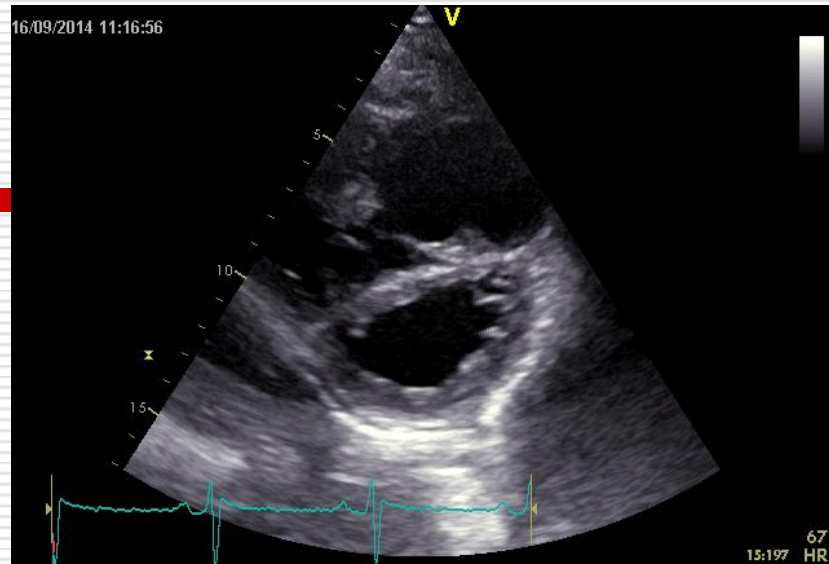
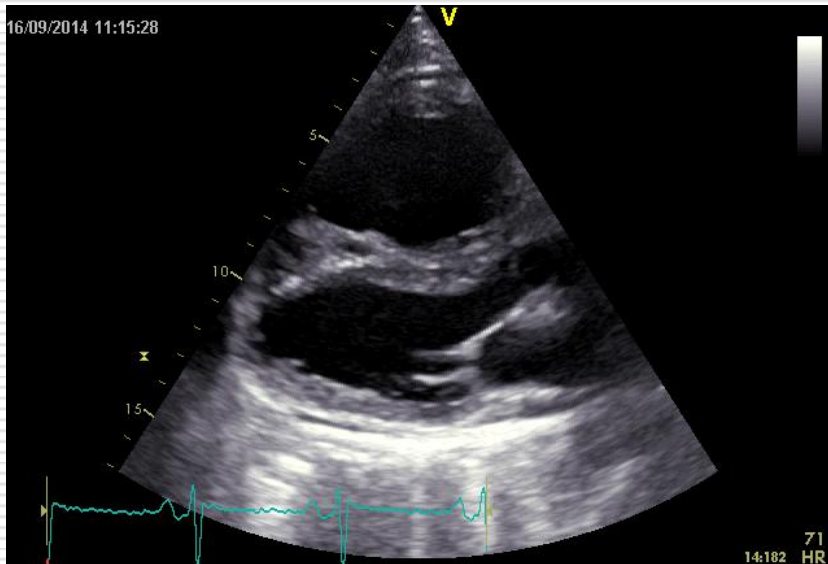


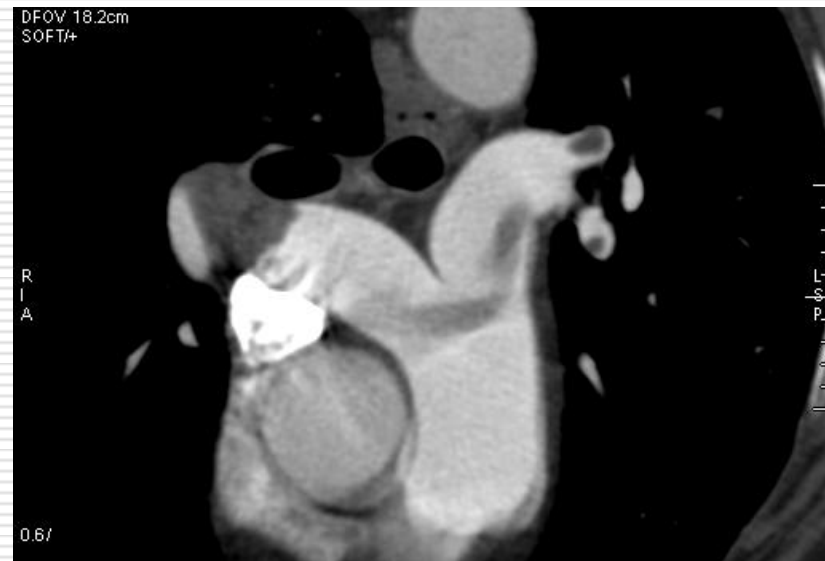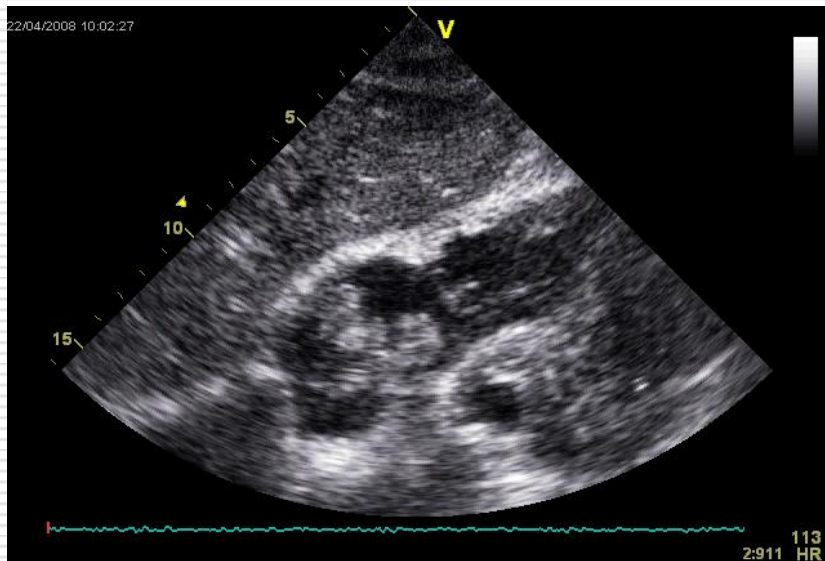
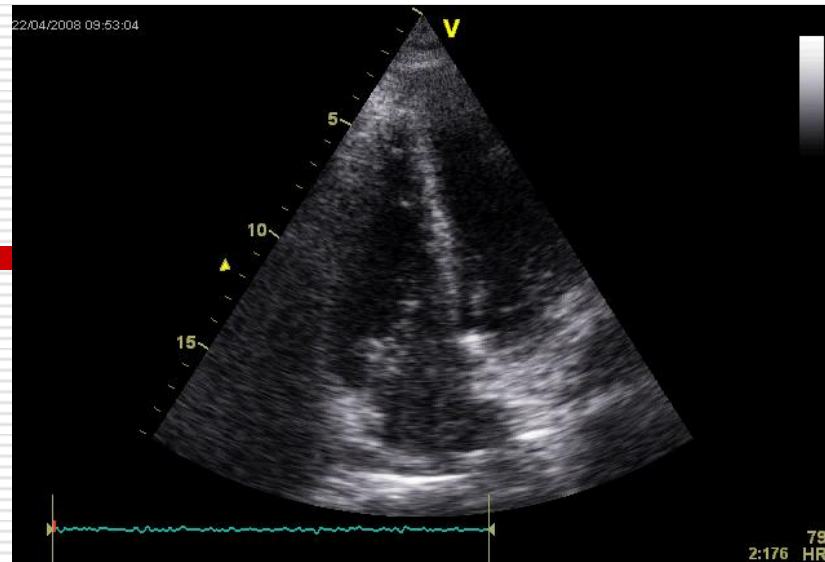
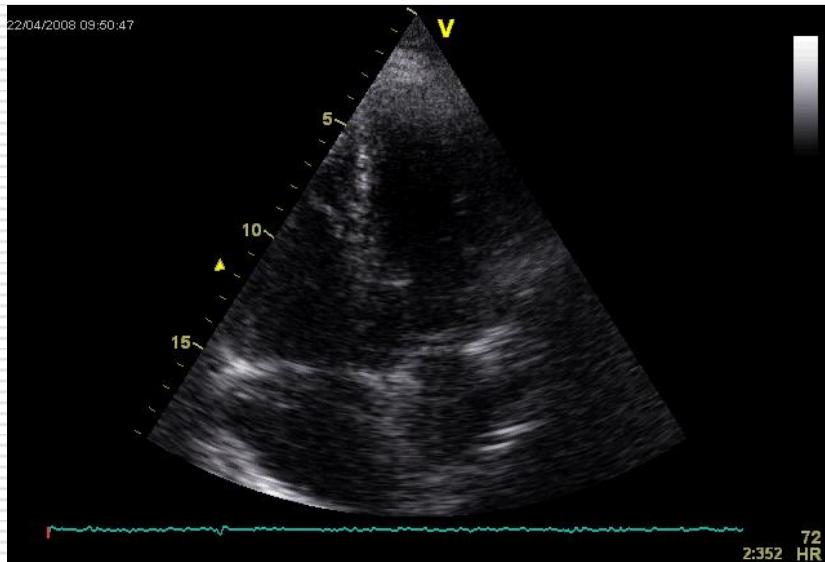


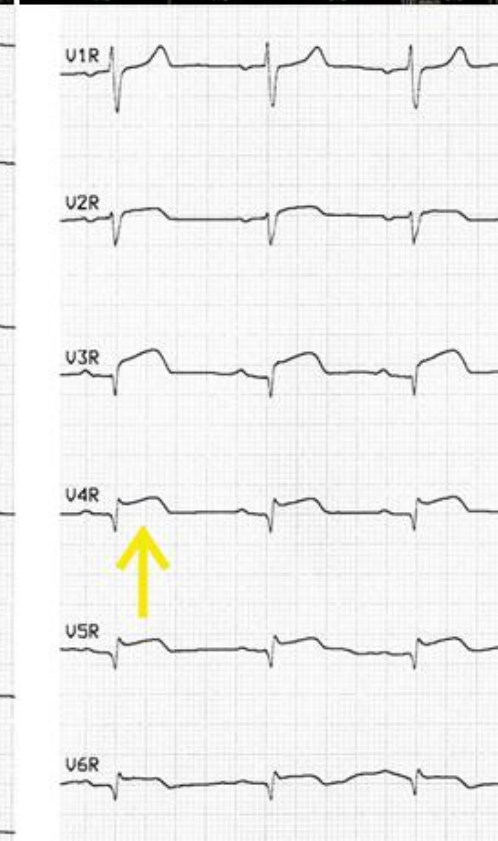
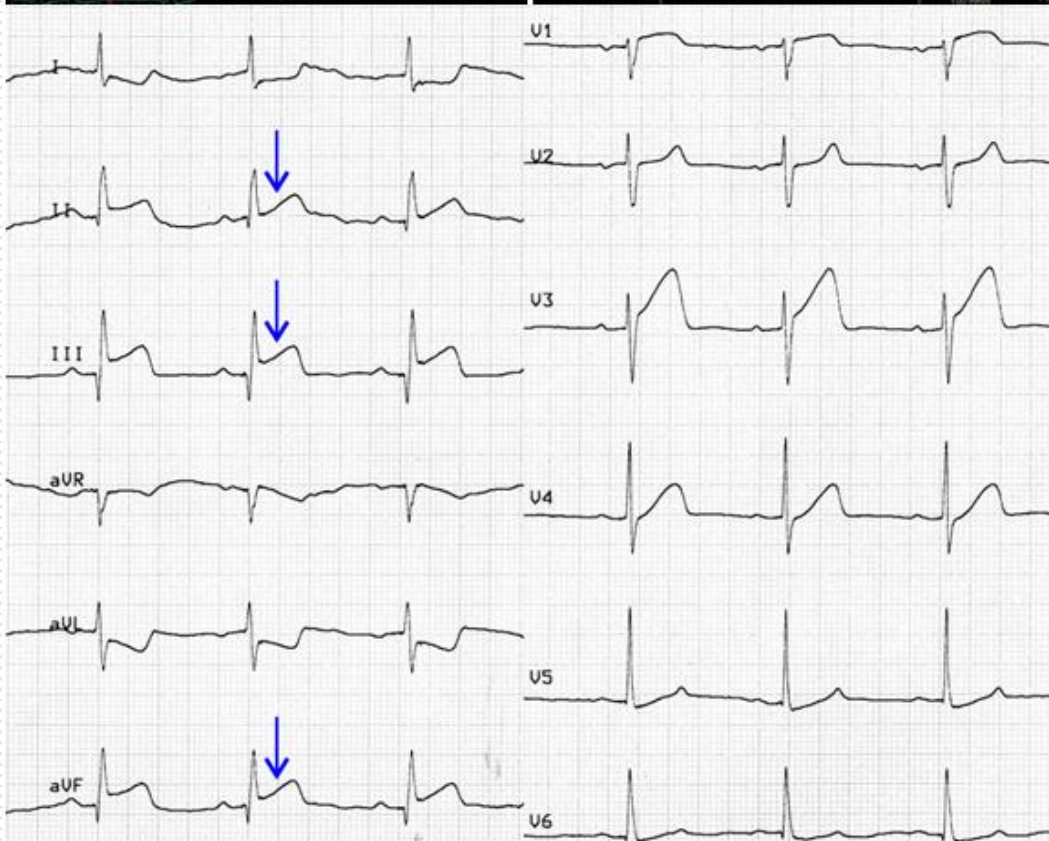
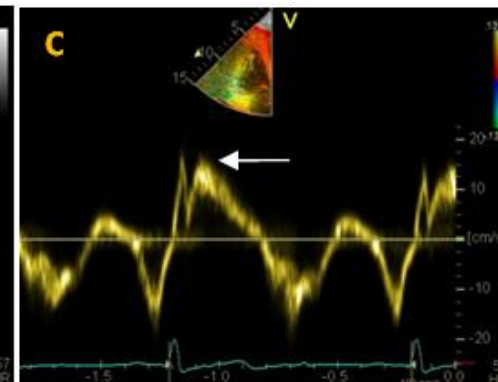
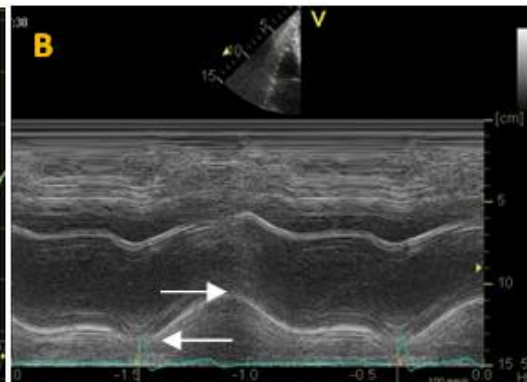
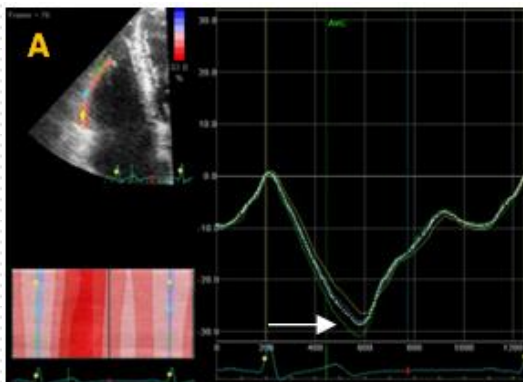




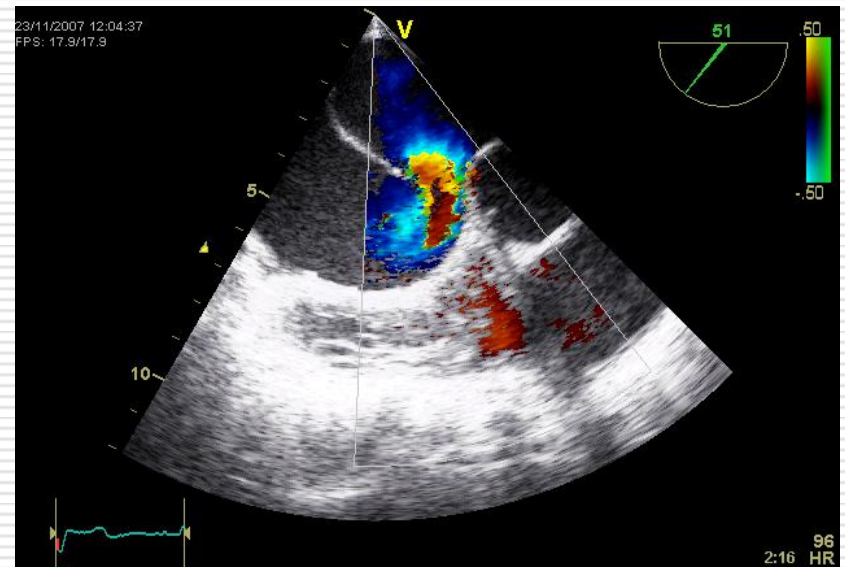

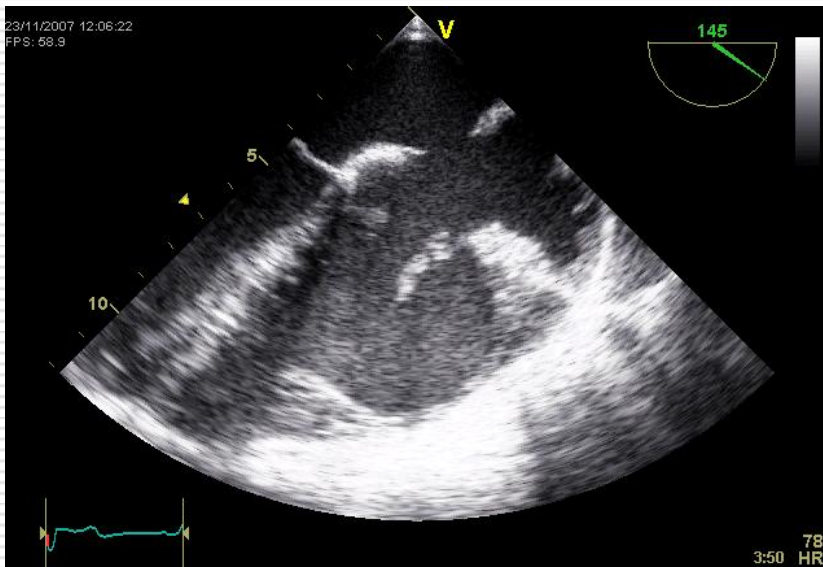
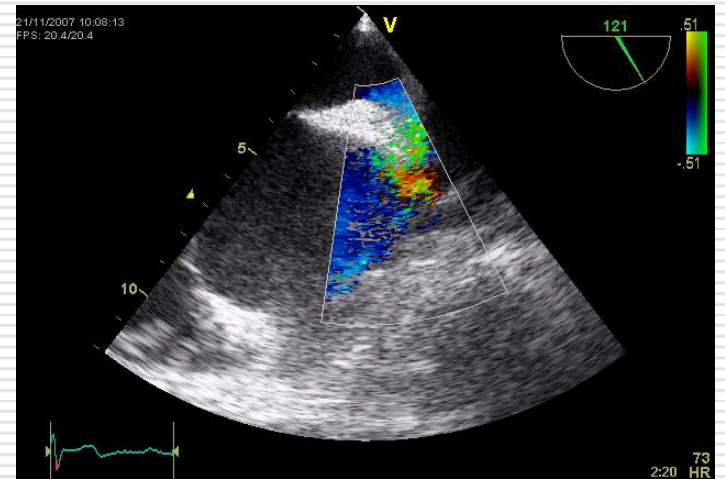
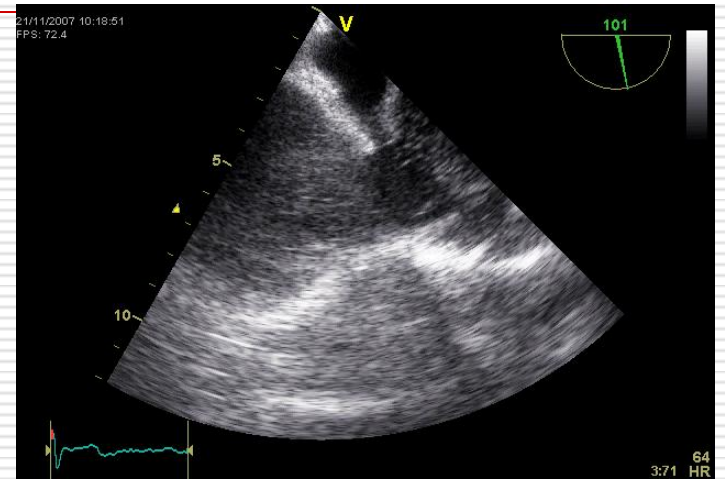
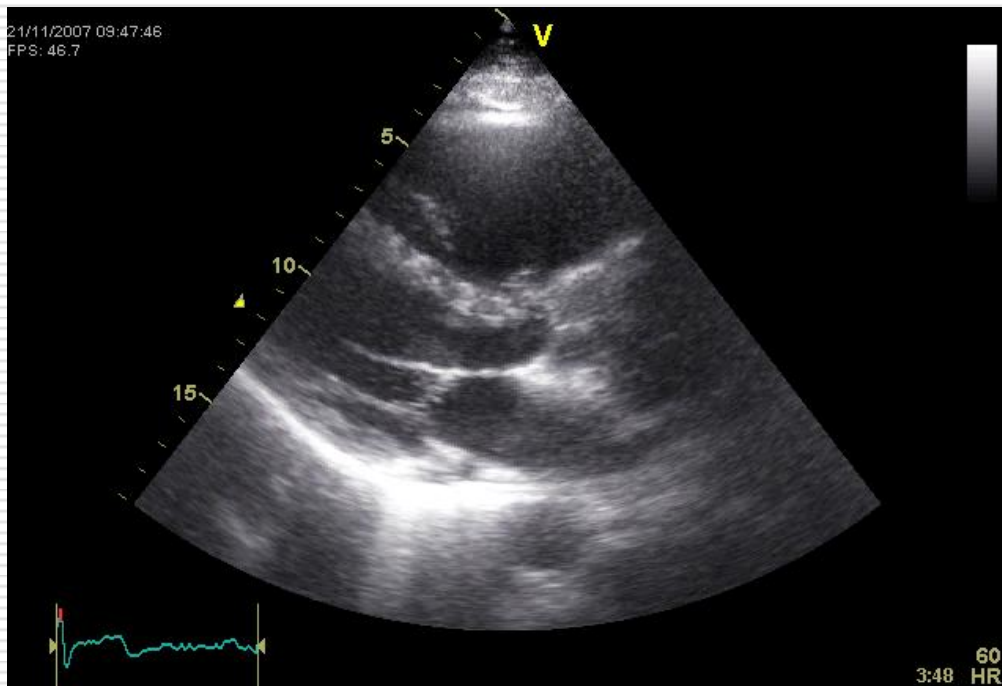


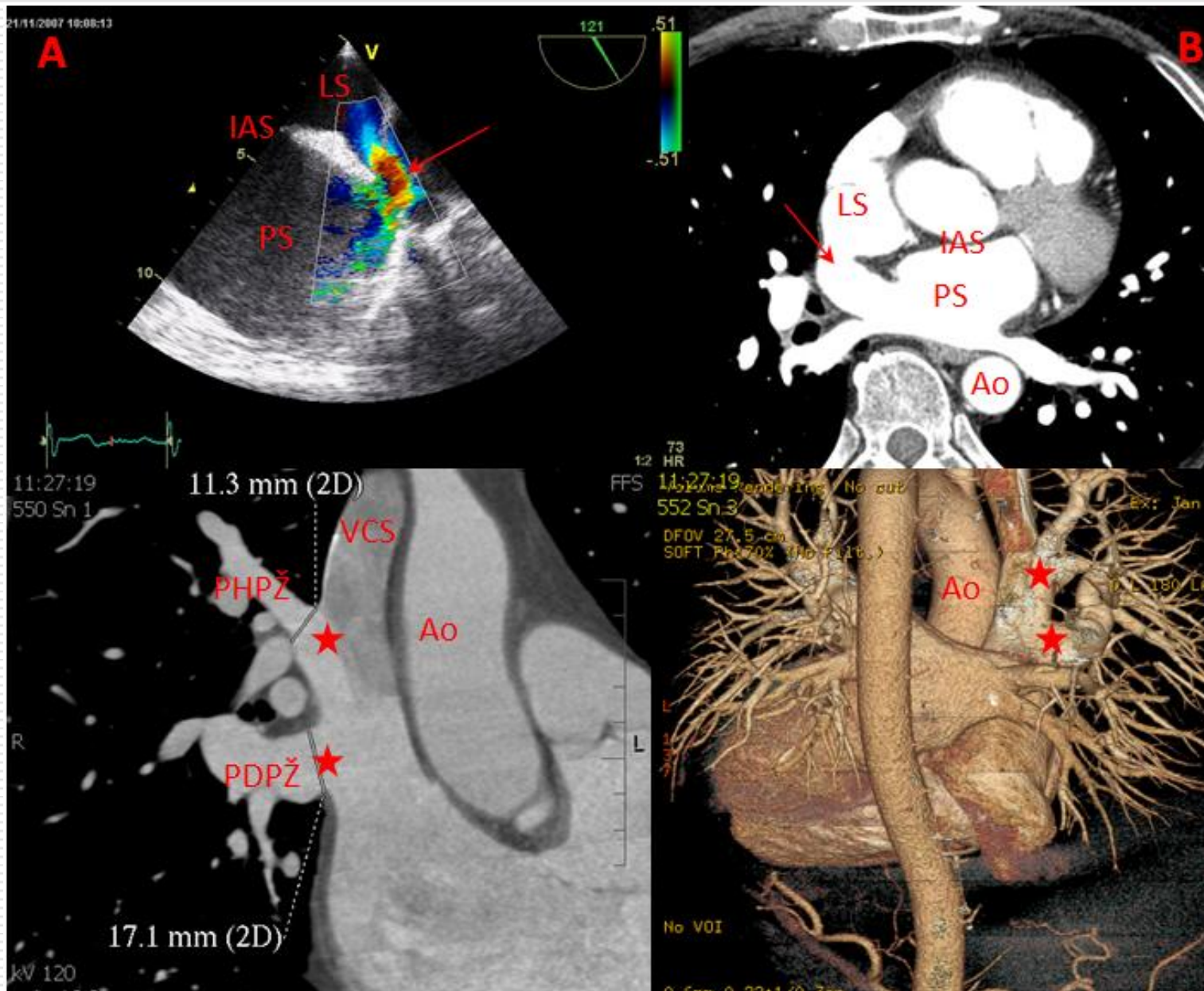




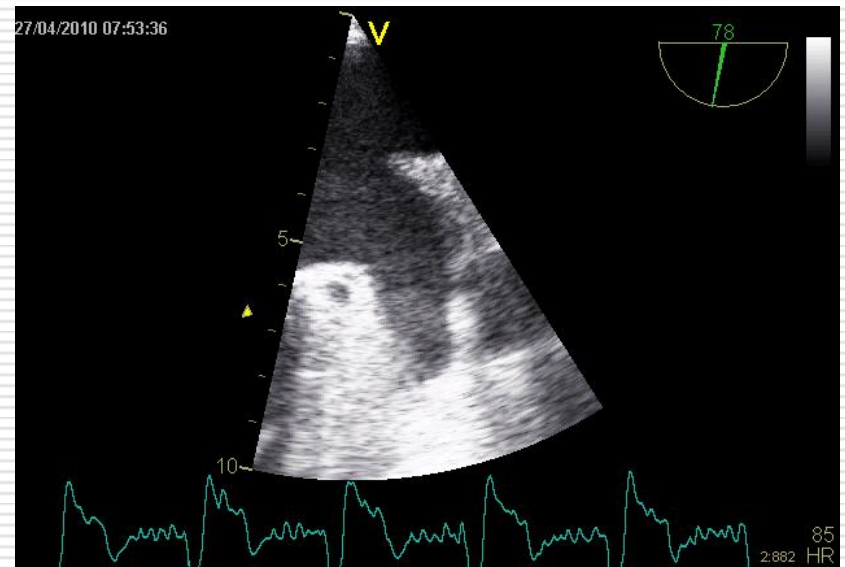
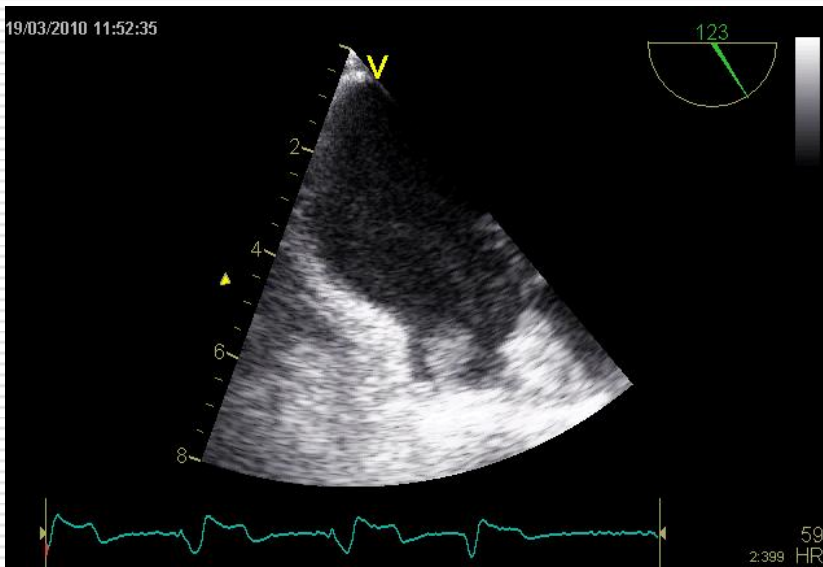






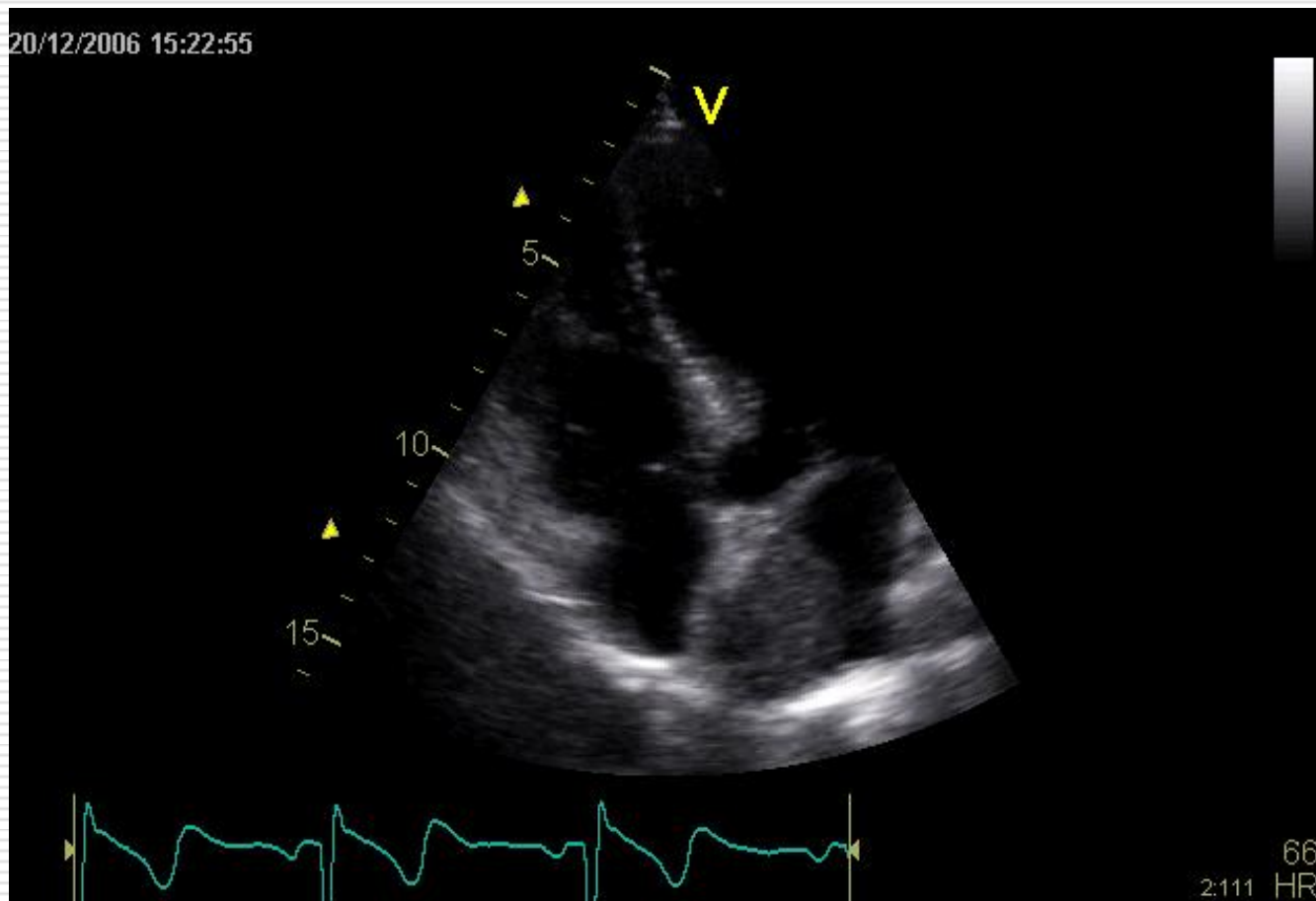




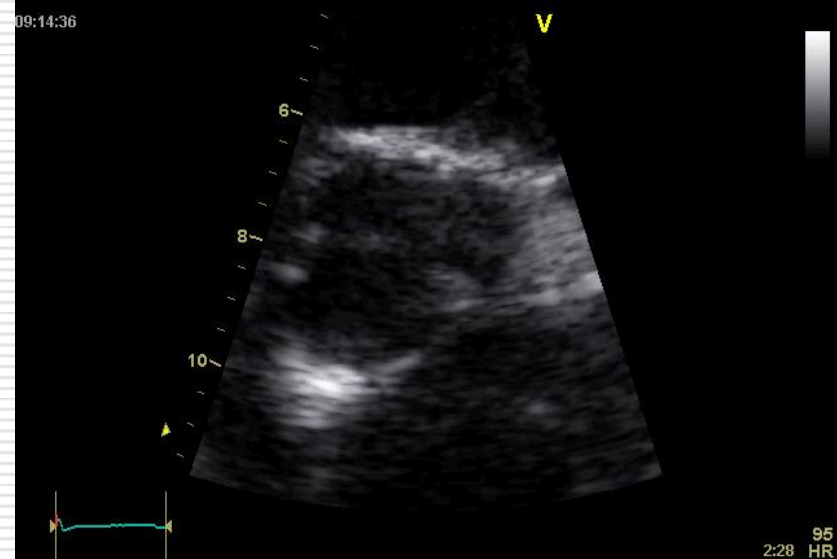
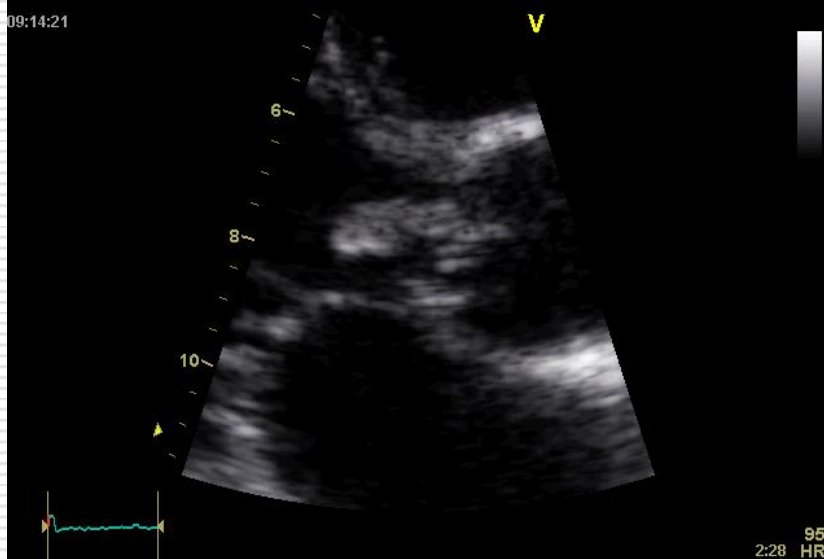
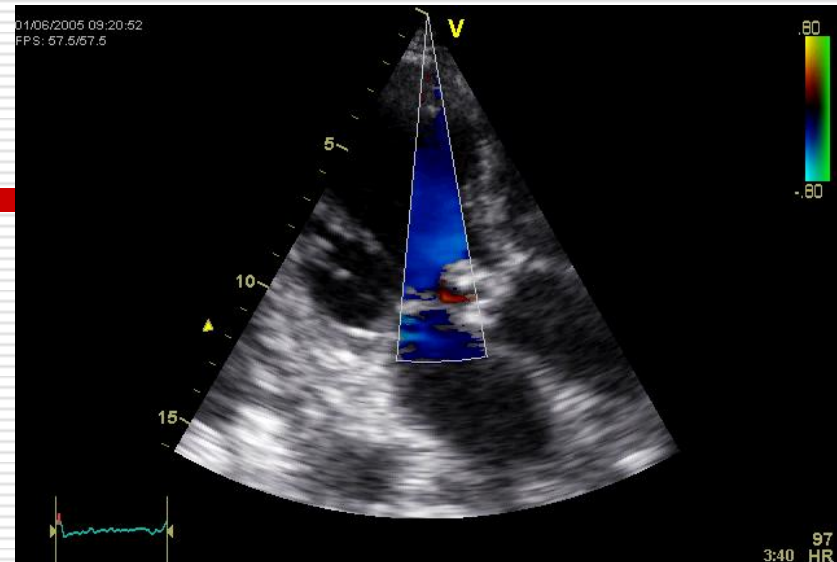
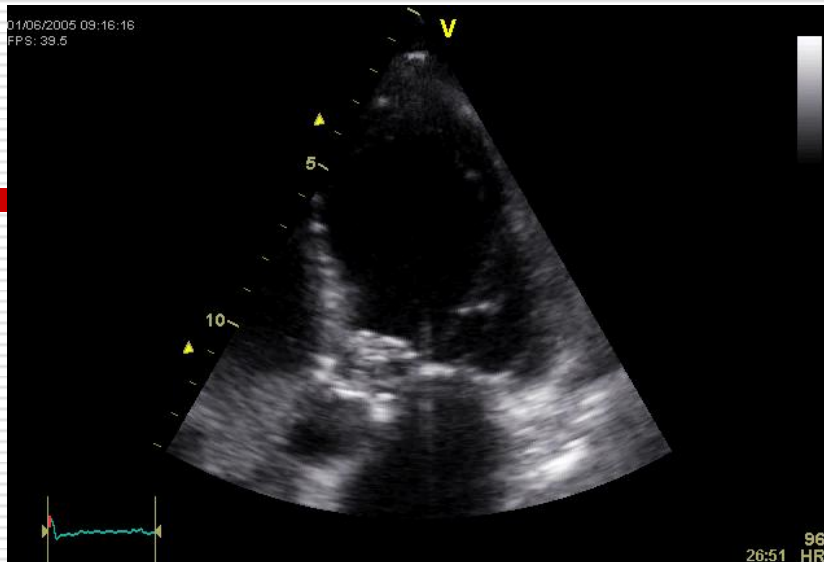




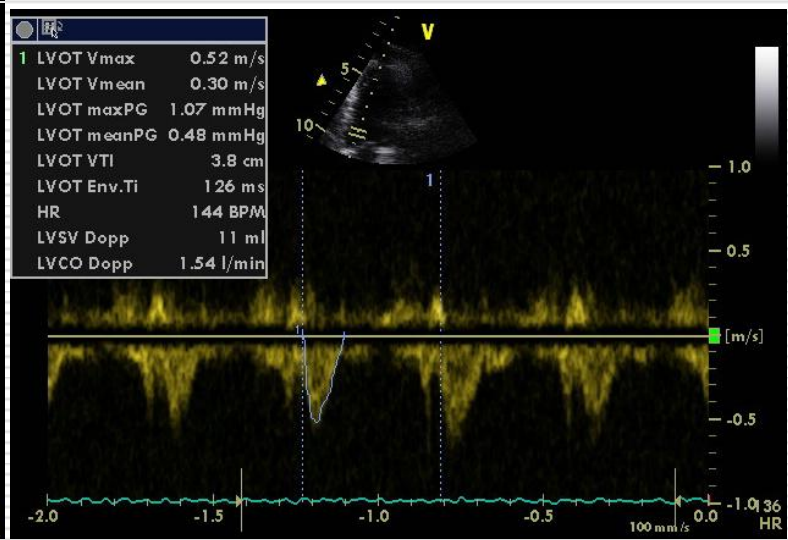
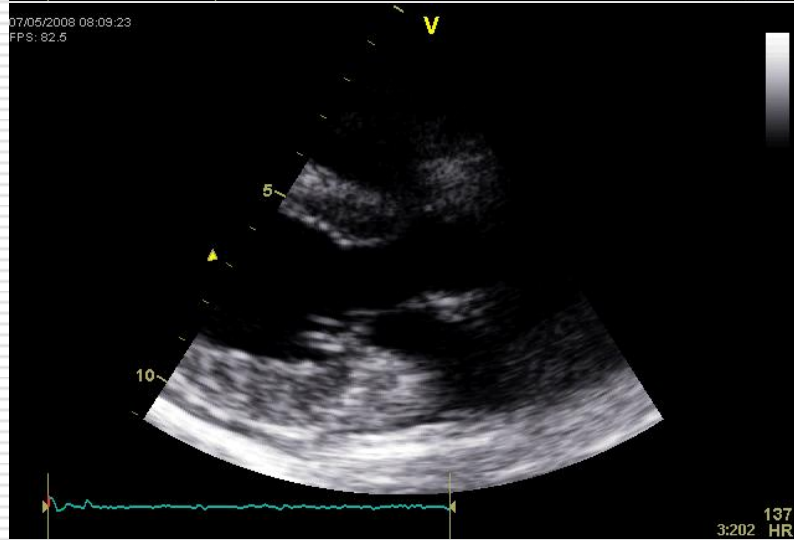
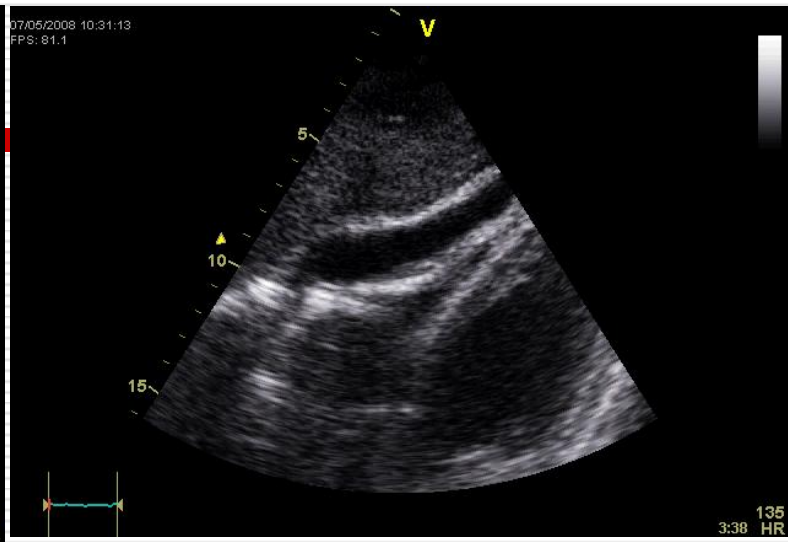
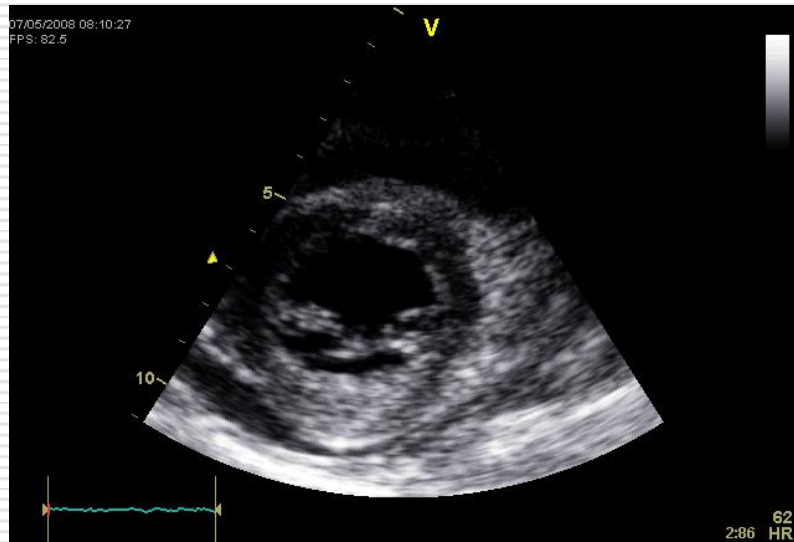
20/12/2006 15:22:55



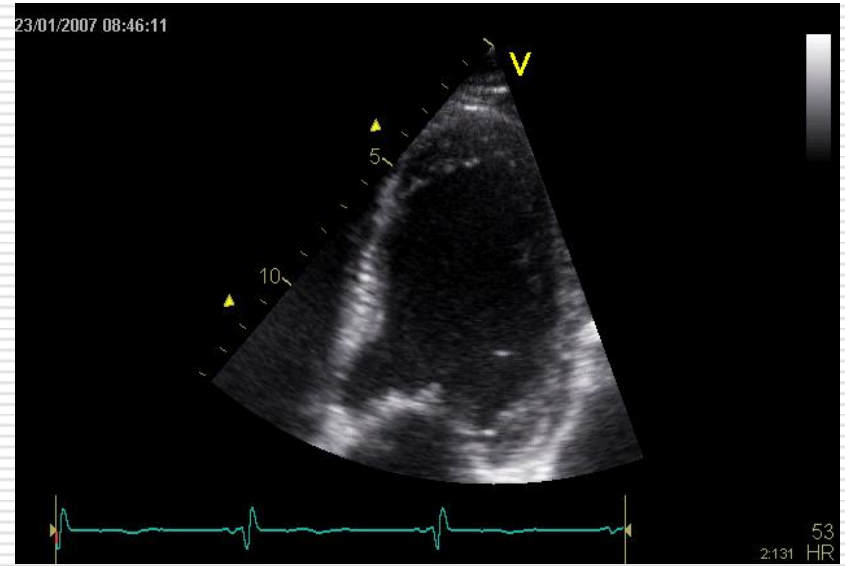
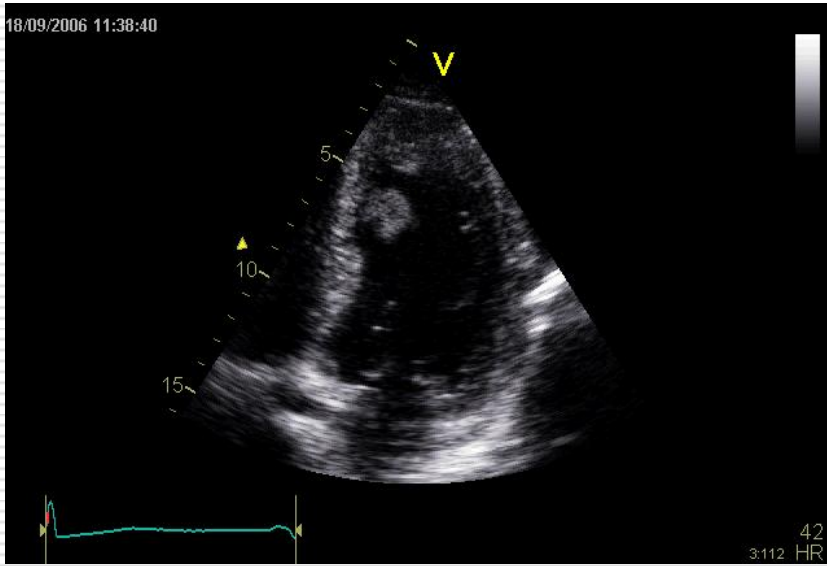




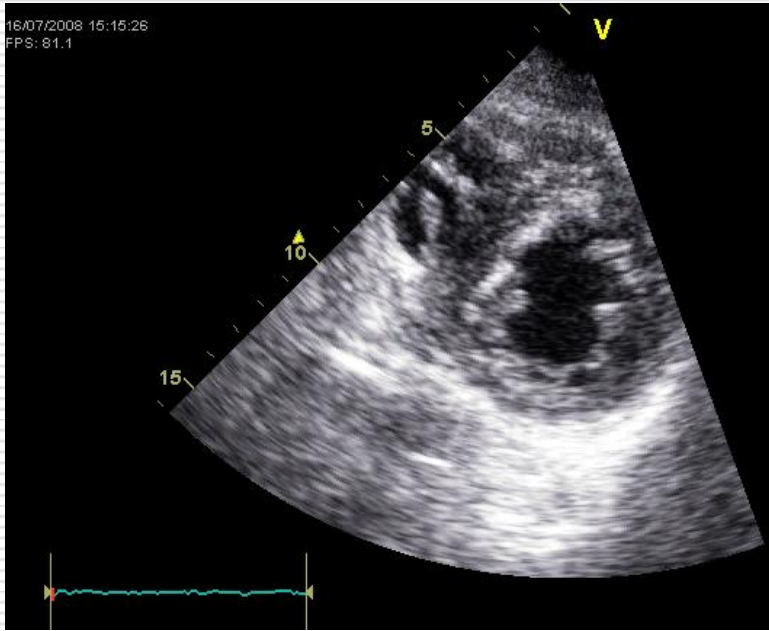






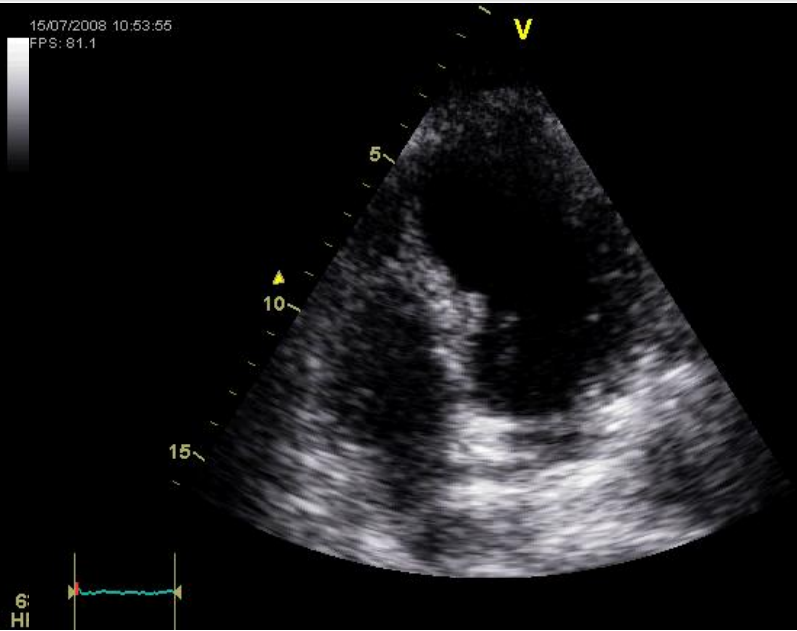


16/07/2008 15:15:26
FPS: 81.1

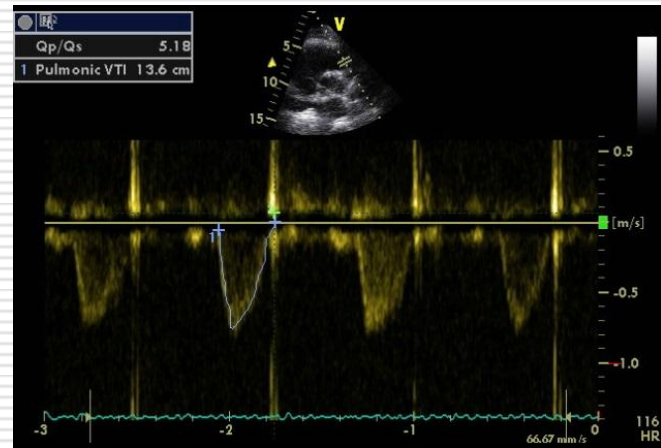
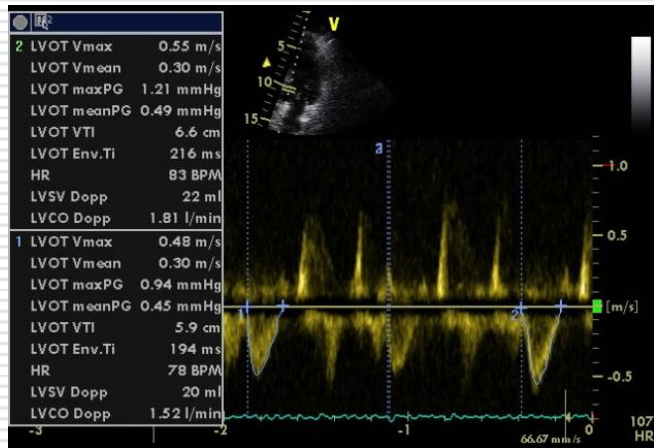


30:135 6 HI

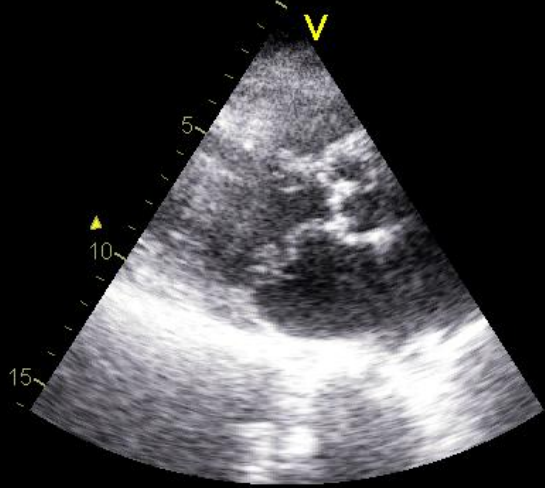
15/07/2008 10:53:55
FPS: 81.1



103 3:46 HR

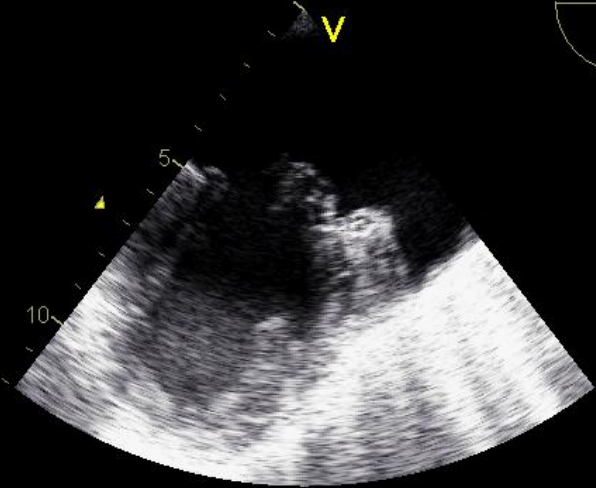


02/12/2009 10:43:20



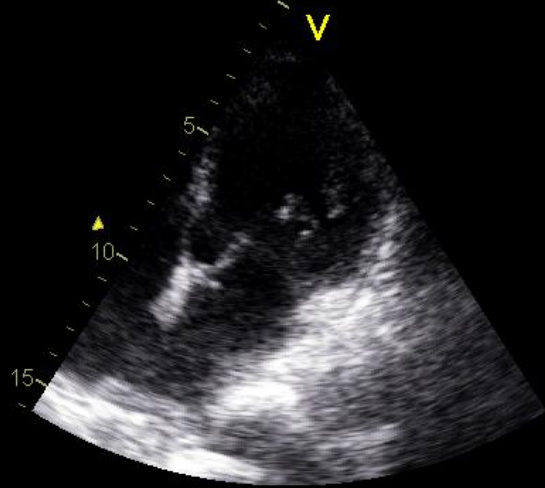
1:83

02/12/2009 11:09:50



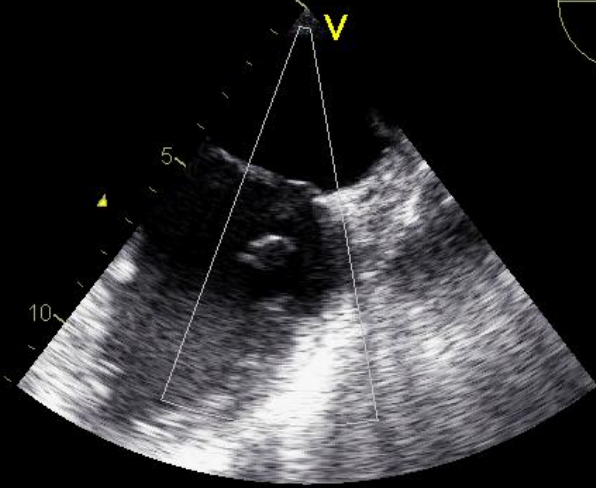
1:62

02/12/2009 10:26:08



1:83

02/12/2009 11:09:29



1:25

