

Ultrazvuková navigace usnadňuje femorální žilní vstup a snižuje riziko cévních komplikací

Stojadinović P, Yamagata K, Peichl P, Aldhoon B,
Fukunaga M, Čihák R, Wichterle D, Kautzner J



Úvod

„The formerly commonly practiced ‘bridging therapy’ with unfractionated heparin or LMWH must not be used since it significantly increases bleeding complications.“

- C. Sticherling et al. EHRA position paper 2015

„Updated real-life rate of major complications of CA for AF persists around 4.0%, the most frequent being vascular access complications.“

- Bertaglia et al. Journal of Cardiovascular Electrophysiology 2013

Naše zkušenosti

Table 2. Major Complications

Type of Complication	Total (n=722)	Idiopathic VT (n=249)	SHD-VT (n=473)
Death	0	0	0
Perforation	3 (0.4%)	0 (0.0%)	3 (0.6%)
Tamponade	2	0	2
Hemopericardium	1	0	1
Thromboembolic event	5 (0.7%)	1 (0.4%)	4 (0.8%)
Stroke intraprocedural	2	0	2
TIA intraprocedural	1	1	0
TIA <7 d	1	0	1
Systemic embolism (legs)	1	0	1
Conduction system damage	7 (1.0%)	1 (0.4%)	6 (1.3%)
AV block	6	1	5
LBBB resulting in HF	1	0	1
Other	4 (0.6%)	1(0.4%)	3 (0.6%)
Pericarditis	1	1	0
RV lead dysfunction	1	0	1
CPR during the procedure	2	0	2
Vascular access	26 (3.6%)	4 (1.6%)	22 (4.7%)
Femoral pseudoaneurysm	14	2	12
Femoral AVF	5	2	3
Groin hematoma			
With surgical management	3	0	3
With transfusion needed	3	0	3
With conservative management	1	0	1
Total	45 (6.2%)	7 (2.8%)	38 (8.0%)

Values are counts (%). AV indicates atrioventricular; AVF, arteriovenous fistula; CPR, cardiopulmonary resuscitation; HF, heart failure; LBBB, left bundle branch block; RV, right ventricular; SHD, structural heart disease; TIA, transient ischemic event; and VT, ventricular tachycardia.

Peichl P et al. Circ EP 2014

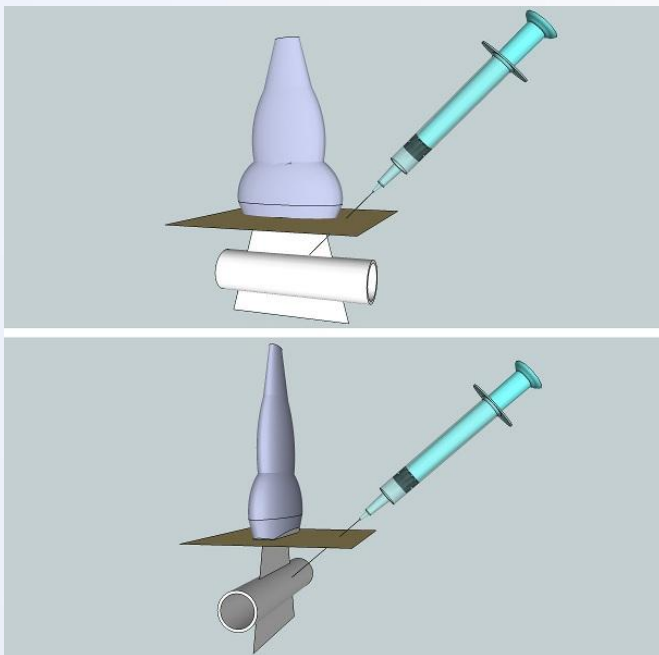
Table 2 Major complications in patients undergoing atrial fibrillation ablation: type and frequency

Complication type	Frequency	
	n	%
Cardiac tamponade/hemopericardium	3	0.25
Stroke	2	0.17
Transient ischaemic attack	3	0.25
Atrioventricular block	1	0.08
Pericarditis	1	0.08
Sepsis	1	0.08
Transient phrenic nerve paresis	1	0.08
Vascular complications		
Hemothorax	2	0.17
Retroperitoneal bleeding	2	0.17
Subclavian vein bleeding	1	0.08
Femoral arteriovenous fistula	7	0.59
Femoral pseudoaneurysm	4	0.34
Femoral vein bleeding	12	1.00
Total	40	3.36

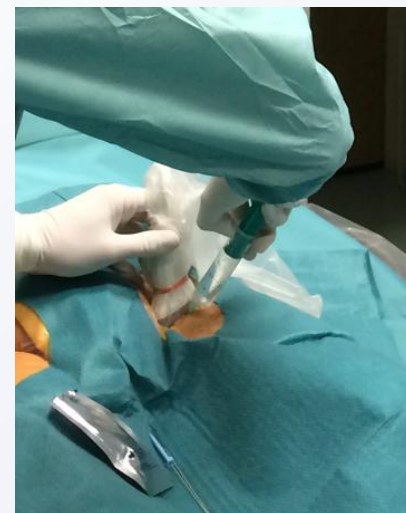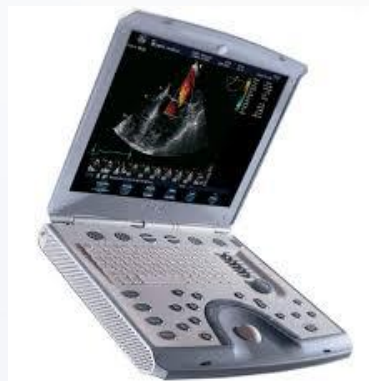In one case, both groin bleeding and transient phrenic nerve injury occurred in the same patient.

Aldhoon B et al. Europace 2013

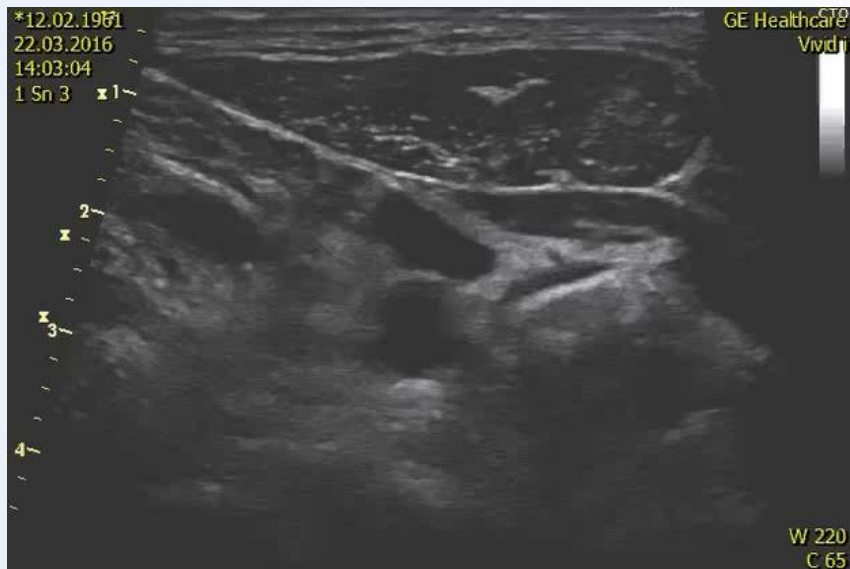Ultrazvukem navigovaná kanylace žil



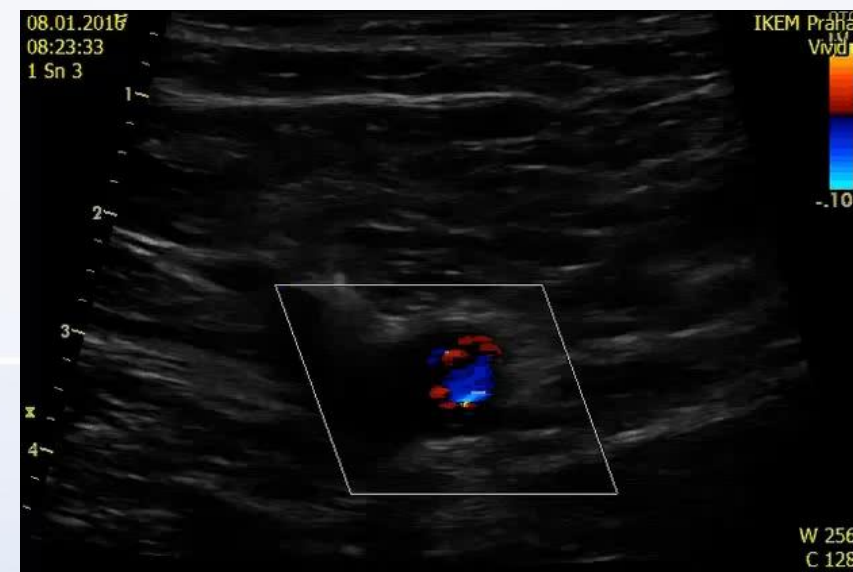
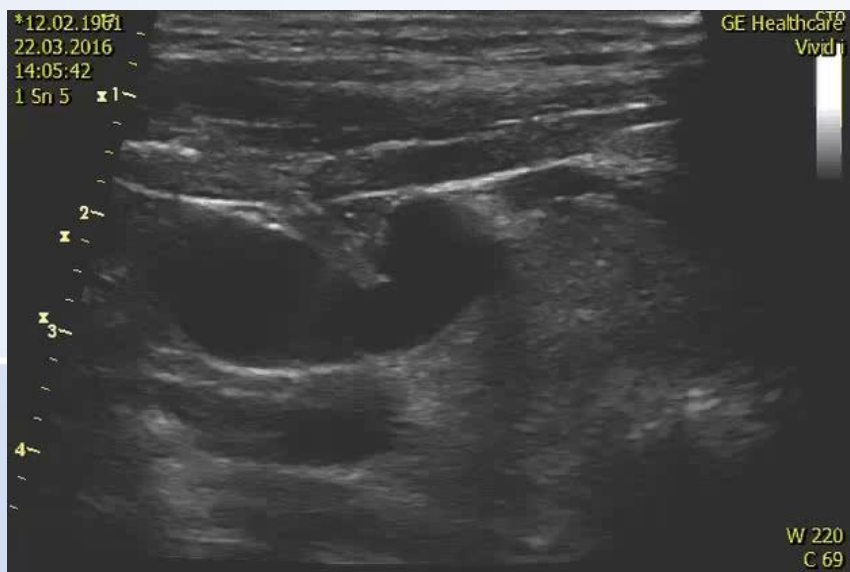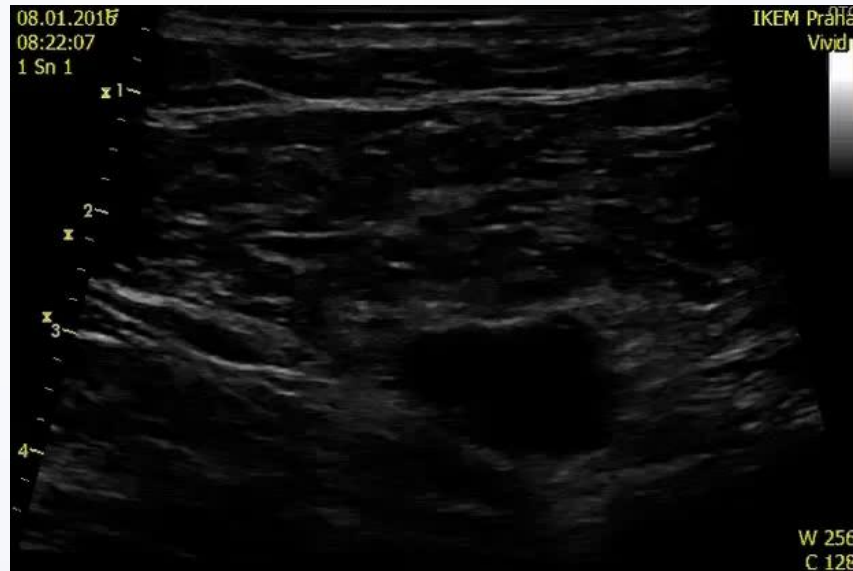
- Long-axis/in-plane
- Short-axis/out-of-plane



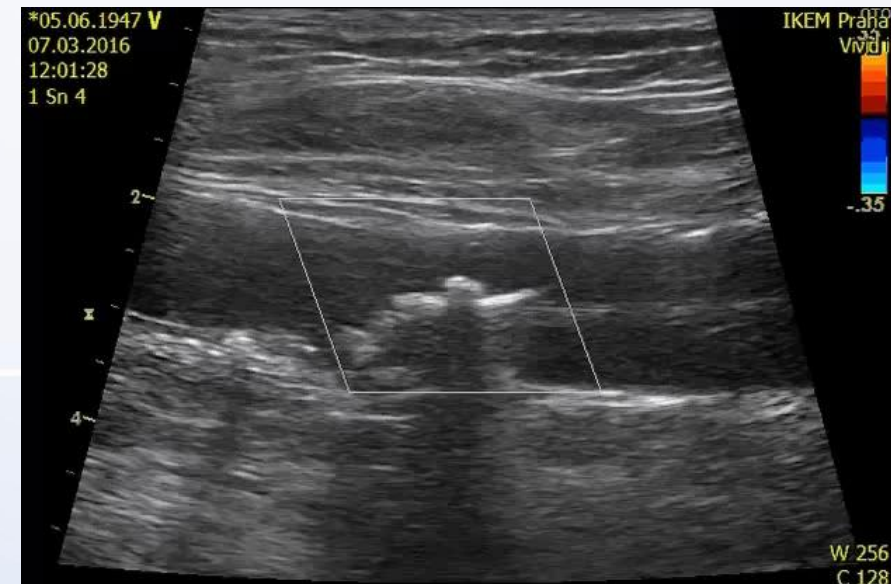
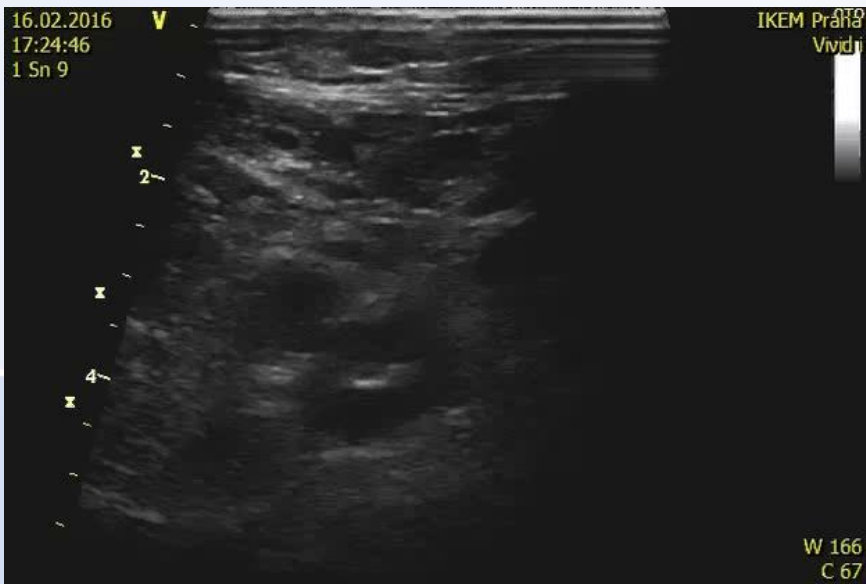
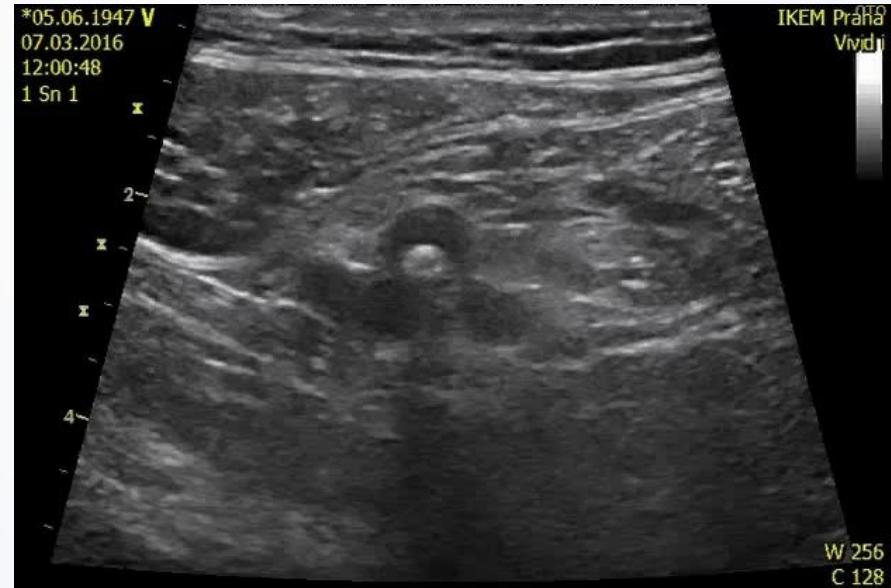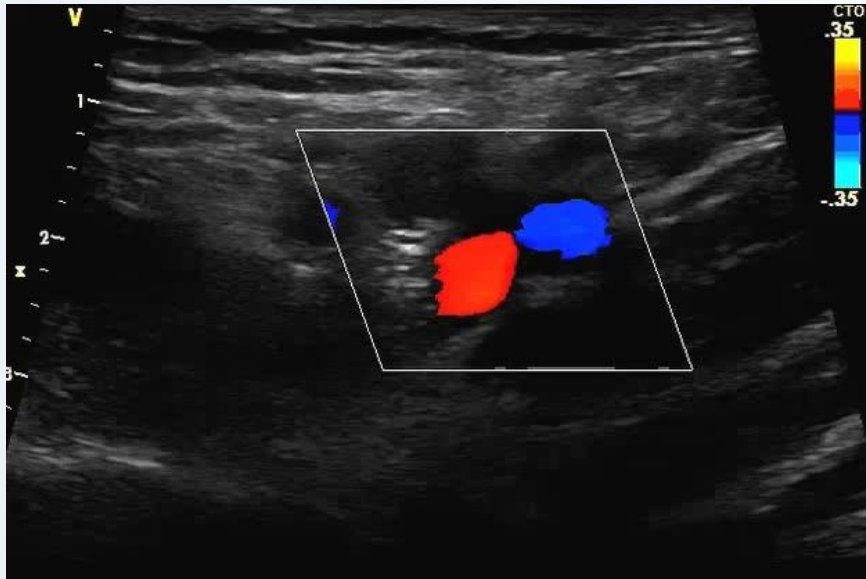
Kanylace vena jugularis interna



Kanylace vena/arteria femoralis



Atypická anatomie/nálezy



Design studie

- Prospektivní randomizovaná studie
- Srovnání konvenční/anatomické a ultrazvukem navigované kanylace femorálních žil
- V souvislosti s radiofrekvenční ablací pro fibrilaci síní

Soubor pacientů

Clinical Characteristics	USG (n = 159)	CONV (n = 160)	<i>P value</i>
Age (years)	63.1 ± 7.4	62.9 ± 9.9	0.85
Male	96 (60%)	100 (63%)	0.70
Body mass index (kg/m ²)	29.6 ± 5.1	29.7 ± 5.3	0.96
Warfarin	95 (60%)	95 (59%)	0.95
Prothrombin time (INR)	2.2 ± 0.4	2.2 ± 0.5	0.85
New oral anticoagulants	64 (40%)	65 (41%)	0.95
Trainees	76 (48%)	79 (49%)	0.78
Re-do procedure	37 (23%)	36 (23%)	0.87
Use of large-diameter sheath	9 (6%)	5 (3%)	0.27
Protamine administration	99 (62%)	104 (65%)	0.61



Výsledky

Outcome	USG (n = 159)	CONV (n = 160)	P value
Primary outcome	1 (0.6%)	3 (1.9%)	0.62
Hematoma with hemoglobin drop	0 (0%)	2 (1.3%)	0.50
Arteriovenous fistula	1 (0.6%)	1 (0.6%)	1.000
Secondary outcomes			
Intra-procedural outcomes			
Puncture time (sec)	288 [191-370]	369 [257-584]	<0.001
First-pass success	118 (74%)	32 (20%)	<0.001
Extra puncture attempts (per patient)	0.5 ± 1.9	2.1 ± 1.9	<0.001
Inadvertent arterial puncture (per patient)	0.07 ± 0.38	0.25 ± 0.51	<0.001
Use of X-ray	4 (3%)	17 (11%)	<0.01
Unsuccessful cannulation	1 (0.6%)	22 (14%)	<0.001
Cross-over	0 (0%)	14 (9%)	<0.001
Hand-over the procedure	1 (0.6%)	11 (7%)	<0.01
Prolonged compression	19 (12%)	23 (14%)	0.52
Pain scale >3	3 (2%)	9 (6%)	0.08

Závěr

Ultrazvukem navigovaná kanylace (oproti konvenční anatomické)

- Usnadňuje femorální žilní vstup
 - Umožňuje kontrolu nad samotnou punkcí
 - Je bezpečnější
 - Je rychlejší i v rukou zkušených operatérů
 - Zobrazí důvod selhání konvenčního přístrupu!
-
- Nízký celkový počet závažných komplikací v obou větvích.

Děkuji za pozornost

