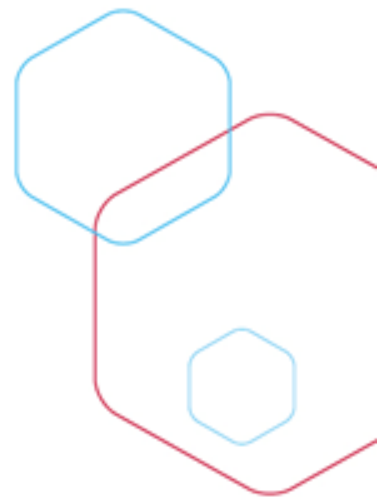


# Distal left main- PCI

XXXIII. WORKSHOP ČESKÉ ASOCIACE INTERVENČNÍ  
KARDIOLOGIE

KARDIOCENTRUM NEMOCNICE PODLESÍ TŘINEC  
(DR. VODZINSKÁ, DR. ČERNÝ, DR. INDRÁK,  
DR. HUDEC, DR. BALUŠÍK A KOL)



# Pacient

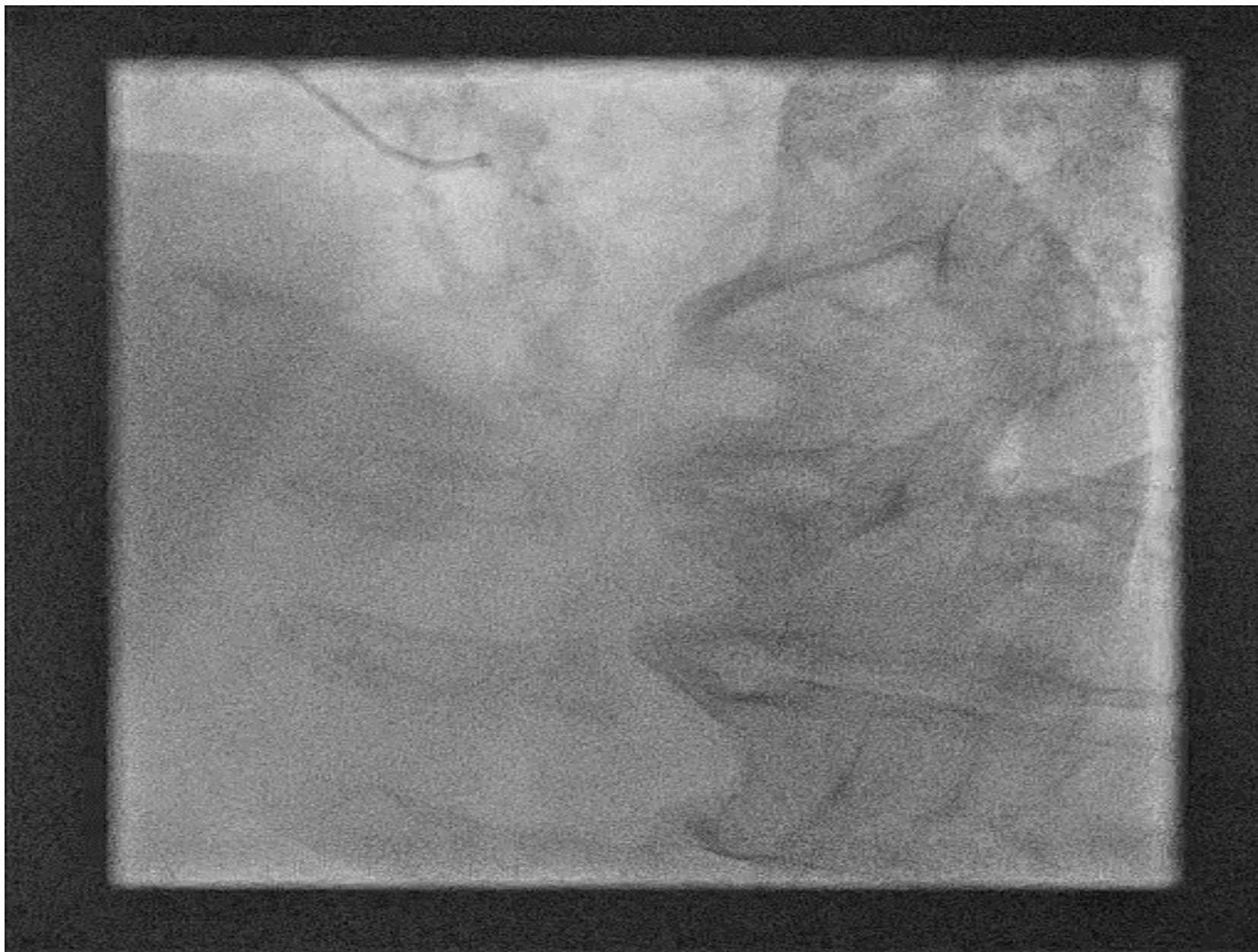
- 74 years
- women
- Fragile, limited mobility
- Hypertension, diabetes mellitus on insulinotherapy, hyperlipidaemia
  
- PAD- diffuse peripheral disease with large infected defects

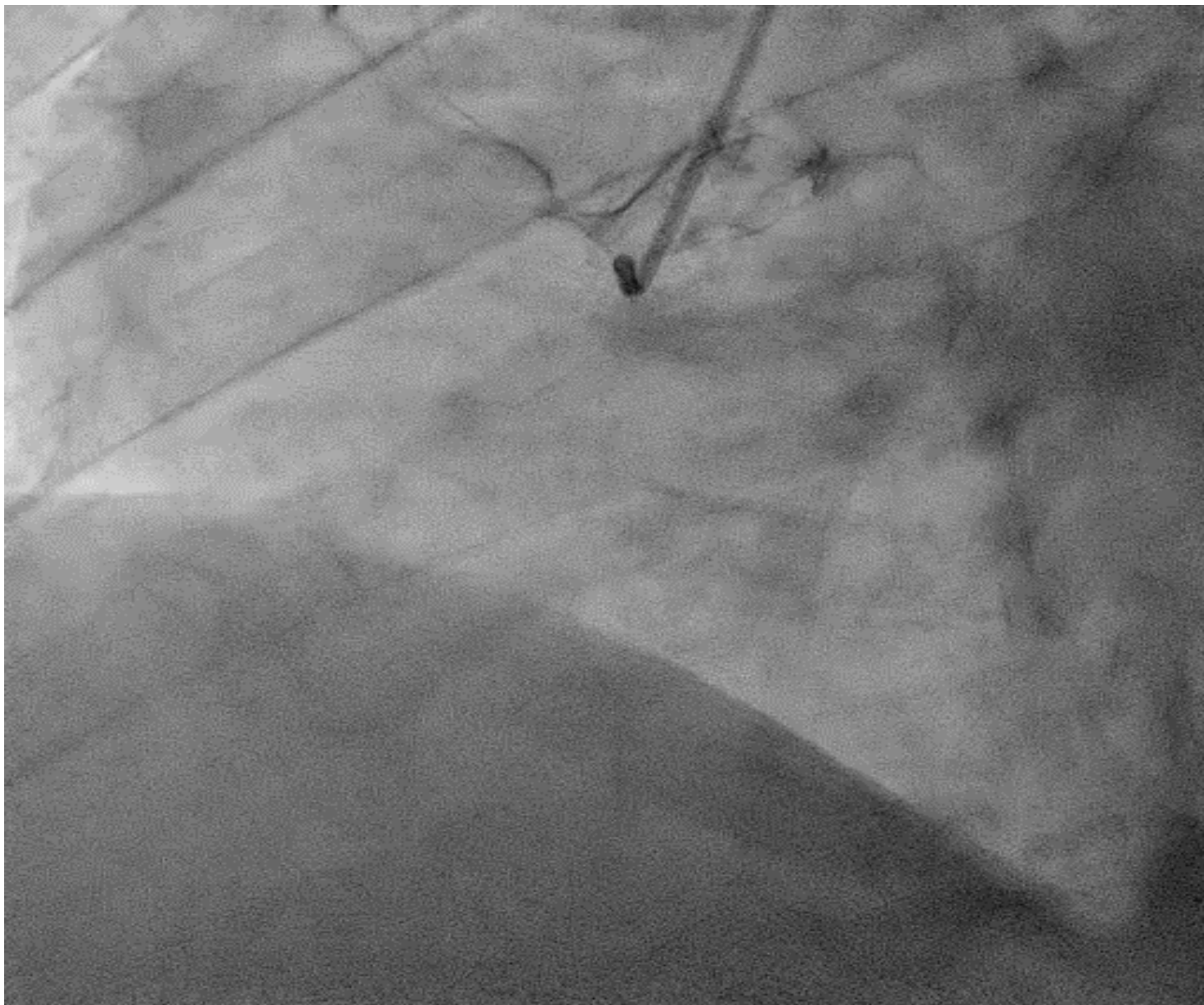
# Pacient

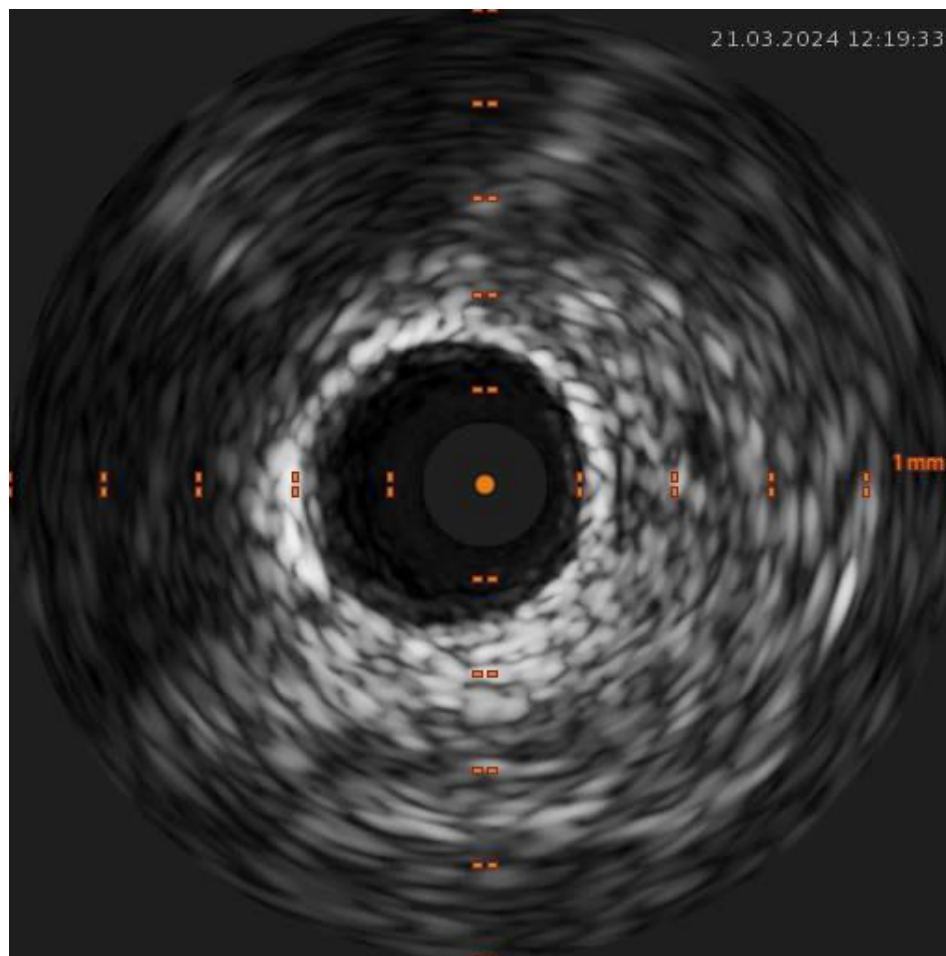
- Accelerated blood pressure with heart failure
- ECG- negative T wave from lateral wall
- Positive cardiomarkers

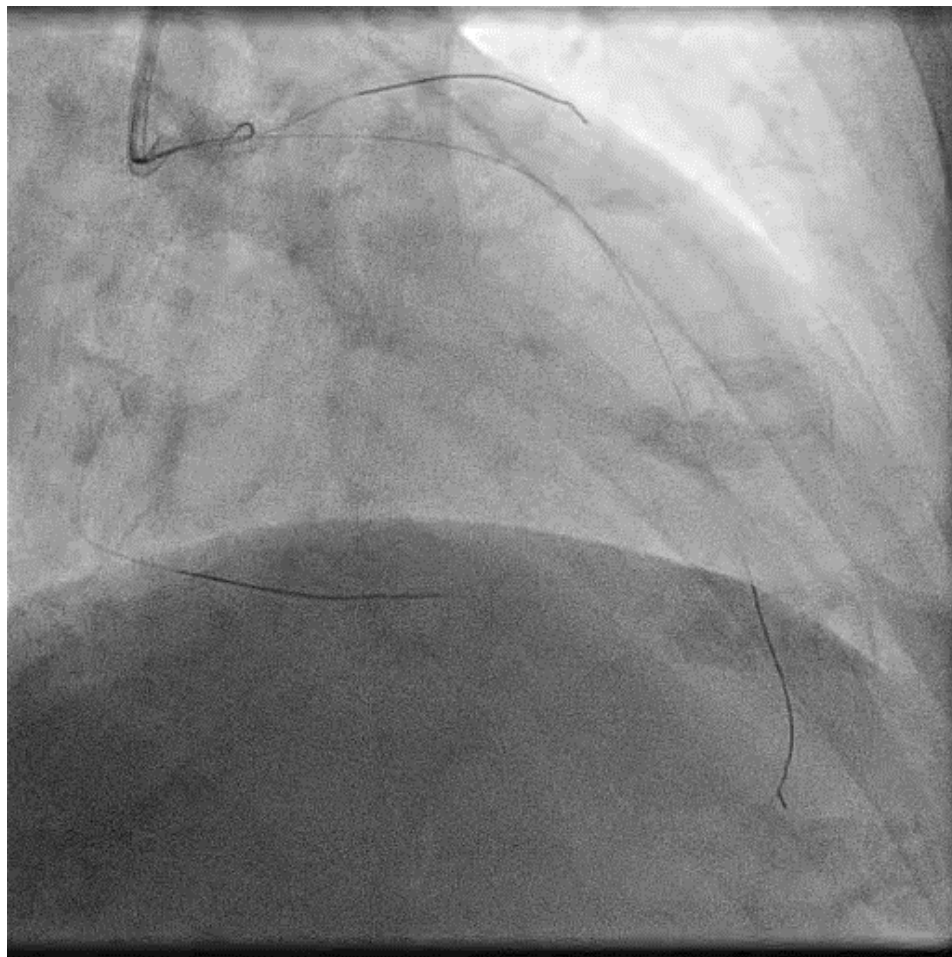
# Angiography

- Heavily calcify left main stenosis
- Stenosis LAD, RIM, RCx
- CTO RCA

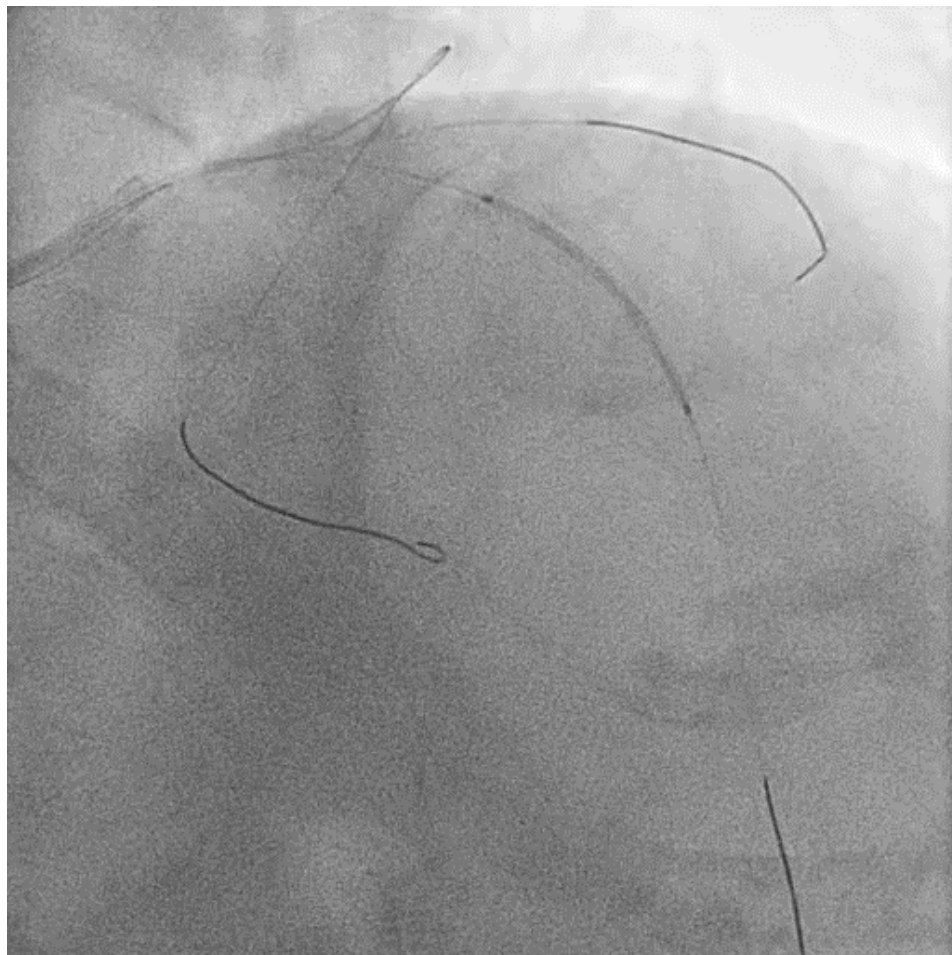


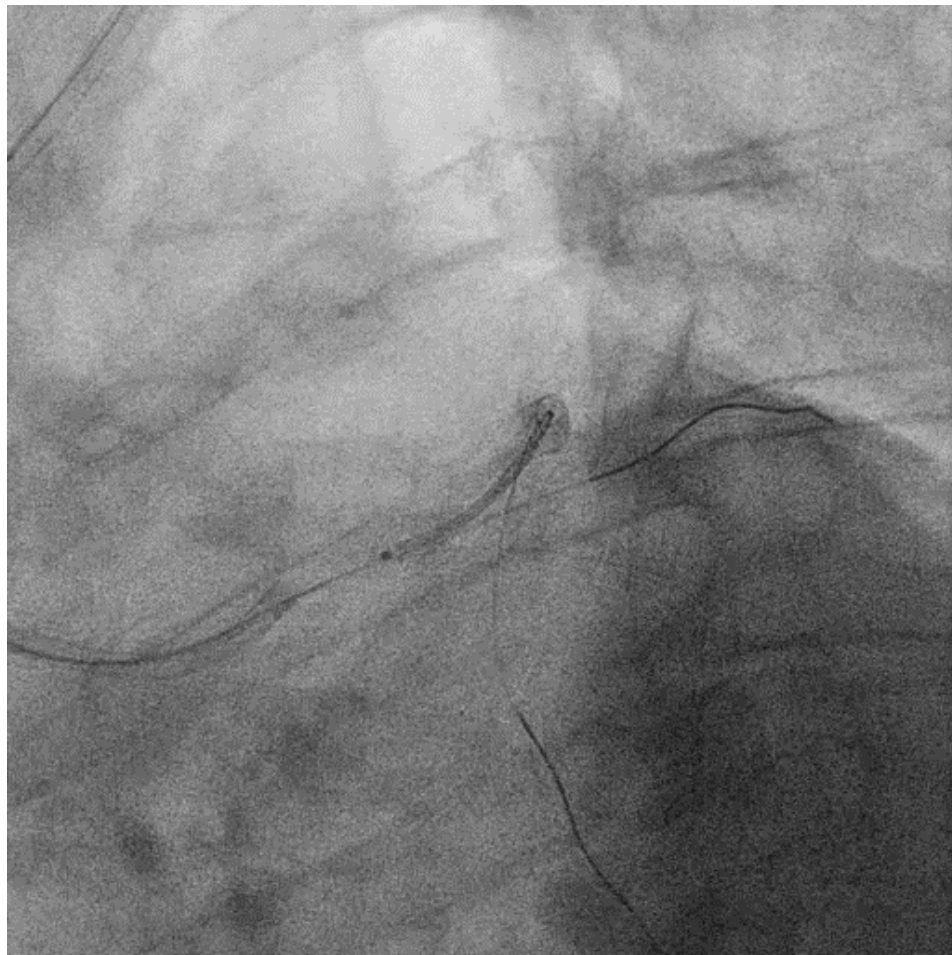

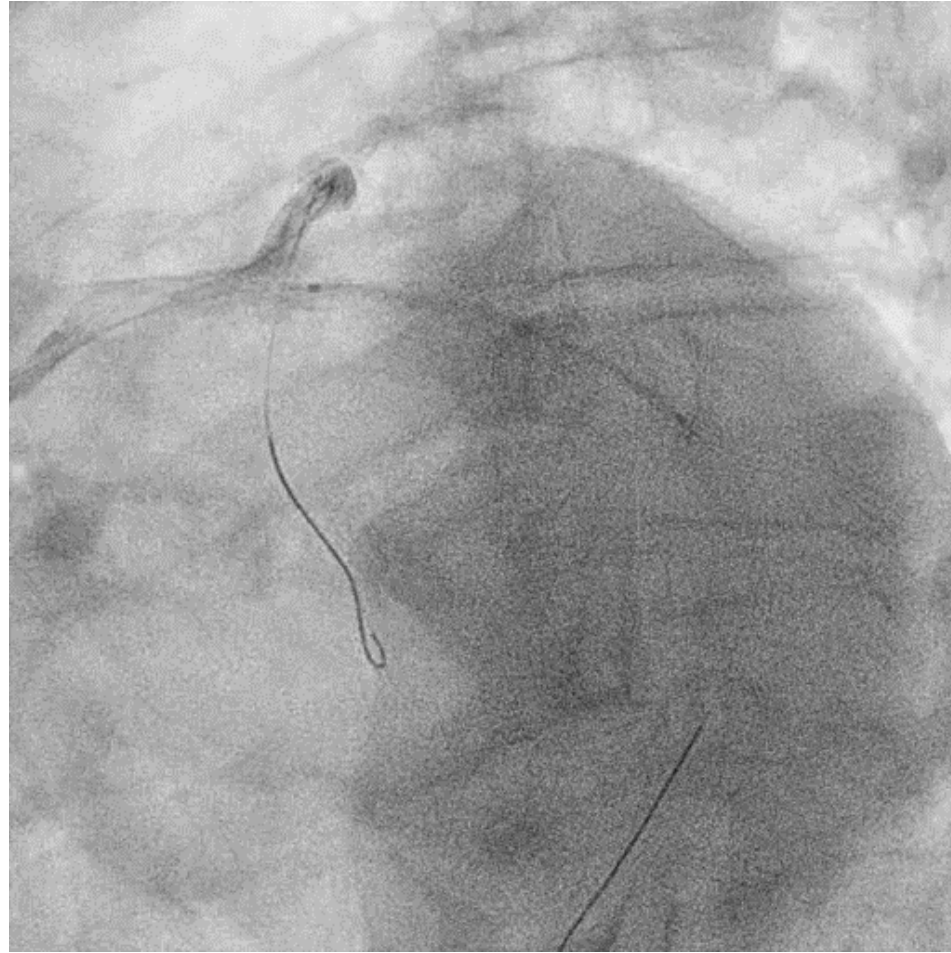


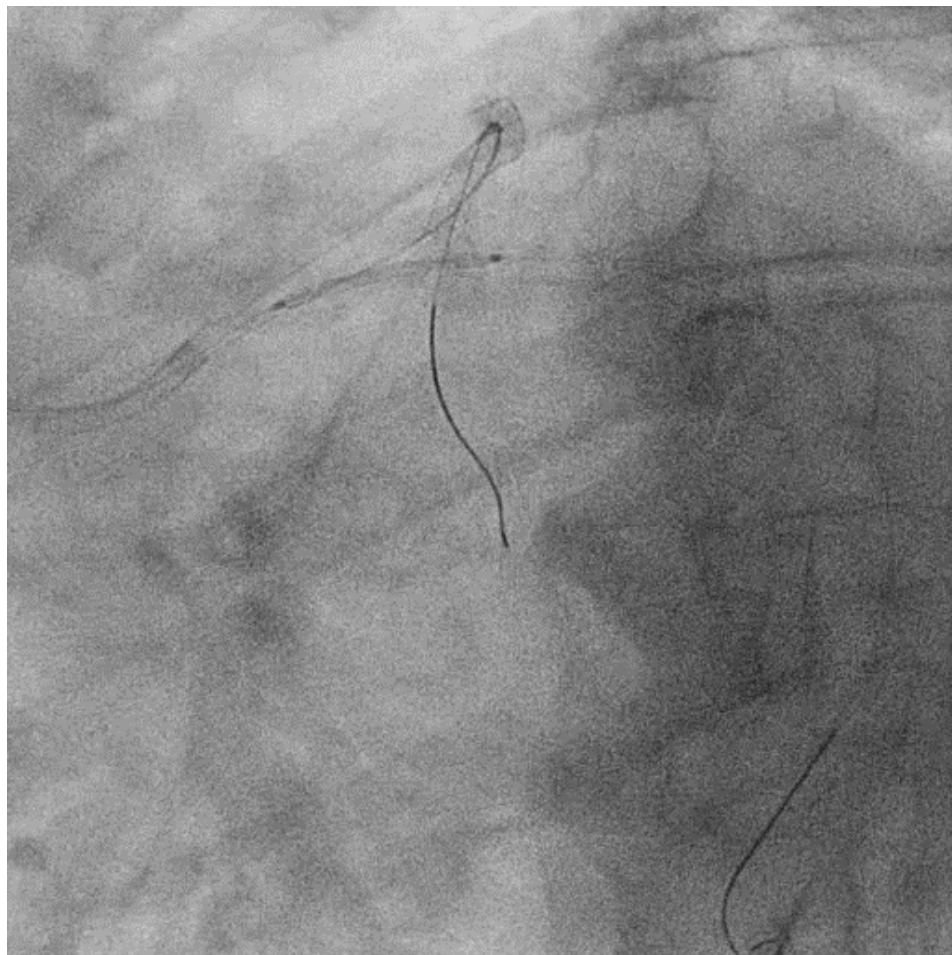


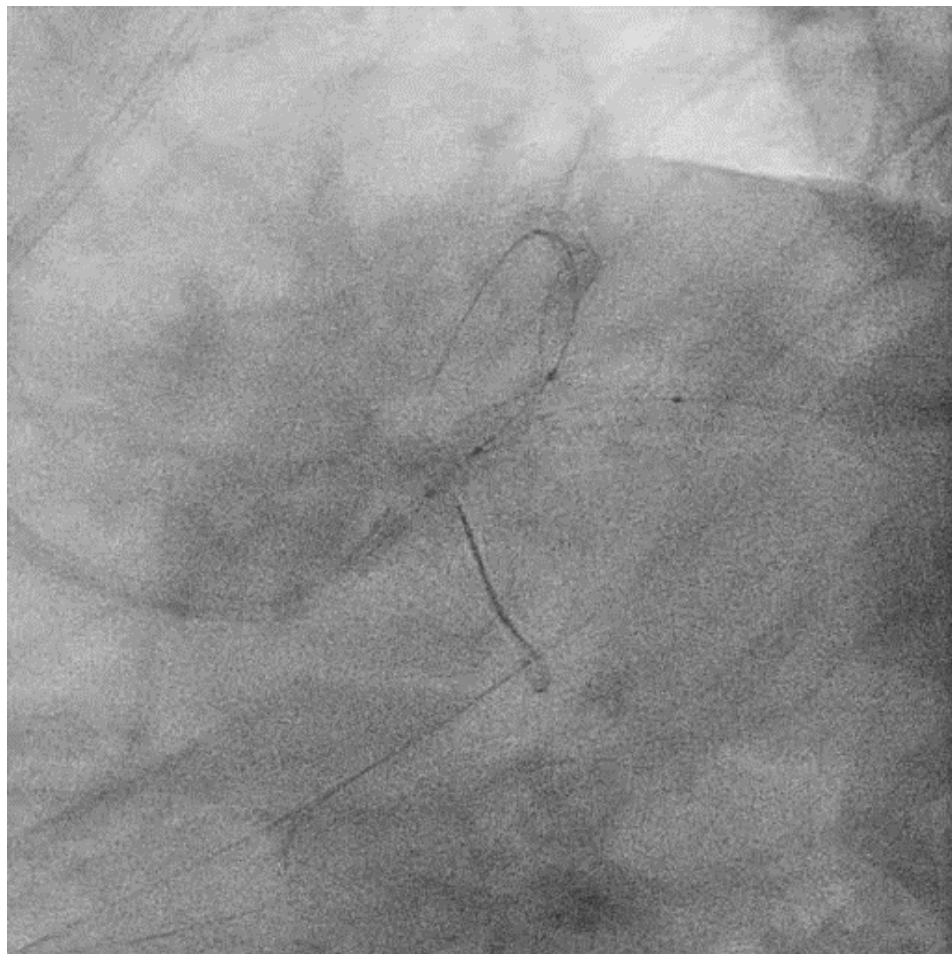


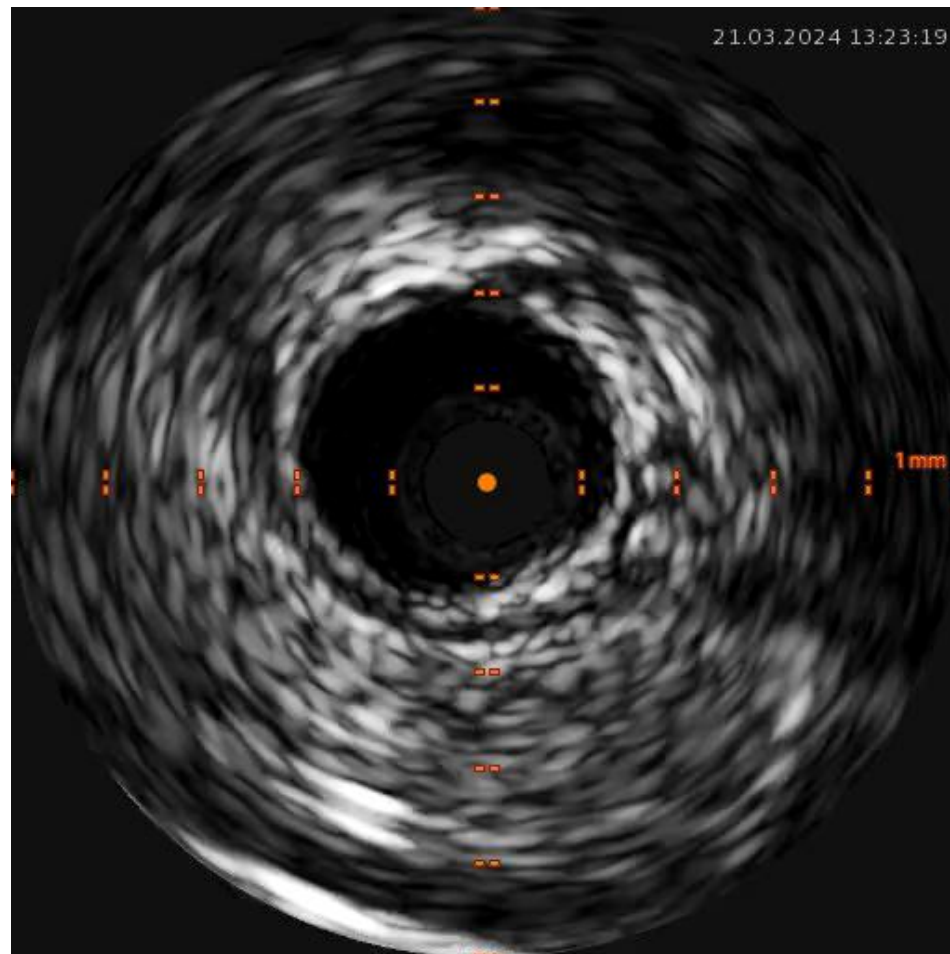


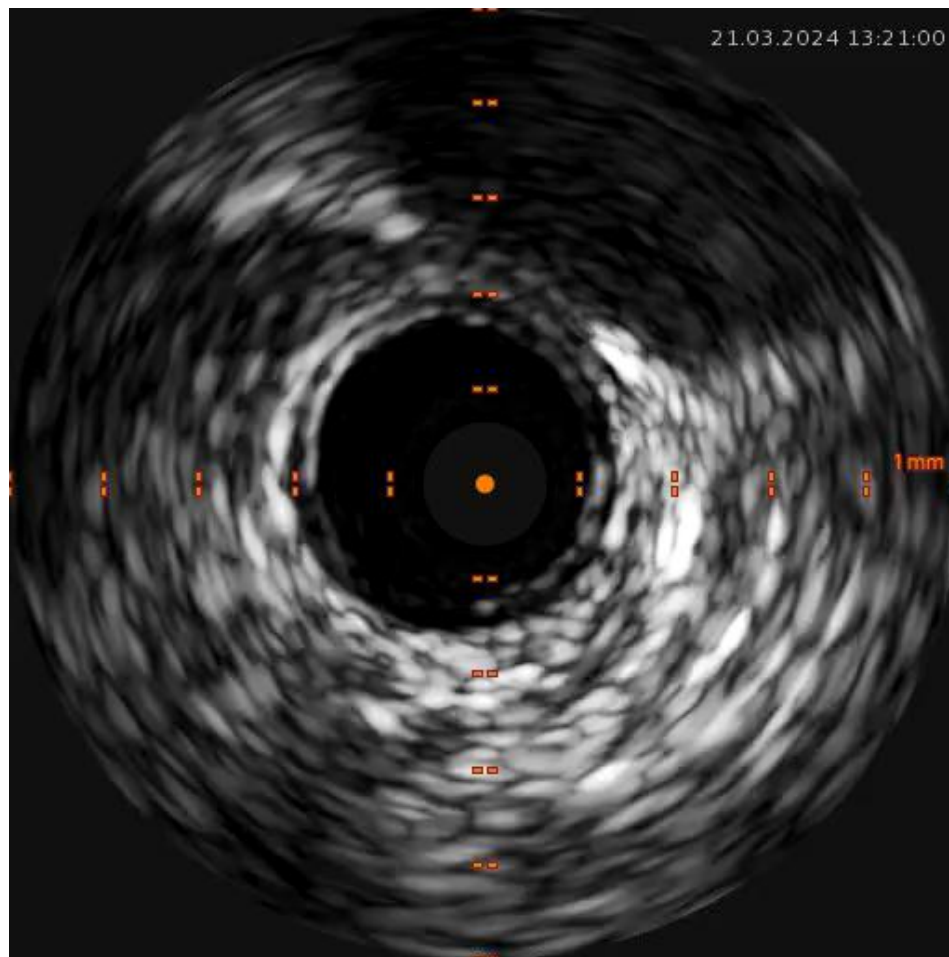


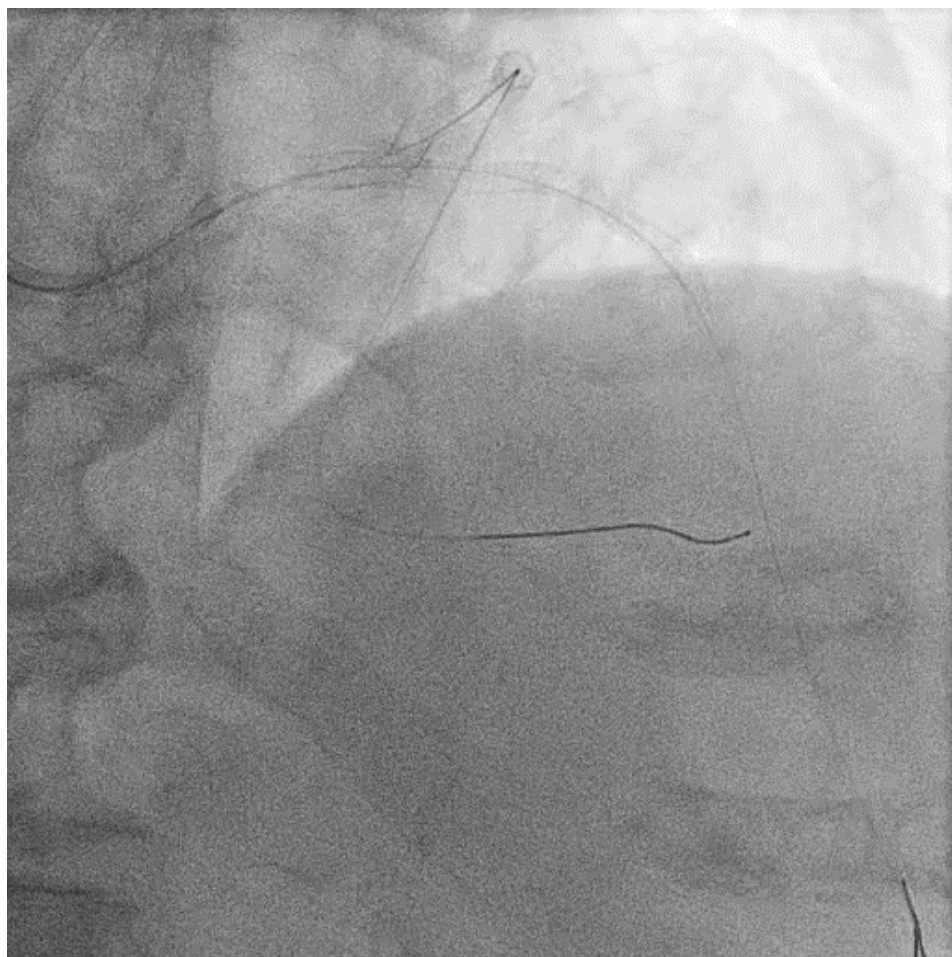




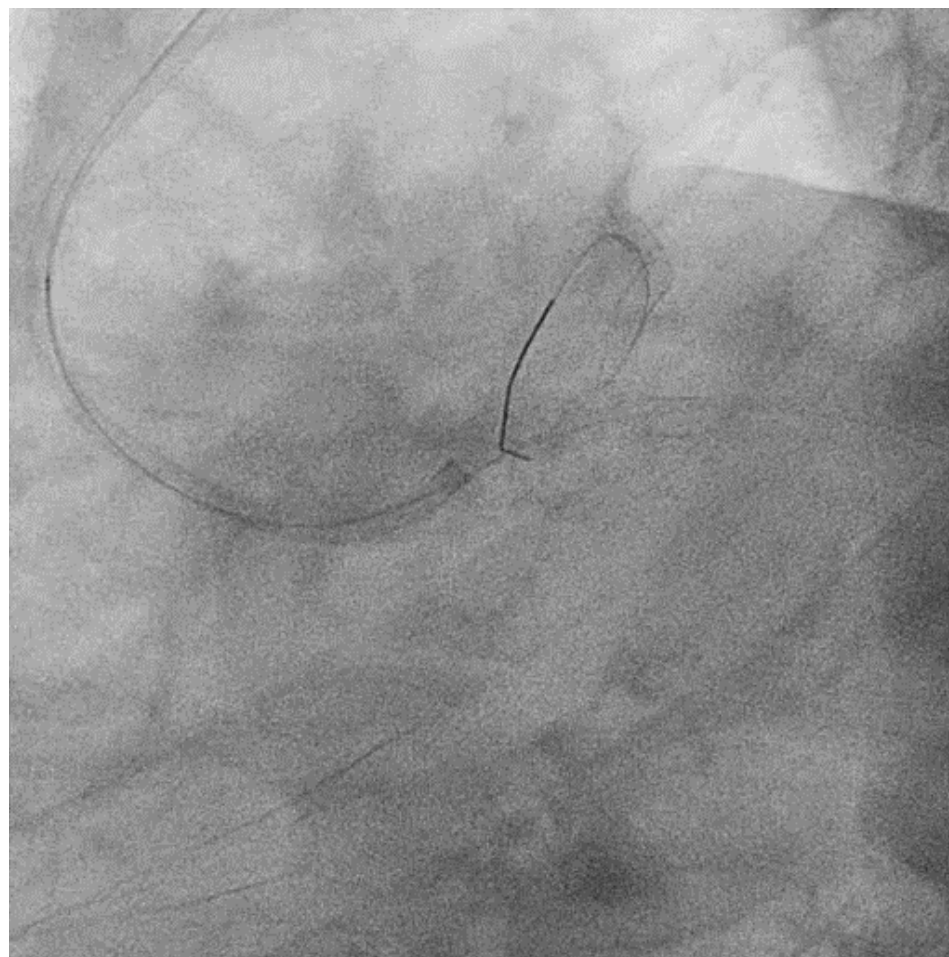












Thank you for your attention.

