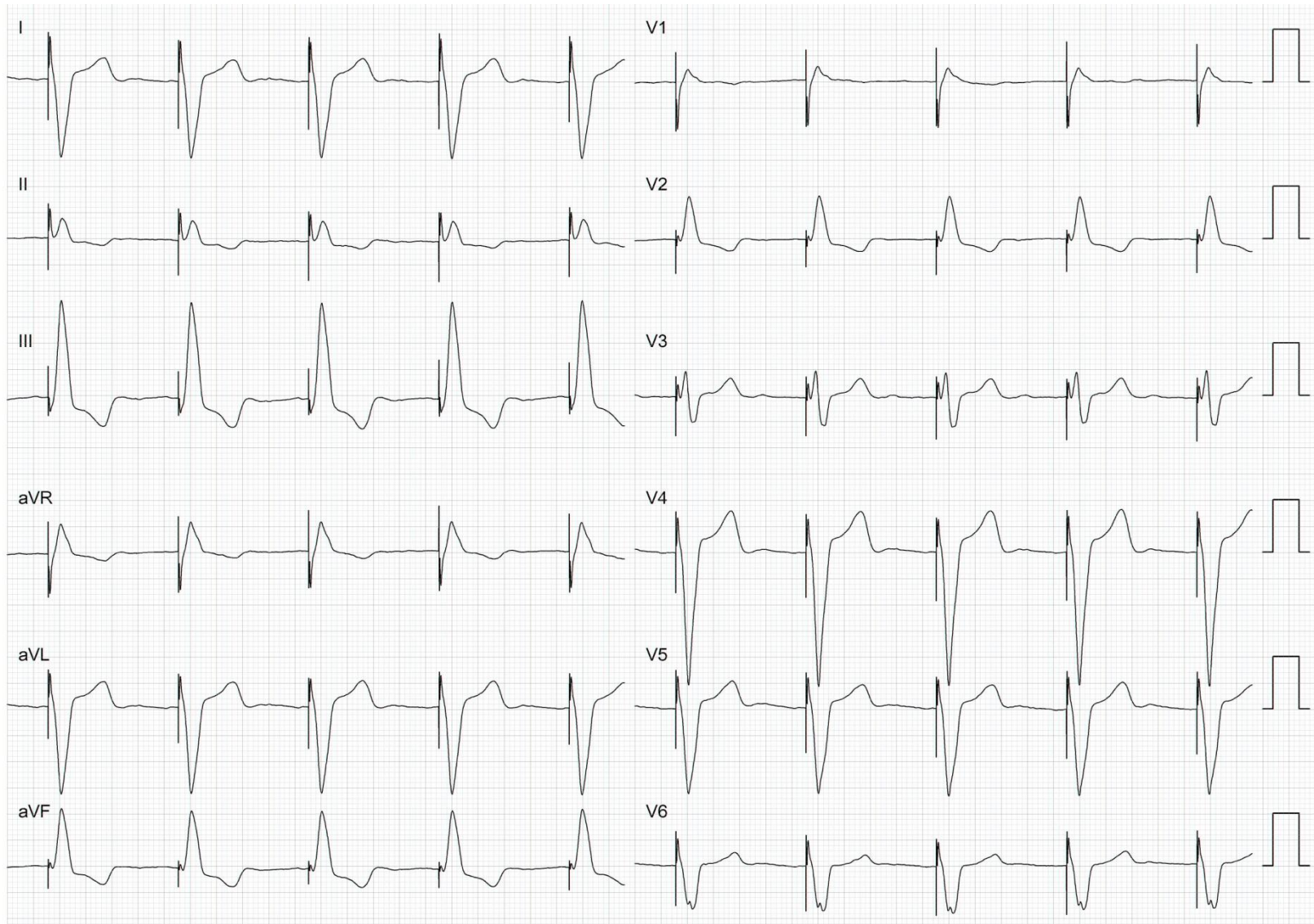


PRAVIDELNÁ SÍŇOVÁ TACHYKARDIE V ELEKTRICKY IZOLOVANÉM OUŠKU PRAVÉ SÍNĚ, JINAK ELEKTRICKY EXTRÉMNĚ NEMOCNÉ PRAVÉ SÍNĚ – KAZUISTIKA

Procházková R.¹, Žďárská J.¹, Štros P.¹,
Heřman D.¹, Čurila K.¹, Osmančík P.¹

¹ *III. interní kardiologické oddělení, FNKV,
Praha*

- 80-ti letá pacientka
- 2003 implantován KS DDD pro SSS
- Červenec 2016 pravidelná síňová tachykardie
 - Délka cyklu 270 ms, převod na komory 3:1
 - Na EKG VVI stimulace



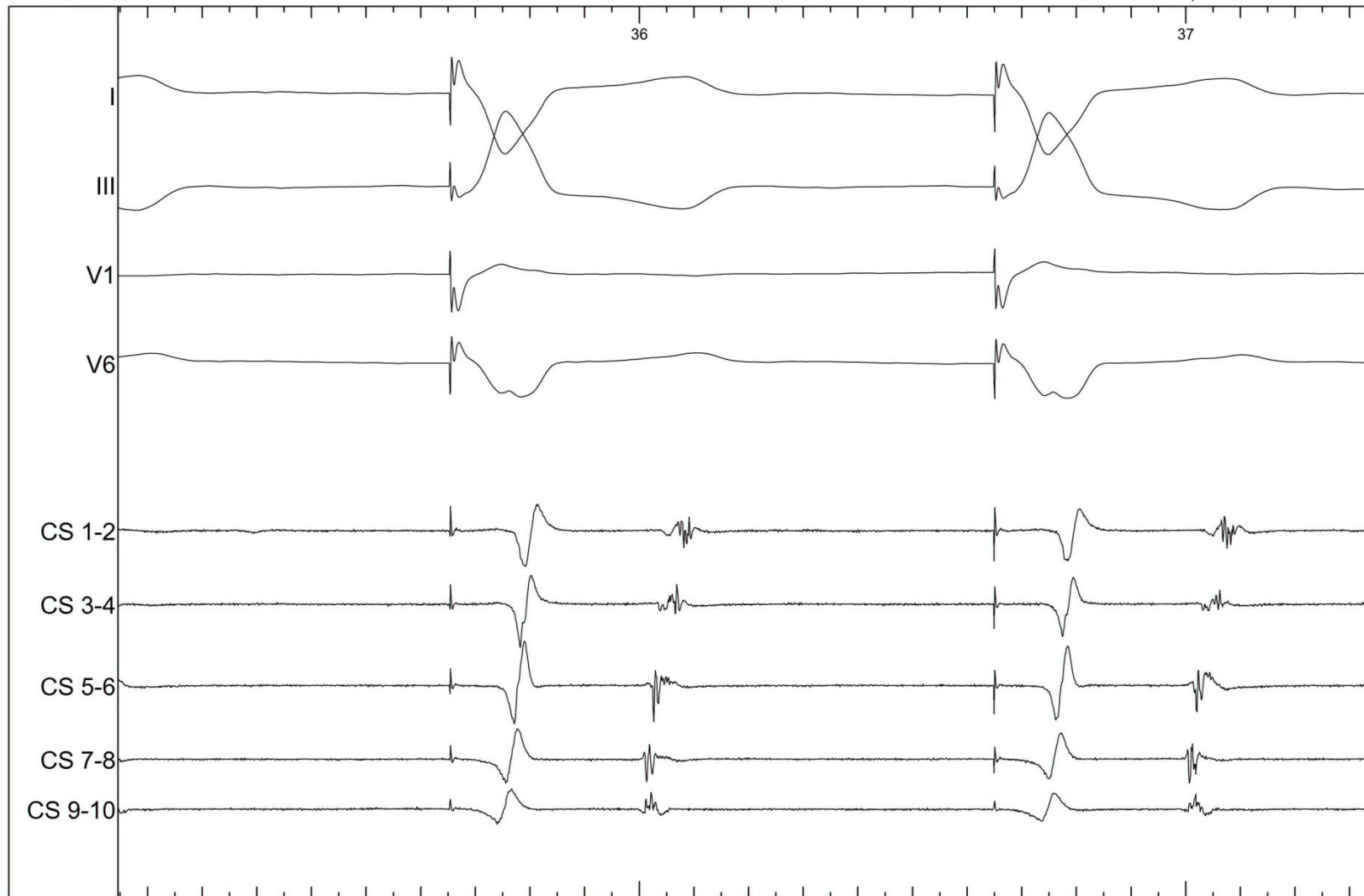
25 mm/s 10 mm/mV Low cutoff: 0.1 Hz, High cutoff: 25 Hz, Notch Filter On, (Low Cutoff of 0.05 Hz recommended for diagnostic ECG)

Zavedeni cs katetru

Fakultni Nemocnice Kralovske Vinohrady

Patient:

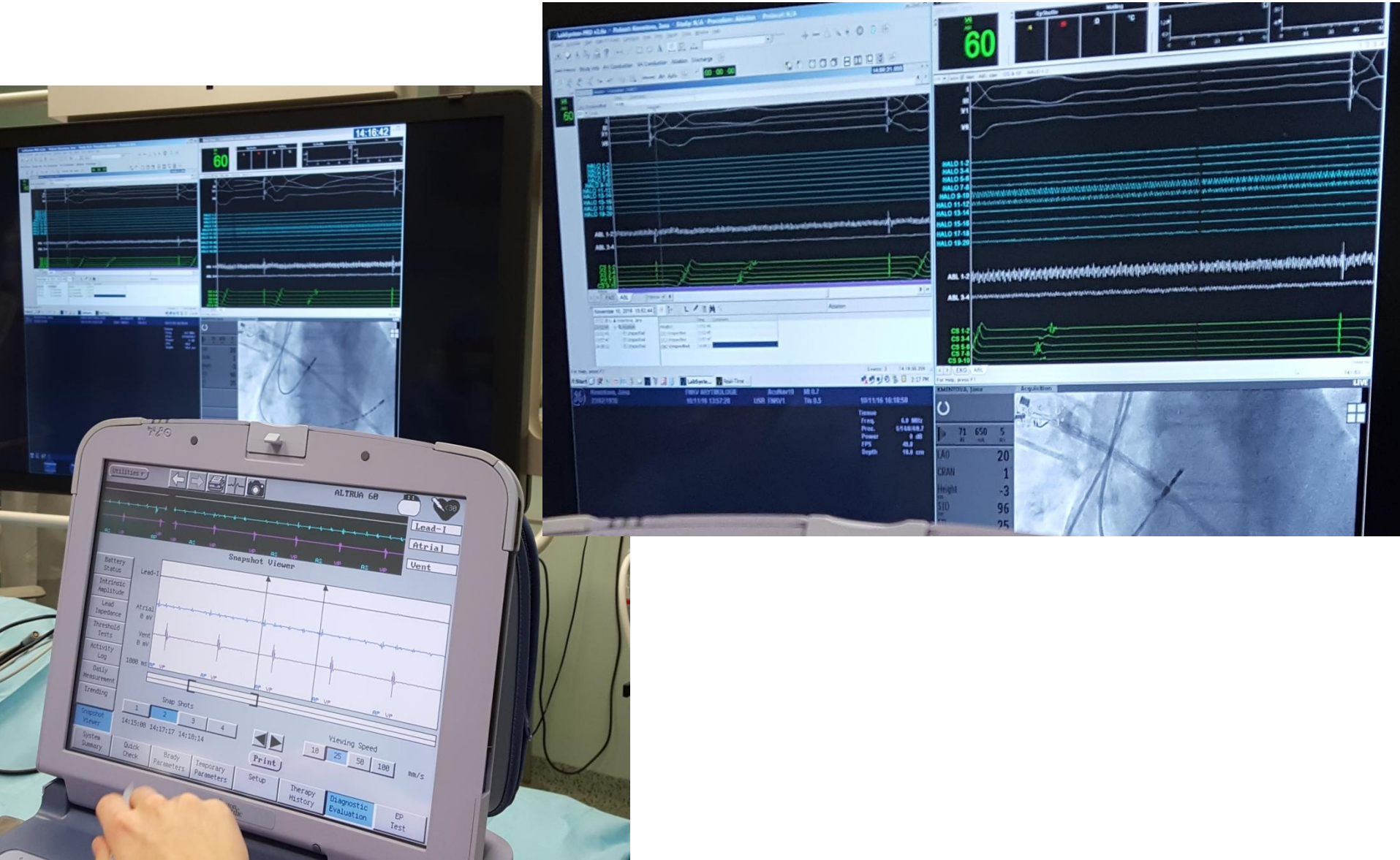Recorded on November 10, 2016 at 14:08:20.421



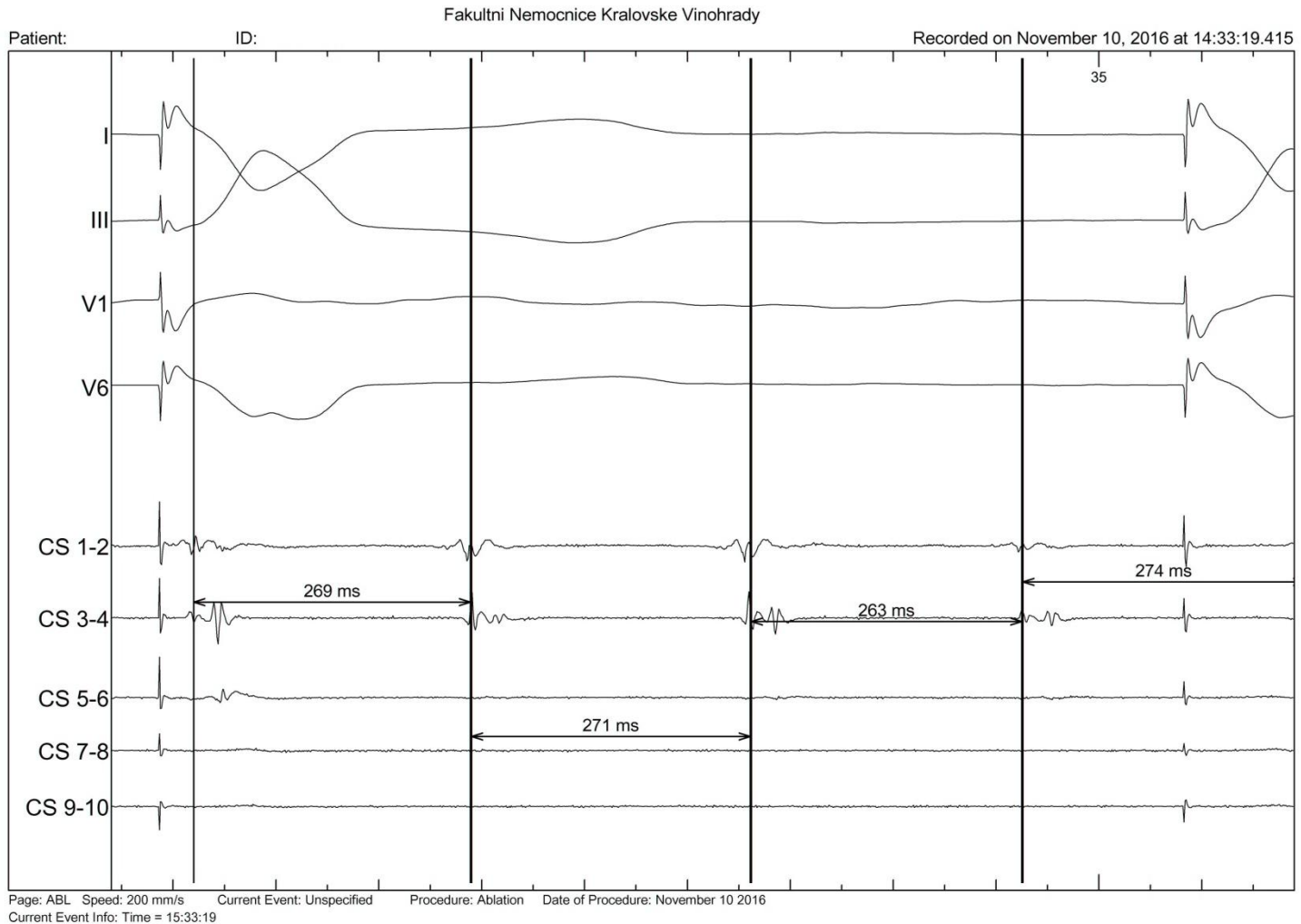
Page: ABL Speed: 100 mm/s Current Event: Unspecified Procedure: Ablation Date of Procedure: November 10 2016

Current Event Info: Time = 15:08:21

Interrogace KS



Deseti-polární katétr položený jako halo



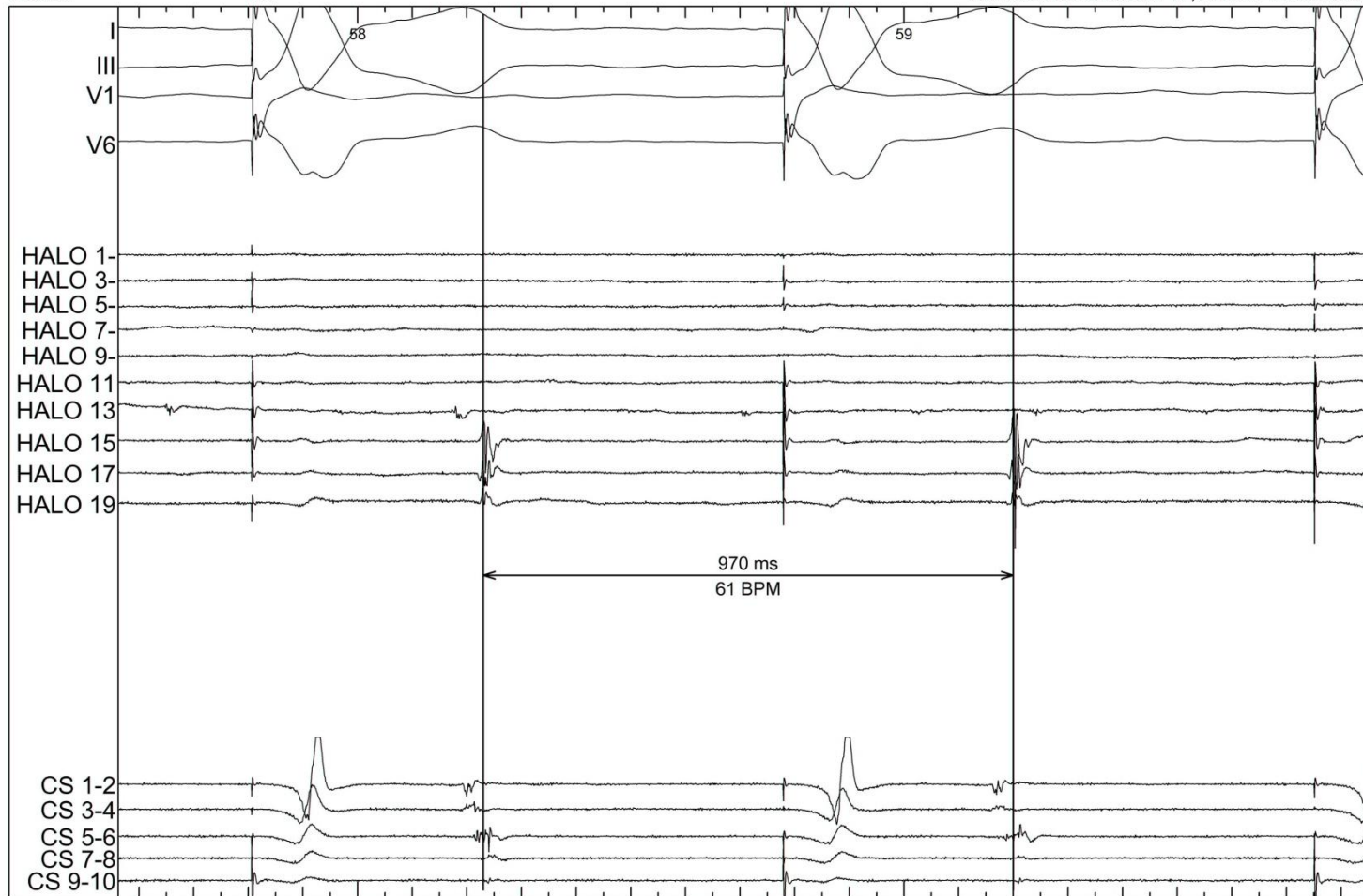
Zavedeno halo

Fakultni Nemocnice Kralovske Vinohrady

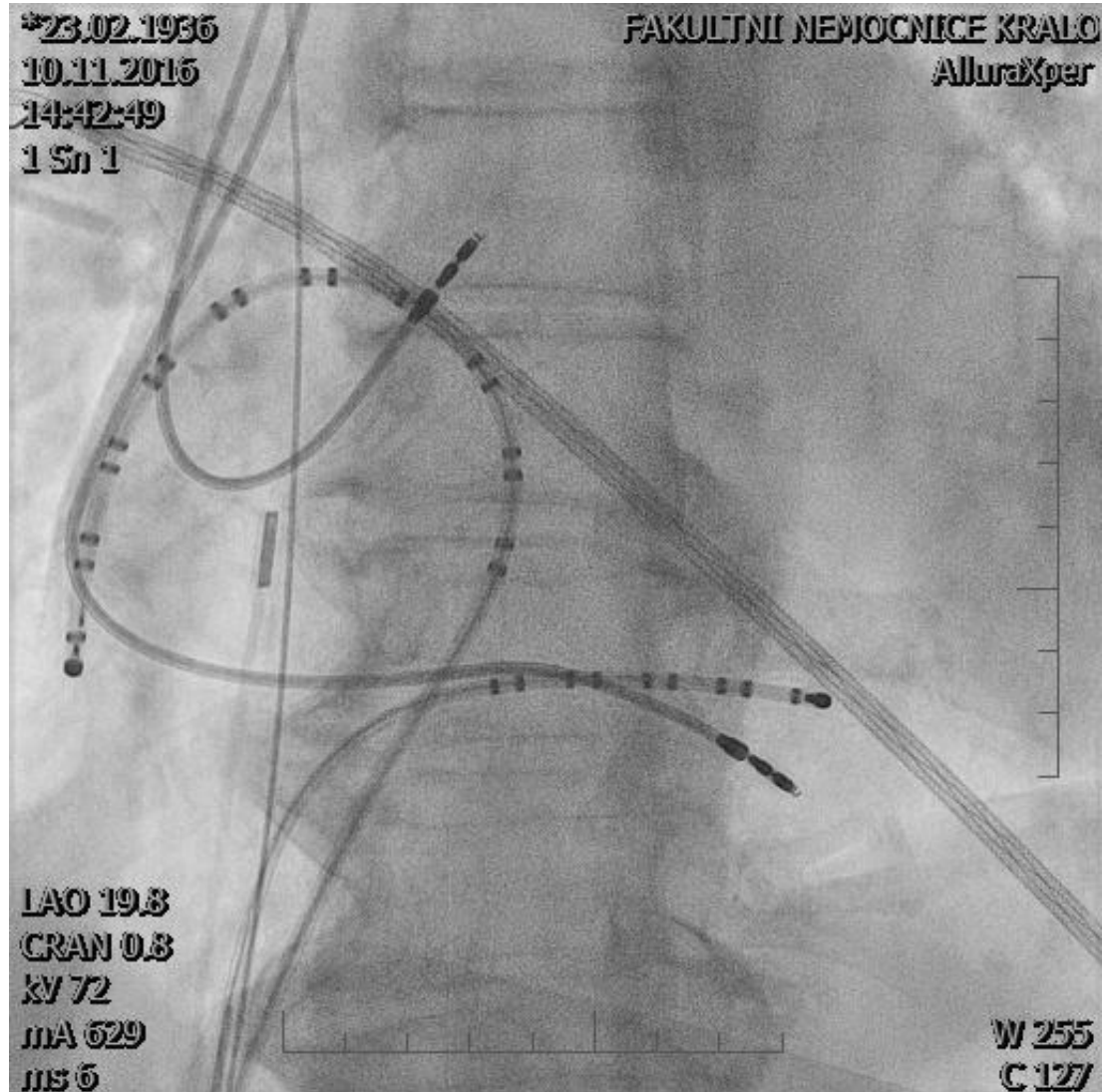
Patient:

ID:

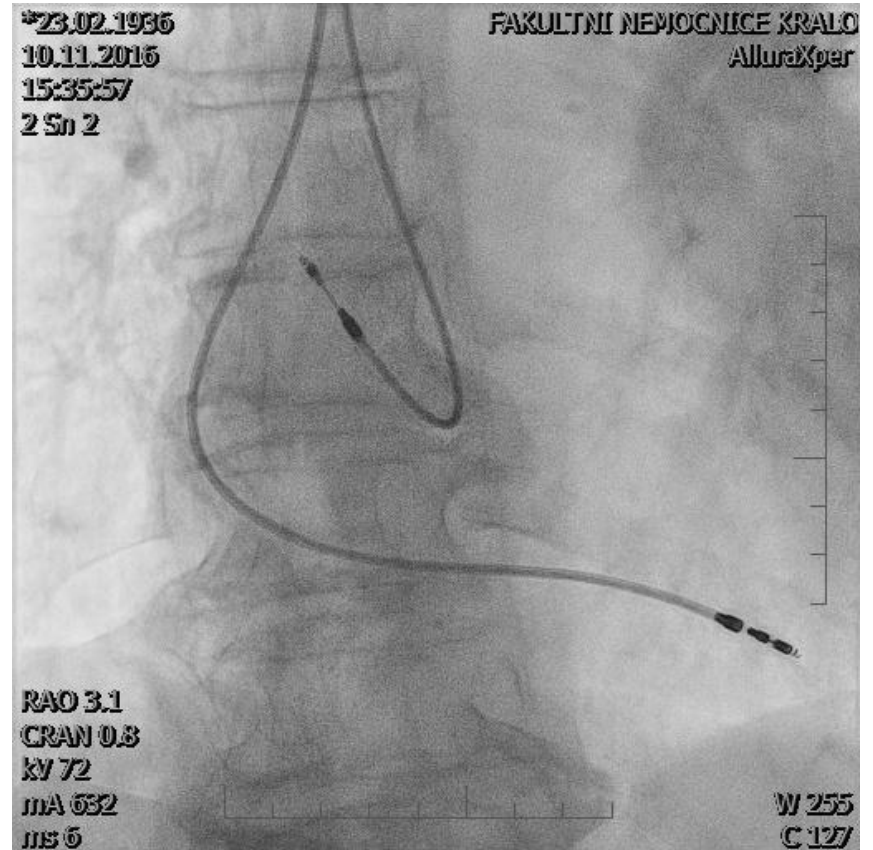
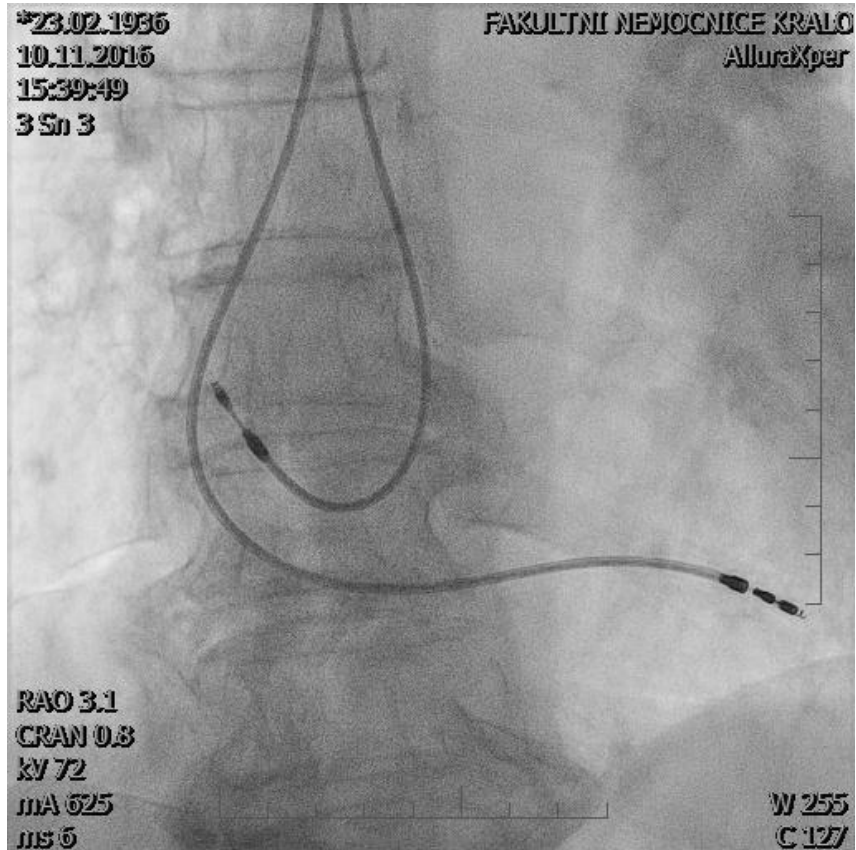
Recorded on November 10, 2016 at 14:48:53.858



RTG

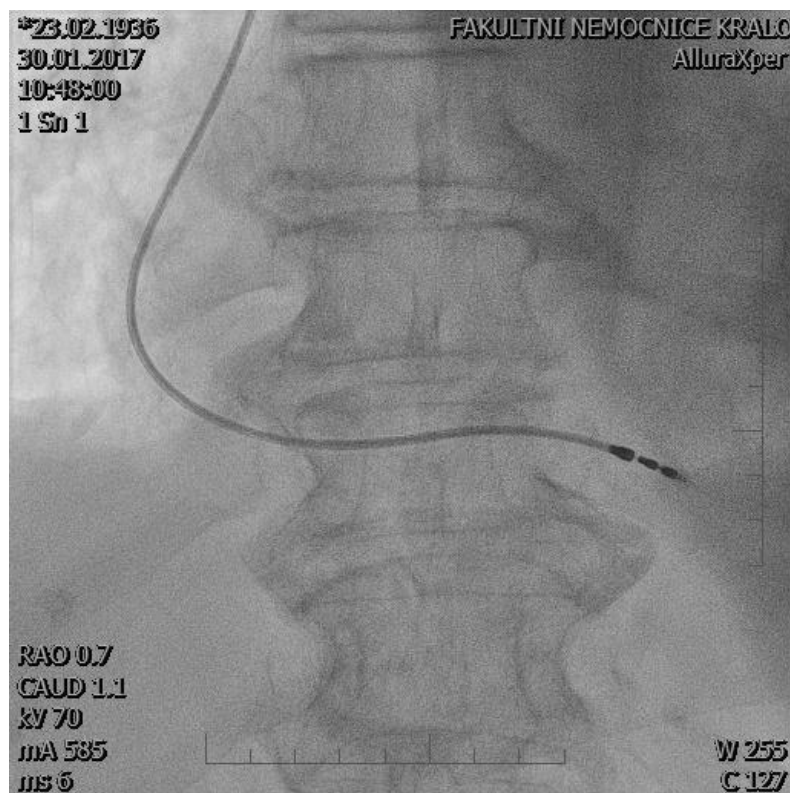


Repozice elektrody



Závěr

- Arytmie →ouško pravé síně
- Implantován 1D KS



BAROLD, S. SERGE, ANDREAS KUCHER, JOCHEN MENNE a ROLAND X. STROOBANDT. Electrical Atrial Alternans Recorded by Cardiac Rhythm Devices during Atrial Flutter. *Pacing and Clinical Electrophysiology* [online]. 2015, **38**(10), 1231-1235 [cit. 2017-05-07]. DOI: 10.1111/pace.12629. ISSN 01478389. Dostupné z: <http://doi.wiley.com/10.1111/pace.12629>

Děkuji za pozornost